

Ameloblastic fibroma to complex composite odontome – a continuum? – a review

Authors:

Sivapathasundharam B.

Professor and Head,
Department of Oral Pathology and
Microbiology,
Meenakshi Ammal Dental College,
Chennai, India

Logeswari Jayamani

Reader
Department of Oral Pathology and
Microbiology,
Meenakshi Ammal Dental College,
Chennai, India

Abstract:

Odontogenic tumours comprise of both hamartomas and true neoplasm and are of great interest to oral pathologists, oral physicians and oral surgeons. The classification of odontogenic tumours underwent many modifications from its inception. Mixed odontogenic tumours are composed of neoplastic odontogenic epithelial as well as ectomesenchymal components. The lesions under this group are ameloblastic fibroma (AF), ameloblastic fibro dentinoma (AFD), ameloblastic fibro odontoma (AFO), odontoma, odontameloblastoma, calcifying cystic odontogenic tumour (calcifying odontogenic cyst or COC) and dentinogenic ghost cell tumour.

Ameloblastic fibromas are rare tumours and occur most commonly in first and second decade of life and may be associated with an impacted tooth.

There are two school of thoughts regarding the nature of ameloblastic fibroma. According to the first view, ameloblastic fibroma is a hamartoma and matures to become complex composite odontoma and according to the latter, it is a neoplasm. In this article, these views and their place in WHO classification of odontogenic tumours, are discussed.

Keywords: Odontogenic tumours, Odontogenic apparatus, Ameloblastic fibroma, Ameloblastic fibro odontoma, Ameloblastic fibro dentinoma, Odontoma, India, WHO classification of odontogenic tumours

1. Introduction

*Odontogenic tumours are lesions arising from or associated with odontogenic apparatus, or their remnants or their derivatives.*¹ Odontogenic tumours are rare heterogeneous group of lesions, accounting for 3-9% of all head and neck biopsied specimens.¹ They range from hamartomas to neoplasms, which in turn may vary from benign to malignant.^{2,3,4} The classification of odontogenic tumours is a dynamic one, due to the change in understanding of their nature and behaviour based on newer molecular and genetic studies.^{1,4,5}

Mixed odontogenic tumours are composed of neoplastic odontogenic epithelial as well as odontogenic ectomesenchymal components, and categorized by WHO in their classification of Odontogenic tumours (2005) under “Tumours of odontogenic epithelium with odontogenic ectomesenchyme”. The lesions under this group are ameloblastic fibroma (AF), ameloblastic fibro dentinoma (AFD), ameloblastic fibro odontoma (AFO), odontoma, ontoameloblastoma, calcifying cystic odontogenic tumour (calcifying odontogenic cyst or COC) and dentinogenic ghost cell tumor.^{3,5,6}

Among these lesions, ameloblastic fibroma, ameloblastic fibro odontoma, ameloblastic fibro dentinoma and odontoma are considered to be different points in same spectrum, with ameloblastic fibroma on one end and complex composite odontoma (CCO) at the other end as per the view of the majority.^{2,7-9}

Literature reveals that these lesions are relatively rare^{3,4,7,9-12} except odontomas, but unfortunately both types of odontomas, viz compound composite and complex composite are grouped together in these studies, though they are pathogenetically different.^{3,9} In our institution (Meenakshi Ammal Dental

College, Chennai, India), out of 4300 biopsied head and neck specimen reported in the last twenty years, ameloblastic fibroma, ameloblastic fibro odontoma, ameloblastic fibro dentinoma and odontoma together formed only 0.44% (19 cases).

Out of the 19 cases, 16 were odontoma (6 complex and 10 compound) followed by AF, AFO and AFD contributing one each.

Though the occurrence of odontoma appears to be high among the mixed odontogenic tumours in many of the Asian^{12,13} and African studies^{12,13}, it is less when compared to the western literature^{9,10,12,13}. This could be due to the racial and genetic variation and/or under reporting, since most of the odontoma, particularly compound composite odontoma, do not warrant a histopathological confirmation and are diagnosed and treated based solely on their clinical and radiographic presentation.

Though the term odontoma is commonly used for the lesions composed of all the tissues of the tooth, there are differences in clinical, radiographical and histological features in their subcategories, namely compound composite and complex composite odontoma.^{10,12,14} Further, the important distinction is that both are pathogenetically different and the pathogenesis of compound odontoma is more closely related to the formation of supernumerary tooth.^{3,6,10,14}

The similar clinical, radiographic features, with few histopathological differences permit us to speculate this spectrum of lesions as continuum of maturation of the same lesion rather than distinct entities.^{3,8,10,11,15,16} *i.e* AF matures into AFD, then AFO and finally CCO.^{6,10,11} The AFs being true neoplasm with consequent non-neoplastic, hamartomatous lesions does not allow many to accept it as a continuum, as the cases of AF occurring at the higher age

than its sequential AFO and AFs recurring as AF and not as AFD or AFO.^{3,8,10} Hence the other names, namely immature dentinoma, ameloblastic fibrodentoma of AFs has been discontinued. This unresolved nature and controversy regarding their pathogenesis inquired us to analyse their inter-relationship in this article.

Ameloblastic fibroma, considered to be the first lesion in this spectrum consists of neoplastic epithelium and connective tissue which resembles ectomesenchyme without hard tissue formation, whereas other lesions are characterised by hard tissue formation, due to the interaction of odontogenic epithelium and ectomesenchyme.^{3,8,10,11,16-18} The type of hard tissue present differentiates this further into AFD, AFO and complex composite odontoma.¹⁰ When the hard tissue is limited only to dentin it is termed as AFD, when enamel and dentin is present, it is AFO.^{8,10} If all the hard tissues of a tooth are present but in an unorganized manner, without any proliferating odontogenic epithelium is called CCO¹⁰, the last or the so called matured lesion of this spectrum.

2. Clinical features

AF, AFD, AFO and CCO clinically present as a slow growing asymptomatic swelling, frequently associated with missing tooth. The size of the lesion is usually small, measuring few millimetres; exhibits equal gender predilection;^{3,4,10,11,14-20} except few case series where male predominance are reported^{4,8}. Posterior region is the commonest site irrespective of maxilla or mandible. Displacement of teeth, pain, discomfort and paraesthesia are not usually present.^{8,10,11,14-20} These lesions occur in young age, usually less than 20 years,^{7,15} with mean age of 14.8 years for AF, 13.6 years for AFD, 9 years for AFO and 19.9 years for complex odontoma.⁷

However, this group of lesions do occur in older age and larger lesions causing asymmetry are also reported.¹¹ However, the exact clinical presentation could not be predicted because of their rarity.

3. Radiographic features

AF, AFD, AFO and CCO are usually detected as an accidental finding in radiographs taken for unerupted teeth or other reasons. Smaller lesions appear as unilocular radiolucent lesions^{15,17} and larger lesions as multilocular.^{2,10}

AFD and AFO frequently appear as unilocular radiolucency with varying amount of radiopacity demonstrating the hard tissue formation.^{2,10,15-17} AF appears as radiolucent lesion with or without sclerotic margin.^{2,10} The features like resorption of bone and surrounding roots, expansion of cortical plates and perforations are not uncommon with these larger lesions.^{10,20} Most of the lesions are associated with unerupted or impacted tooth, especially it is evidenced that three quarters of AFs are associated with impacted tooth.²¹

CCO, the final lesion of the spectrum shows varying features ranging from radiolucency, mixed radiolucency to radiopacity depending on the stage of the lesion.^{2,10,11,14} Thus, it may be difficult to differentiate a developing CCO from AF or other lesions of this group. It may also be associated with unerupted tooth.

This mixed radiopacities of the lesions discussed above bring in more similar radiographic differential diagnosis including AOT, CEOT and COC.^{15,16,19,20}

4. Histopathology

Unresolved histogenesis, limited knowledge on clinical behaviour, multivocal radiographic features and its extreme rare

occurrence perplexes the pathologist to give diagnosis based only on their histological evidences. Microscopically, AF, AFD, AFO and CCO demonstrate only minor histological differences.

The AF demonstrates capsule, which may or may not present with proliferating odontogenic islands dispersed in the cell rich ectomesenchyme resembling immature pulp with limited collagen fibres. **[Figure 1]** The islands of odontogenic epithelium are dispersed sparsely in the form of buds, cords

and strands. Each island resembles cell rests consisting of 1-2 layers of cuboidal to columnar cells with or without central stellate reticulum like cells.^{3,7-11} In contrast, the AFD and AFO resemble AF but with hard tissue deposits. **[Figure 2]** The hard tissue deposits are distinguishable as components of tooth, namely enamel, dentin, and cementum. The odontogenic islands found in proximity to the enamel and dentin matrix appear columnar and assumed to be ameloblast like cells or odontoblast like cells which have secreted the matrix.^{4,10,11,17,19}

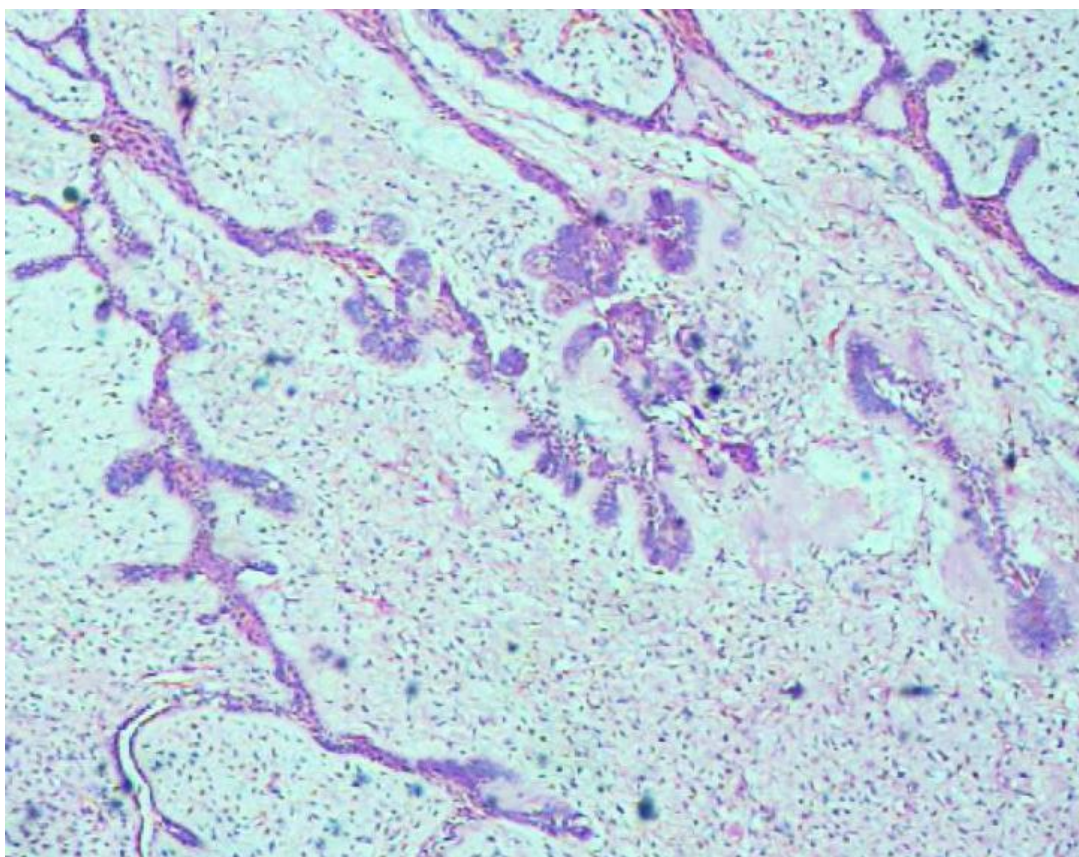


Figure 1. 20X H&E image showing Ameloblastic fibroma

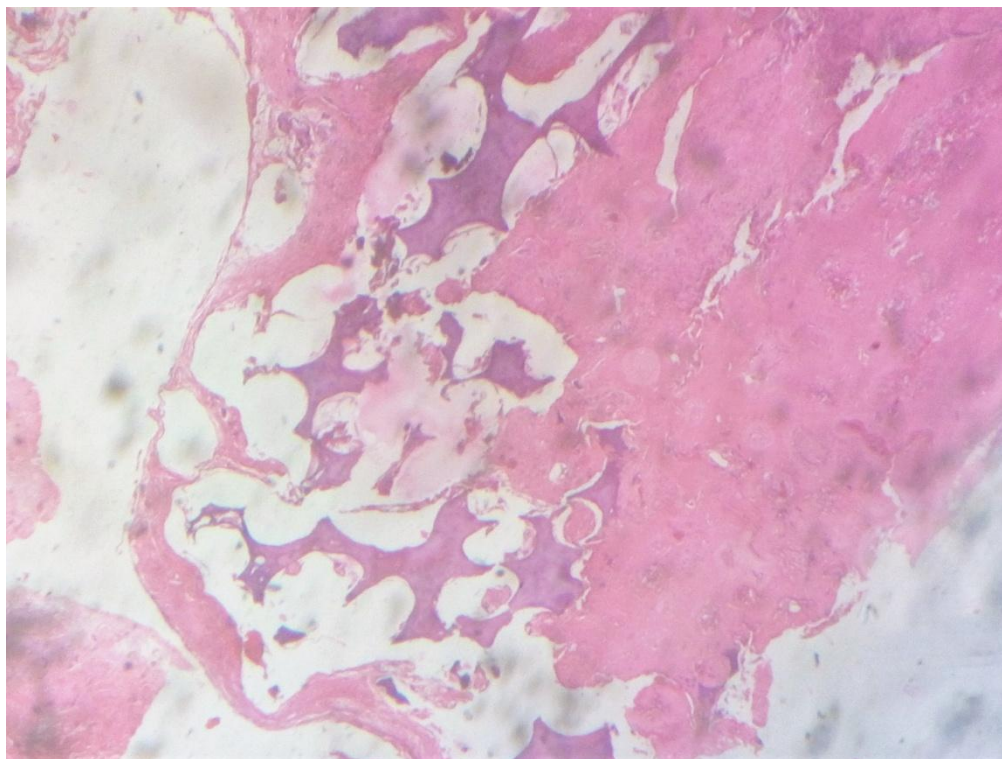


Figure 2. 20X H&E image showing Ameloblastic fibrodentinitoma

The gradual increase in hard tissue formation and decrease in ectomesenchyme in the centre of the lesion is viewed as a process of the development of CCO (continuum of the lesion). Enamel matrix, dentin matrix, cementum matrix, small areas of pulp at different degree of differentiation and nest and strands of odontogenic epithelium and ghost cells may be observed in the CCO.^{2,7,10,11,14}

5. Treatment

Irrespective of the type of these lesions, the management is almost same. Considering the benign nature and limited size, complete excision of lesion should be considered along with impacted tooth, if associated. Recurrence is seldom noticed. Malignant transformation rate is low or rarely reported.^{2,8,10,11,15-18,21} However, exact rate is not elucidated because of the paucity of data.

6. Discussion

Despite all these lesions being benign and exhibiting similar clinical, radiographic and histopathological findings and biological behaviour, the histogenesis of these lesions are still controversial. Considering AF as a true neoplasm and CCO as a hamartoma is questionable when CCO are conceived as a mature form of untreated AF with AFO and AFD being an intermediate stage.^{3,8} Various concepts were proposed and contradicted by many, in an attempt to unravel the exact origin.^{2,3,8,22}

The “continuum concept” was first postulated by Cahn and Blum, where AF matures over the period to become CCO.^{3,8} Later, this was contradicted by various authors and considered this spectrum of lesion, as a separate entity owing to occurrence of AF in older age group compared to AFO⁷ and differences in

ultrastructural and immunohistochemical features.^{3,8,21,22}

Philipsen et al, hypothesized that mixed tumours, particularly AF and AFD, exist in two lines i.e. neoplastic and hamartomatous, where the hamartomatous line continues to differentiate into other mixed odontogenic lesions of this described spectrum^{3,8} i.e. AF, AFD, AFO and CCO. Thus, it is acceptable that the proposal of AF exists in two forms, the neoplastic form, which remains AF without any further differentiation, usually occurs after 20 years of age (after the period of odontogenesis) and recur only as AF. The hamartomatous one, begins as AF (could be developing CCO) and matures to become CCO and occurs before the age of 20 years.^{3,8} However, both the categories appear histologically similar but concrete materialistic proof for the existence of these two forms is yet to be established.³ Figure 3- The schematic diagram summarizing the two lines of origin.

Since AFO and CCO have little tendency for recurrence and malignant

transformation, they better be considered as hamartomas and having no neoplastic line. However, lack of precise histological features to identify the line of origin (Hamartomatous/Neoplastic), inadequate evidences to prove the existence of the two above mentioned forms and the similar therapeutic intervention allow many to consider AF, AFO, AFD and odontoma as distinct entities. Further, WHO 2005 classification considers AF, AFO, AFD and odontoma as separate entities under “Odontogenic epithelium with odontogenic ectomesenchyme with or without hard tissue formation”.

Despite the efforts made to clarify the origin, the inadequate molecular studies and lack of association with epidemiological data leaves the interrelationship between these tumours to be inconclusive. Further, we also recommend appropriate categorisation of this mixed tumour in newer WHO classification considering its nature and behaviour.

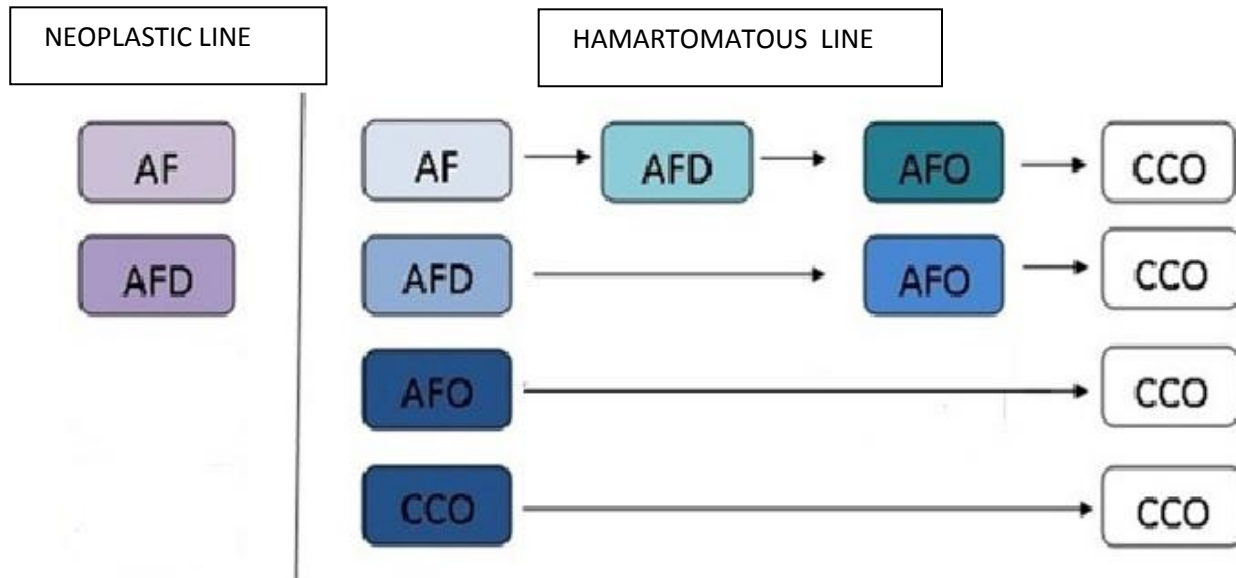


Figure 3. The schematic diagram summarizing the two lines of origin.

References

1. Sivapathasundharam B. Odontogenic tumor: Indian scenario. *J. Oral Maxillofac Pathol* 2017;21:2-3.
2. Hans Peter Philipsen, Peter A. Reichart. Classification of Odontogenic tumours. A historical review. *J Oral Pathol Med* 2006; 35:525-9.
3. Reichart PA, Philipsen HP. Odontogenic tumours and allied lesions, 2nd Ed. 2004; Quintessence publishing Co Ltd, London.
4. E. Singh¹, R. K. Pujari¹, S. Murgod¹ and H. C. Girish. Odontogenic Tumour Patterns- An Introspective Analysis; *BJMMR*:2016;11(2): 1-17.
5. Wright J, et al. Odontogenic Tumors WHO 2005: Where DO we Go from Here? *Head and Neck Pathol* 2014;8:373-382.
6. Nayak B, Patankar S, Khot K, Shobha BV, Sharma G. Ameloblastic fibro-odontoma of the maxilla: Review of literature and report of a case. *JIAOMR* 2011;23:S442-4.
7. Carlos R, Altini M, Takeda Y: In: World health organization classification of tumours Pathology and genetics of 15 head and neck tumours. Edited by Barnes L, Eveson J, Reichart P, Sidransky D. Lyon: IARC Press; 2005:294-295.
8. P.J. Slootweg. An analysis of the interrelationship of the mixed odontogenic tumors - ameloblastic fibroma, ameloblastic fibro-odontoma, and the odontomas. *Oral Surg Oral Med Oral Pathol* 1981;51:266–276.
9. Barnes L, Eveson JW, Reichart P, Sidransky D. World Health Organization classification of tumours: pathology and genetics, head and neck tumours. Lyon: IARC Press; 2005.
10. D. M. Cohen, I. Bhattacharyya. Ameloblastic fibroma, ameloblastic fibro-odontoma and odontoma. *Oral Maxillofacial Surg Clin N Am* 2004;16:375-384.
11. Peter R. Morgan. Odontogenic tumours: a review. *Periodontology* 2000 2011;57:160-176.
12. Gupta B, Ponniah I. The pattern of odontogenic tumors in a government teaching hospital in the southern Indian state of Tamil Nadu. *Oral Surg Oral Med Oral Pathol Oral Radiol Endod* 2010;110(1):e32-39.
13. Sriram G, Shetty RP. Odontogenic tumors: a study of 250 cases in an Indian teaching hospital. *Oral Surg Oral Med Oral Pathol Oral Radiol Endod* 2008;105(6):e14-21
14. Olga Hidalgo Sánchez , M^a Isabel Leco Berrocal , José M^a Martínez González. Metaanalysis of the epidemiology and clinical manifestations of odontomas. *Med Oral Patol Oral Cir Bucal*. 2008 Nov 1;13(11):E730-4.

15. Chang H, Precious DS, Shimizu MS. Ameloblastic fibro-odontoma: A case report. *J Can Dent Assoc* 2002;68:243-6.
16. G. De Riu, S. M. Meloni, M. Contini, and A. Tullio, “Ameloblastic fibro-odontoma. Case report and review of the literature,” *Journal of Cranio-Maxillofacial Surgery* 2010;38:141–144.
17. Silva GC, Jham BC, Silva EC. Ameloblastic fibro-odontoma. *Oral Oncol Extra* 2006;42:217-20.
18. Ayham Arab Oghli, Ignazio Scuto, Christoph Ziegler, Christa Flechtenmacher, Christof Hofele. A large ameloblastic fibro-odontoma of the right mandible. *Med Oral Patol Oral Cir Bucal* 2007;12:E34-7.
19. Priyanka G, Vijay W, Priya K. Ameloblastic fibro-odontome. A case report with review of literature. *Indian Journal of Basic and Applied Medical Research* 2014;3(4):109-12.
20. Brenda L. Nelson Æ Gretchen S. Folk. Ameloblastic fibroma *Head and Neck Pathol* (2009) 3:51–53
21. Pontes H.A.R, Pontes F.S.C, Lameria A.G, Salim R.A, Carvalho P.L.D, Guimares D.M, Pinto D S. Report of four cases of ameloblastic fibro-odontoma in mandible and discussion of the literature about the treatment. *Journal of Carnio-Maxillo-Facial Surgery*.2012: 40;e59-e63.
22. Chen Y, Li TJ, Gao Y, Yu SF. Ameloblastic fibroma and related lesions: a clinicopathologic study with reference to their nature and interrelationship. *J Oral Pathol Med* 2005,34:588-595.