

REVIEW ARTICLE

Serous Cystic Neoplasms of the Pancreas: Can We Distinguish the So-Called Locally-Aggressive Lesions from the Malignant Lesions? Case Series and Proposal of Unified Term “Serous Cystic Neoplasms of Low Grade Malignant Potential”

Author

Hongfa Zhu, MD, PhD¹, Sara C. Lewis, MD², Xuchen Zhang, MD, PhD³, Myron E. Schwartz, MD⁴

Affiliations

¹Departments of Pathology, ²Radiology, ⁴Surgical Oncology, of the Icahn School of Medicine at Mount Sinai, New York, NY 10029

³Department of Pathology, Yale University School of Medicine, New Haven, CT 06510

Correspondence:

Hongfa Zhu, MD, PhD

Department of Pathology

Annenberg 15-38C

The Icahn School of Medicine at Mount Sinai

1468 Madison Avenue, New York, NY 10029

Tel: 212-241-4226

Email: hongfa.zhu@mountsinai.org

Abstract:

Serous cystic neoplasms of the pancreas are uncommon lesions and are generally considered benign. Conservative management is generally advised unless the lesion is symptomatic, rapidly enlarging mass, or the diagnosis is uncertain. Malignant serous cystadenocarcinoma has been occasionally reported in the literature. However, controversy remains for the definition, diagnosis, and management of the malignant counterpart. Additional proposal for the so-called locally invasive serous cystic neoplasms could also add more confusion to the rare entity.

Key Words: Serous cystic neoplasms; serous cystadenocarcinoma; locally invasive serous cystic neoplasms

Introduction:

Due to widespread use of advanced radiographic imaging, the discovery of incidental asymptomatic pancreatic cysts has increased. The prevalence of pancreatic cysts is estimated at 2.6% and can reach 8% in the elderly [1, 2]. Serous cystic neoplasms (SCNs) of the pancreas are relatively uncommon tumors that comprise approximately 1% of all pancreatic neoplasms and 10-15% of all pancreatic cystic neoplasms [3]. Unlike intraductal papillary mucinous neoplasms (IPMNs) and mucinous cystic neoplasms (MCNs), which are premalignant lesions, SCNs are generally regarded as almost always benign and can be managed conservatively. Surgery is usually reserved for patients with symptoms, an uncertain diagnosis, or a rapid enlarging tumor [4-6]. In addition, unlike IPMNs, surgery is considered curable for most SCNs and post-operational surveillance is not warranted [7].

George et al [8] first reported a case of serous cystadenocarcinoma (SCAC) manifested by invasion into the adjacent organs and synchronous liver metastases. Since then, approximately several dozen cases of the so-called “malignant” or “invasive” SCNs have reported in the literatures [9]. The prevalence of SCACs is estimated to be less than 1% to 3% and SCACs are characterized by female predominance with a mean age of 66 years, larger tumor size, and are almost always symptomatic [7, 10, 11]. Both SCACs and SCAs are lined by glycogen-rich cuboidal cells without cytological atypia that are histologically indistinguishable from each other.

However, controversy and uncertainty regarding the natural history, definition, and diagnosis of SCACs persist; partially fueled by the rarity of the lesion, indolent tumor behavior even in the presence of metastasis, the short-term

postsurgical follow-up, and the possibility of concomitant multi-organ benign cystic diseases [5, 9, 12]. The 2010 WHO [13] requires the presence of distant organ metastasis for the diagnosis of SCACs. In the meantime, other investigators [10] have proposed the concept of “locally-aggressive SCNs” (LaSCNs) as a separate subgroup of tumors described as invading surrounding structures and/or vessels, or directly extending into peripancreatic lymph nodes. LaSCNs are usually large (mean diameter 10.5 cm) and have the potential to recur as metachronous metastatic lesions, therefore additional postsurgical surveillance is warranted [10, 14].

We reported here two of three cases of serous cystic tumors of the pancreas with local invasion, one of which developed local tumor recurrence with metachronous liver metastases over a 17-year postoperational surveillance. The patient is still alive; however, she has been severely debilitated by the tumor burden and is no longer a candidate for either surgery or chemotherapy. Therefore, it is important to understand that both LaSCNs and SCACs require long-term postsurgical follow-up and that LaSCNs may develop metachronous distant metastases if given sufficient postsurgical follow-up. Arbitrary separation of LaSCNs from SCACs will cause potential confusion in the diagnosis and patient care and we therefore propose the unified term of “serous cystic neoplasms of low grade malignant potential” (SCNsLMP) that includes both LaSCNs and SCACs.

Case reports:

Case #1:

A 69-year-old woman presented with abdominal pain, nausea, and obstructive jaundice. Ultrasound exam showed a cystic lesion in the head of pancreas. The patient had worsening symptoms and a stent was placed in the common bile duct (CBD) in Ecuador. The discomfort never resolved, and

two years later, the patient was brought to the Mount Sinai Hospital. Computed tomography (CT) radiography showed a 5.5 cm complex cystic mass in the head of pancreas, which was found to compress the distal bile duct and portomesenteric junction. No other lesion was found in the liver or other organs. The resected Whipple specimen showed an ill-defined multilocular cystic lesion that grossly invaded the CBD and superior mesenteric vein (SMV) (Fig

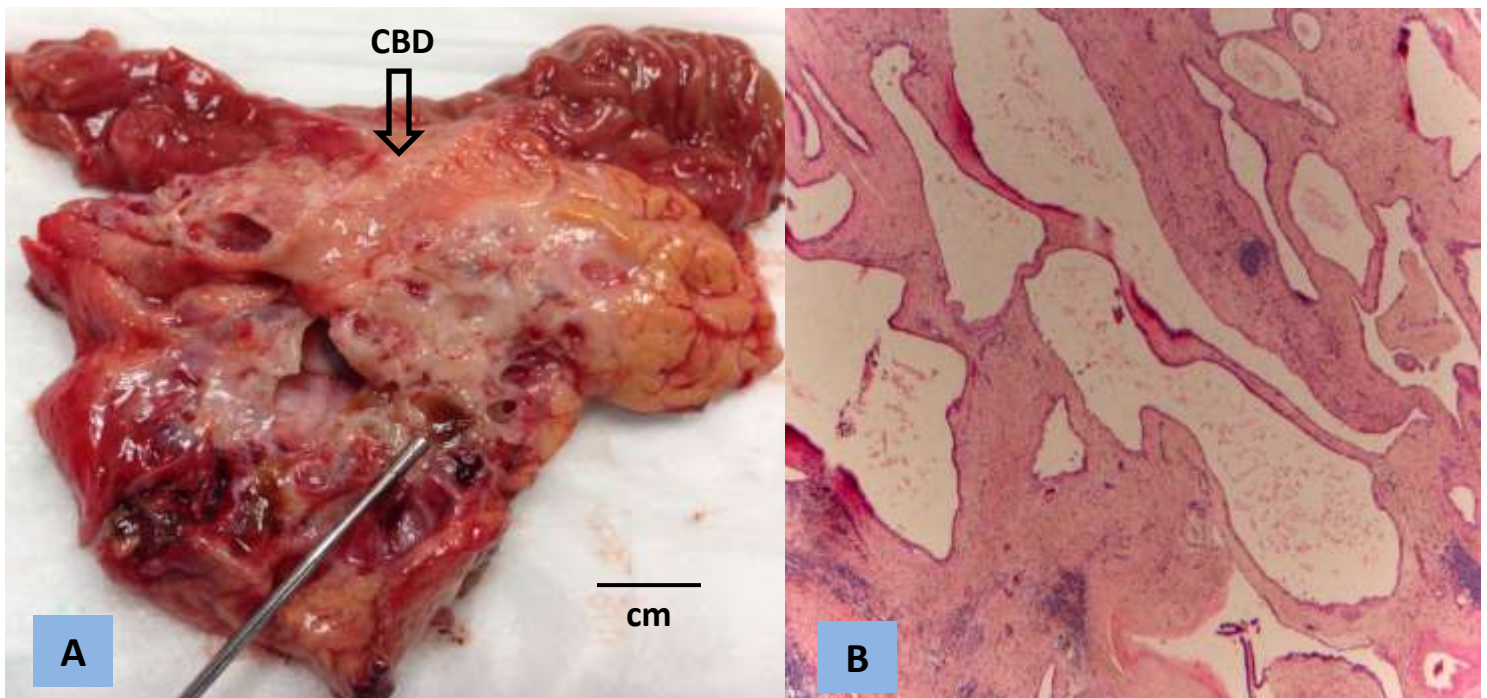
1A). Microscopically, the cystic lesion was lined by glycogen-rich cuboidal epithelium without cytologic atypia, compatible with serous cystic neoplasm (Fig 1B). Intra-neural invasion was identified and three of seventeen (3/17) lymph nodes were involved by the tumor (Fig 1C, D). The patient did not receive adjuvant therapy and a repeated CT scan a year later did not reveal any tumor recurrence. The patient is currently asymptomatic three years after surgery.

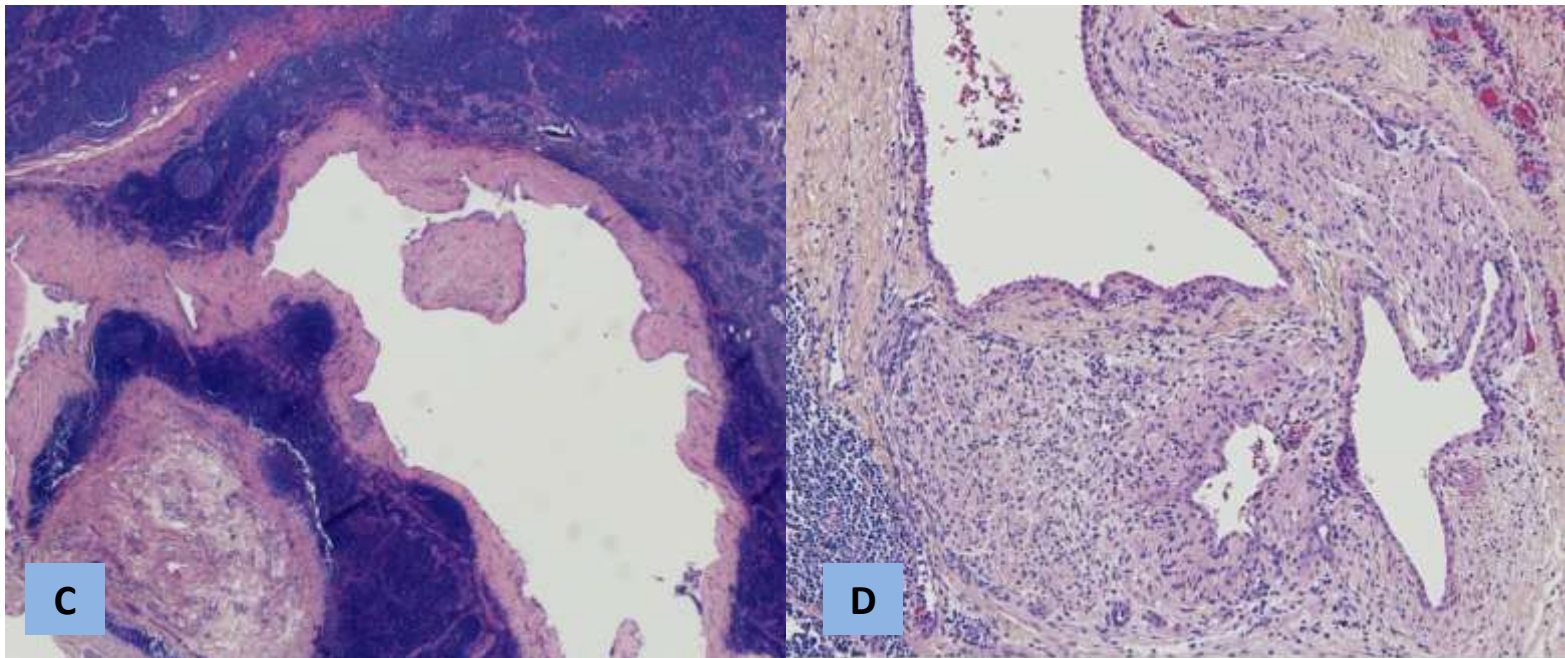
Fig1: Whipple resection of pancreatic serous cystic neoplasm

A. The resected specimen showed an ill-defined multilocular cystic lesion with invasion of the common bile duct (arrow).

B. Microscopically, the cystic lesion had abundant intervening stroma and lined by bland cuboidal epithelium. C. Lymph node invasion.

D. Intra-neural invasion.





Case #2:

A 63-year-old woman presented with abdominal pain, ascites, ovarian mass, and a cystic lesion in the head of pancreas in 2000 and underwent Whipple resection, hysterectomy, and bilateral salpingo-oophorectomy at the Mount Sinai Hospital. The resected pancreatic tumor was a 4 cm well-circumscribed, rubbery, homogenous cystic mass. The mass did not appear to be invading the peripancreatic fat or adjacent organs other than SMV involvement. No distant metastasis was found at that time. Microscopically, the tumor consisted of multilocular microcysts lined by glycogen-rich cuboidal epithelium with minimal cytologic atypia. No lymphovascular or perineural invasion was reported. The ovaries showed extensive hemorrhage and infarction consistent with adnexal torsion. The patient was put under surveillance every six months post surgically and was doing well until five years after initial surgery, when the patient developed recurrent tumor

at the mesentery near the segment of small bowel that was resected. The recurrent tumor showed identical histology to the prior pancreatic tumor. The patient remained asymptomatic and CT surveillance showed stable disease in the first few years after the second surgery. However, subsequent surveillance CT scans showed slowly progressive recurrent tumor in the pancreatic bed that encased superior mesenteric artery (SMA) with enlarged lymph nodes (Fig 2A, B). Nine years after initial Whipple surgery, CT also showed a number of small hypodense lesions in the liver that progressed over time (Fig 2B, C, D). Biopsy of the liver tumor showed identical histology to that of primary pancreatic tumor (Fig 3A, B). Over the past two years, the patient has developed progressive weakness, shortness of breath, diarrhea, and wasting. Currently, 17 years after the initial Whipple procedure, the patient is still alive, but is unable to tolerate chemotherapy or surgery.

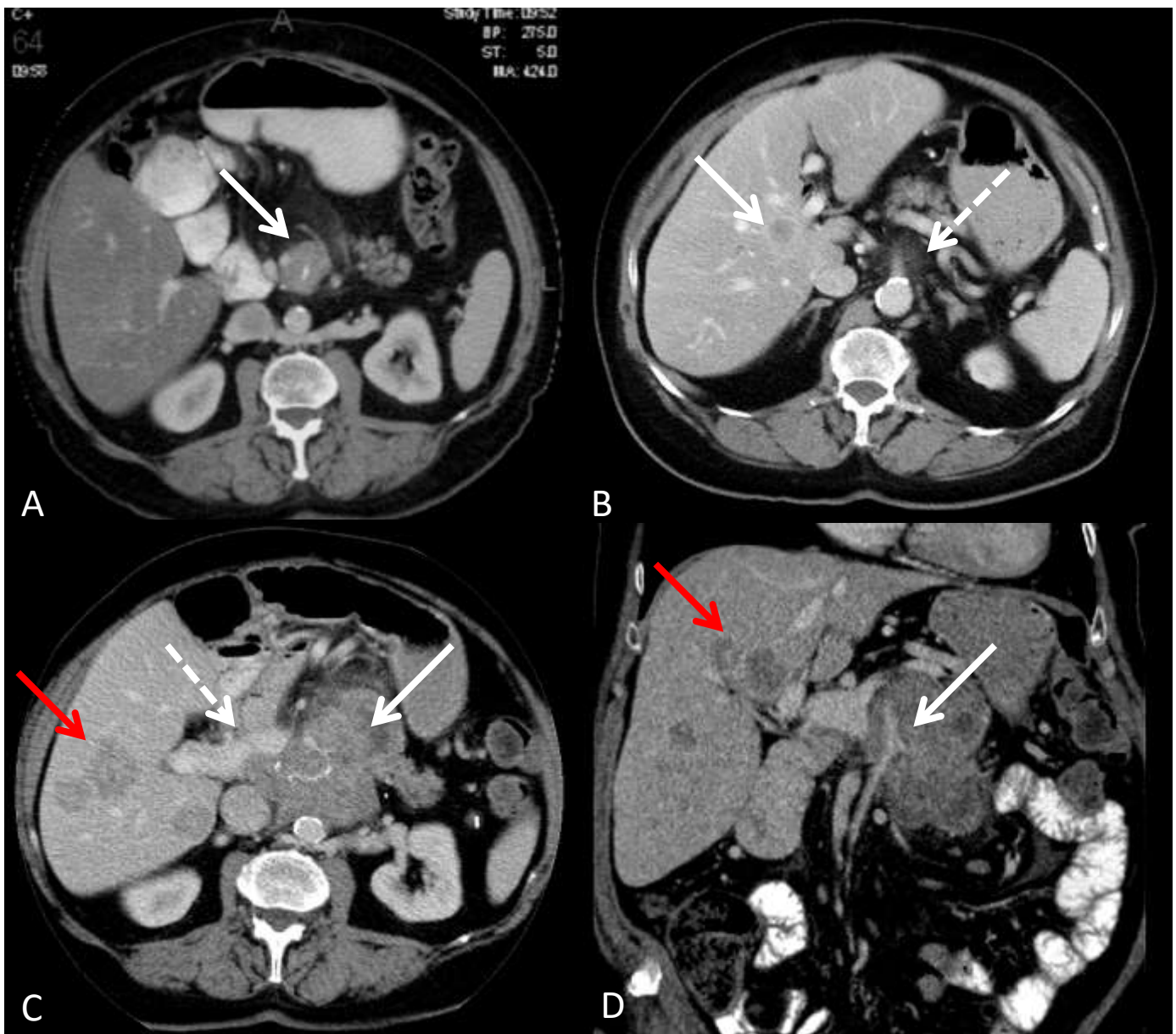
Fig 2. Radiographic progression of serous cystic tumor over 17-year surveillance.

A. Contrast enhanced CT performed in 2005 demonstrated a well circumscribed soft tissue mass in the surgical bed encasing the suture material, consistent with recurrent tumor (arrow).

B. CT exam performed in 2011 revealed new hypoenhancing lesion in the right lobe of the liver, consistent with metastasis (arrow). Minimal infiltration of the fat surrounding the SMA was noted at this time (dashed arrow).

C. CT scan performed in 2013 demonstrated enlargement of the soft tissue mass in the prior surgical bed, which now involves the remaining pancreas (arrow). Tumor was inseparable from the main PV (dashed arrow). Three hypoenhancing liver metastases were present in the right lobe, also consistent with progression of metastatic disease (red arrow).

D. Coronal image demonstrated encasement of the SMA by the recurrent tumor in the surgical bed (arrow). Metastatic liver lesions were also noted (red arrow).



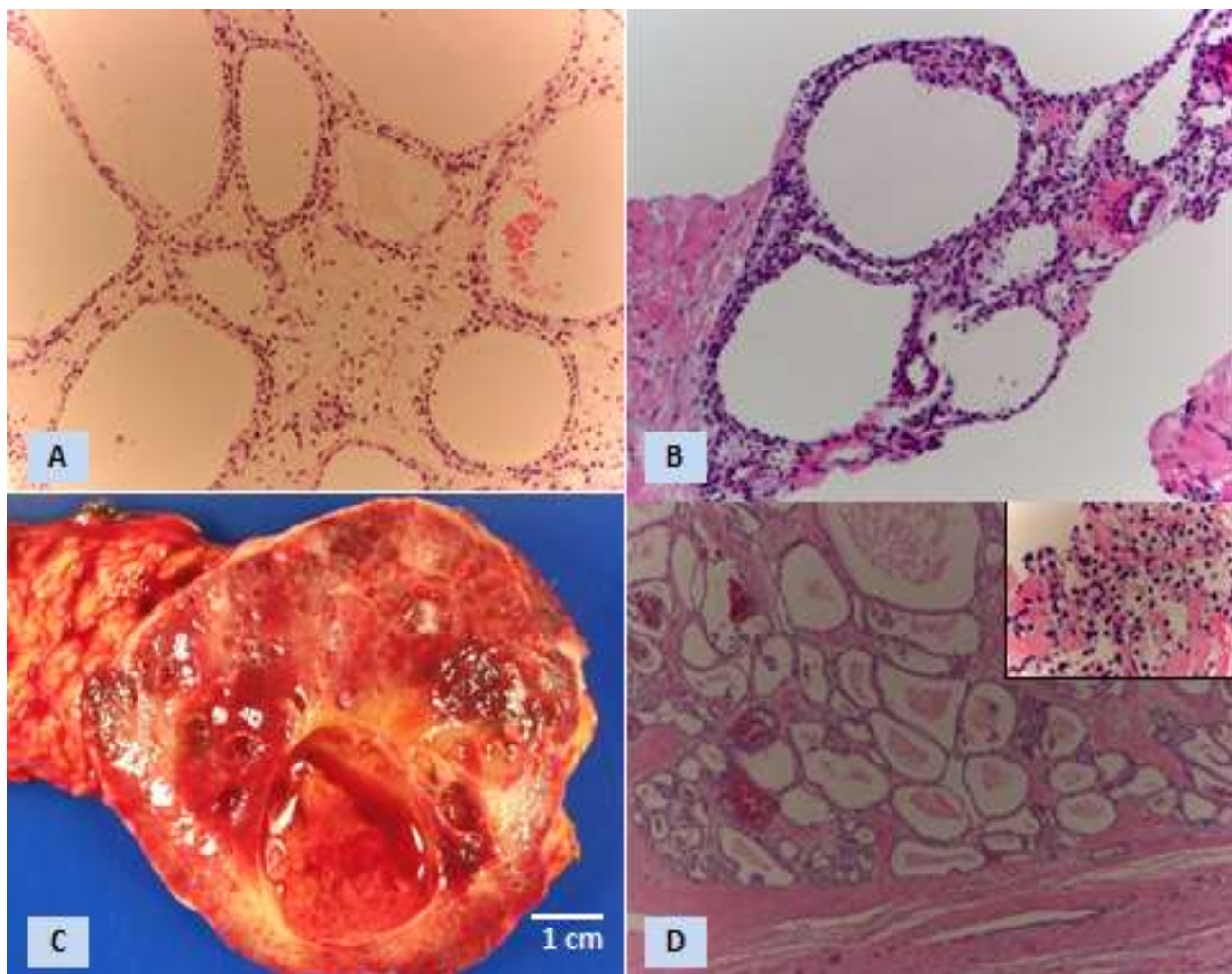
Case #3:

A 38-year woman presented with dyspepsia, vomiting, palpation of mass, and abdominal pain in 2006. CT showed a very large vascular mass in the body of pancreas that was suspicious for neuroendocrine tumor. The resected distal pancreas specimen showed a 7.2 x 7 x 7 cm well-circumscribed mass with solid to cystic appearances (Fig 3C). Microscopically, the tumor consisted of multilocular cysts lined by glycogen-rich cuboidal cells consistent with serous cystic neoplasm (Fig 3D). No

definite adjacent organ invasion. Lymph nodes were free of tumor. The patient's postoperational recovery was uneventful.

In May 2017, the patient was admitted to the Yale New Haven Hospital for increased liver function test and MRI showed a 2.8 cm mass in the right lobe that was hypointense on T1 and hyperintense on T2 with ring enhancement. The mass was not seen on abdominal CT in 2006. Liver biopsy of the mass showed a serous cystic tumor that was similar to the prior pancreatic tumor (Fig 3D, insert).

Fig 3. Gross and microscopic images of the serous cystic neoplasms of the pancreas and liver metastases
A. Microscopic image of primary pancreatic serous cystic tumor in case #2 (original magnification x 200).
B. Biopsy of the metastatic tumor from the liver in case #2 (original magnification x200). C. Resected distal pancreatic multilocular cystic tumor case #3. D. Microscopic images of pancreatic and liver metastasis (insert) in case #3.



Discussion:

Unlike mucinous cystic counterparts, serous cystic neoplasms are considered almost always benign and can be managed conservatively. Surgery is only considered in the case of uncertain diagnoses, symptoms, an increase in size of the tumor, or for large tumors [4, 6, 11]. Since George et al [8] first described a case of biopsy-proven, malignant serous cystic tumor that invaded into the adjacent organs with liver metastasis, approximately 42 cases of the so-called “malignant” or “invasive” serous cystic tumors of the pancreas have been reported [9]. The reported malignant or invasive serous cystic tumors were manifested by either local invasion into adjacent organs such as vessels, spleen, peripancreatic fat, stomach, duodenum, colon, retroperineum, adrenal gland, and nerves [10, 12, 15-23], or distant organ metastasis that usually involved the liver [7, 8, 10, 11, 14, 24-30]. SCACs are very rare and most believe that the incidence of SCACs is less than 1% [10, 11, 14]. Both SCACs and SCAs share similar histology that is characterized by glycogen-rich cuboidal cells and are morphologically indistinguishable from each other except in rare case of histologically malignant serous cystadenocarcinoma (aka carcinoma ex microcystic adenoma) [31].

The most controversial and contentious issue regarding serous cystic neoplasms is whether the malignant serous cystic tumor entity ever exists, and if so, what the diagnostic criteria are for diagnosis, and whether these lesions can be diagnosed pre-operatively [7, 9, 12]. Much of the debate stems from the extremely indolent behavior of these tumors, absence of histologic atypia, paucity of cases, and limited postoperational follow-up. In one quarter cases, SCNs were initially considered benign at the time of operation,

and malignancy was only made on the occurrence of metachronous metastasis [7]. Other challenges in the histopathologic assessment include distinction of true invasion by malignant tumors from compression or adhesion into adjacent organs by large benign tumors as well as the possibility of multiorgan benign cystic lesions [9, 12].

Despite the controversy, there are a good number of reports to suggest that a small percentage of SCNs do have definite malignant clinical behavior [8, 14, 26, 29, 32]. Wu et al [33] reported a 57-year-old woman with metastatic serous cystic tumor diffusely infiltrating the liver, pancreatic bed, and encasing the celiac axis 10 years following prior tumor resection. Franko et al [29] also reported that a 68-year-old woman had a 5 cm locally-aggressive serous cystic tumor that subsequently developed metachronous liver metastasis. The patient developed anemia, weight loss, abdominal pain and died of local tumor progression and the metastatic disease. In the second case presented here, the patient was initially diagnosed with a 4 cm well-circumscribed serous cystic tumor in the head of pancreas with only SMV involvement. However, during 17-year postoperational surveillance, the patient developed local tumor recurrence that further progressed to tumor encasement of the SMA with lymphadenopathy and multiple liver metastases. The tumor clearly demonstrated a slow, but progressive behavior that was characteristic of low grade malignant tumor. Although some of the reported cases were hampered by short-term postoperational follow-up or lack of histological confirmation, the finding from other well-documented cases undoubtedly confirms the existence of malignant serous cystic neoplasms. The hypothesis of

multiorgan benign cystic disease is not well supported [9].

Large series studies of SCNs of pancreas have led some to propose the term “locally aggressive SCNs” (LaSCNs), defined by invasion into the surrounding structures and/or vessels or extension into peripancreatic lymph nodes [10]. LaSCNs account for about 2-5% of SCNs [9-11, 14].

In comparison to SCACs with metastatic disease, LaSCNs shared similar patients’ age (68 vs 66 years) and tumor size (9.6 vs 9.8 cm) (Table 1). The main difference was that tumors with metachronous distant organ metastasis occurred at an average of 5.8 years postoperation while LaSCNs had much shorter postoperational follow-up at an average of 2.7 years (Table 1).

Table 1 Comparison of Locally-Invasive to Metastatic Serous Cystic Neoplasms

	No. Cases	Mean Age (Range) Mets (years)	F/M	Size (cm)	Follow-up or Time to
LaSCNs without mets *	32	68 (28-87)	21/11	9.6	2.7 (0.5-10)
LaSCNs with metachronous mets **	8	66 (57-86)	5/2	9.8	5.8 (0.3-13)
SCNs with synchronous mets ***	10	65 (56-78)	5/4	11.6	n/a
SCNs with metachronous mets **** without invasion	8	61 (52-63)	7/0	11.3	4.3 (2-9)

References:

*[3, 9, 10, 12, 16-23, 42-44], Zhu case#1

**[10, 14, 28-30, 32, 33], Zhu case#2

***[8, 10, 14, 24-26, 28, 45]

**** [7, 25, 34, 46-49]

Galanis et al [14] reported a case that initially presented as a locally-aggressive tumor, but recurred 13 years after primary surgery with disease in the liver and retroperitoneal tissue. In the reported 14 cases of SCACs with either synchronous or metastatic disease, 6 of them (43%) were preceded by local tumor invasion [34]. It is generally agreed that LaSCNs do harbor significant risk of future metachronous metastasis and additional postoperational follow-up surveillance is warranted [10, 14]. In a series of 243 SCNs, none of those patients without locally aggressive features developed liver metastasis [10]. Thus, LaSCNs and SCACs share many common features and may have similar clinical course if giving sufficient postoperational follow-up. In the absence of a complete understanding of the natural history and

molecular mechanism of malignant SCNs, arbitrary separation of LaSCNs from SCACs will only add more confusion to the diagnosis, classification, and management of patients with malignant or invasive SCNs.

The 2010 WHO requires the presence of distant organ metastasis for the diagnosis of SCACs. However, this definition has very limited supporting evidence. As noted previously, many SCACs were preceded by primary serous cystic tumor with local invasion [7, 10, 11, 14, 28-30, 33]. Although we cannot distinguish the SCACs from the LaSCNs or large SCNs morphologically, it is undeniable that LaSCNs do have increased risk for future metachronous metastasis [10, 14]. Defining the malignancy based on metastasis will cause confusion and

mismanagement in many cases and will repeat similar mistakes as the 2004 WHO on pancreatic neuroendocrine tumor which has been criticized and subsequently corrected [35].

Following the tumor growth rate of the SCN can also help to guide clinical management. With serial radiographic imaging, it was found that smaller tumors (< 4 cm) grew at slower rate at 0.12 cm/year and were less likely to be symptomatic; while larger tumors (> 4 cm) grew at much fast rate at 2 cm/year and were more likely to be symptomatic (22% vs 72%, $p < 0.001$) [36]. In study of 257 patients who underwent resection for SCNs, it was also found that larger tumor size (mean 10.5 cm) and head of pancreas location were independently associated with aggressive behavior [10]. While the debate on SCACs may continue, it has been accepted that LaSCNs do pose significant potential for future metachronous metastasis and long term postoperational follow-up is warranted [10, 14]. Practically, both SCACs and LaSCNs require complete tumor resection if possible and long-term postoperational follow-up for potential tumor recurrence or metastasis. Therefore, instead of arbitrary classifying malignant tumors based on metastasis, we propose the unified term of “serous cystic neoplasms of low grade malignant potential” (SCNsLMP) for tumors at significant risk of malignant potential, i.e. tumors with either locally aggressive features or with distant organ metastasis. This classification would reduce confusion in diagnosis and improve patient care.

Currently, it is accepted that most small, asymptomatic SCNs can be managed conservatively while surgery is reserved for patients with symptoms, large tumors, rapidly increasing size, or uncertaining diagnosis [4, 10, 11, 37]. Some centers

advocate aggressive surgery for all serous cystic tumors [3]. It should be emphasized that while SCN-related mortality in major academic centers is almost nil (0.1%), the overall morbidity is still significant at 15-30% [11].

The molecular makeup of pancreatic cystic neoplasms has been increasingly recognized [27, 38, 39]. It has been known that mutations in KRAS, GNAS, and/or RNF43 are highly specific for IPMNs and MCNs [27, 38, 40]. Moreover, pancreatic ductal carcinoma and carcinoma arising from IPMNs or MCNs often harbor alterations in p53, PIK3CA, and/or PTEN [41]. In contrast, VHL mutations and/or deletions are present in SCAs [27, 41]. Using whole-exome sequencing, it was found that SCAs harbor an average of 10 somatic mutations, compared to 27 mutations in IPMNs and 16 mutations in MCNs [27]. Additional molecular studies may shed some light in our understanding of the natural history of SCNs and identify molecular biomarkers in predicting SCNs at risk of malignancy.

Conclusion

It has been well-recognized that small percentage of SCNs may have the potential of low grade malignant behavior. Locally aggressive SCNs and metastatic serous cystic tumors share common histological features and a risk of future tumor recurrence; therefore they should be categorized together and managed similarly. While our understanding of the natural history of SCNs is very limited, future clinical, radiological, histopathologic and molecular studies are warranted to identify distinguishing features for the diagnosis of benign SCNs from SCNs at risk of malignant behavior.

REFERENCE LIST

1. Laffan, T.A., et al., *Prevalence of unsuspected pancreatic cysts on MDCT*. *AJR Am J Roentgenol*, 2008. **191**(3): p. 802-7.
2. de Jong, K., et al., *Disappointing interobserver agreement among radiologists for a classifying diagnosis of pancreatic cysts using magnetic resonance imaging*. *Pancreas*, 2012. **41**(2): p. 278-82.
3. Horvath, K.D. and J.A. Chabot, *An aggressive resectional approach to cystic neoplasms of the pancreas*. *Am J Surg*, 1999. **178**(4): p. 269-74.
4. Vege, S.S., et al., *American gastroenterological association institute guideline on the diagnosis and management of asymptomatic neoplastic pancreatic cysts*. *Gastroenterology*, 2015. **148**(4): p. 819-22; quiz12-3.
5. Antonini, F., et al., *Management of serous cystic neoplasms of the pancreas*. *Expert Rev Gastroenterol Hepatol*, 2015. **9**(1): p. 115-25.
6. Wargo, J.A., C. Fernandez-del-Castillo, and A.L. Warshaw, *Management of pancreatic serous cystadenomas*. *Adv Surg*, 2009. **43**: p. 23-34.
7. Strobel, O., et al., *Risk of malignancy in serous cystic neoplasms of the pancreas*. *Digestion*, 2003. **68**(1): p. 24-33.
8. George, D.H., et al., *Serous cystadenocarcinoma of the pancreas: a new entity?* *Am J Surg Pathol*, 1989. **13**(1): p. 61-6.
9. Reid, M.D., et al., *Serous Neoplasms of the Pancreas: A Clinicopathologic Analysis of 193 Cases and Literature Review With New Insights on Macrocystic and Solid Variants and Critical Reappraisal of So-called "Serous Cystadenocarcinoma"*. *Am J Surg Pathol*, 2015. **39**(12): p. 1597-610.
10. Khashab, M.A., et al., *Tumor size and location correlate with behavior of pancreatic serous cystic neoplasms*. *Am J Gastroenterol*, 2011. **106**(8): p. 1521-6.
11. Jais, B., et al., *Serous cystic neoplasm of the pancreas: a multinational study of 2622 patients under the auspices of the International Association of Pancreatology and European Pancreatic Club (European Study Group on Cystic Tumors of the Pancreas)*. *Gut*, 2016. **65**(2): p. 305-12.
12. Abe, H., et al., *Serous cystadenoma of the pancreas with invasive growth: benign or malignant?* *Am J Gastroenterol*, 1998. **93**(10): p. 1963-6.
13. Bosman, F.T., World Health Organization., and International Agency for Research on Cancer., *WHO classification of tumours of the digestive system*. 4th ed. World Health Organization classification of tumours. 2010, Lyon: International Agency for Research on Cancer. 417 p.
14. Galanis, C., et al., *Resected serous cystic neoplasms of the pancreas: a review of 158 patients with*

- recommendations for treatment. J Gastrointest Surg, 2007. 11(7): p. 820-6.*
15. Kosmahl, M., et al., *Cystic neoplasms of the pancreas and tumor-like lesions with cystic features: a review of 418 cases and a classification proposal. Virchows Arch, 2004. 445(2): p. 168-78.*
 16. Ohta, T., et al., *A case of serous cystadenoma of the pancreas with focal malignant changes. Int J Pancreatol, 1993. 14(3): p. 283-9.*
 17. Widmaier, U., et al., *Serous cystadenocarcinoma of the pancreas. Int J Pancreatol, 1996. 20(2): p. 135-9.*
 18. Vadala, S., et al., *Serous cystadenocarcinoma of the pancreas with portal thrombosis. Clin Ter, 2010. 161(2): p. 149-52.*
 19. Shintaku, M., A. Arimoto, and N. Sakita, *Serous cystadenocarcinoma of the pancreas. Pathol Int, 2005. 55(7): p. 436-9.*
 20. Matsumoto, T., et al., *Malignant serous cystic neoplasm of the pancreas: report of a case and review of the literature. J Clin Gastroenterol, 2005. 39(3): p. 253-6.*
 21. King, J.C., et al., *Pancreatic serous cystadenocarcinoma: a case report and review of the literature. J Gastrointest Surg, 2009. 13(10): p. 1864-8.*
 22. Friebe, V., et al., *Serous cystadenocarcinoma of the pancreas: management of a rare entity. Pancreas, 2005. 31(2): p. 182-7.*
 23. Cho, W., et al., *Pancreatic serous cystadenocarcinoma with invasive growth into the colon and spleen. J Korean Surg Soc, 2011. 81(3): p. 221-4.*
 24. Kimura, W. and M. Makuuchi, *Operative indications for cystic lesions of the pancreas with malignant potential--our experience. Hepatogastroenterology, 1999. 46(25): p. 483-91.*
 25. Eriguchi, N., et al., *Serous cystadenocarcinoma of the pancreas with liver metastases. J Hepatobiliary Pancreat Surg, 1998. 5(4): p. 467-70.*
 26. Wasel, B.A., et al., *Histological percutaneous diagnosis of stage IV microcystic serous cystadenocarcinoma of the pancreas. BMJ Case Rep, 2013. 2013.*
 27. Wu, J., et al., *Whole-exome sequencing of neoplastic cysts of the pancreas reveals recurrent mutations in components of ubiquitin-dependent pathways. Proc Natl Acad Sci U S A, 2011. 108(52): p. 21188-93.*
 28. Van Dyke, T.J., et al., *Serous Cystadenocarcinoma of the Pancreas: Clinical Features and Management of a Rare Tumor. Dig Surg, 2016. 33(3): p. 240-8.*
 29. Franko, J., et al., *Serous cystadenocarcinoma of the pancreas with metachronous*

- hepatic metastasis*. *Am J Clin Oncol*, 2008. **31**(6): p. 624-5.
30. Bano, S., et al., *Imaging of pancreatic serous cystadenocarcinoma*. *Jpn J Radiol*, 2011. **29**(10): p. 730-4.
31. Zhu, H., et al., *Carcinoma ex microcystic adenoma of the pancreas: a report of a novel form of malignancy in serous neoplasms*. *Am J Surg Pathol*, 2012. **36**(2): p. 305-10.
32. Bramis, K., et al., *Serous cystadenocarcinoma of the pancreas: report of a case and management reflections*. *World J Surg Oncol*, 2012. **10**: p. 51.
33. Wu, C.M., et al., *Serous cystic neoplasm involving the pancreas and liver: an unusual clinical entity*. *Abdom Imaging*, 1999. **24**(1): p. 75-7.
34. Huh, J., et al., *Malignant pancreatic serous cystic neoplasms: systematic review with a new case*. *BMC Gastroenterol*, 2016. **16**(1): p. 97.
35. Klimstra, D.S., et al., *The pathologic classification of neuroendocrine tumors: a review of nomenclature, grading, and staging systems*. *Pancreas*, 2010. **39**(6): p. 707-12.
36. Tseng, J.F., et al., *Serous cystadenoma of the pancreas: tumor growth rates and recommendations for treatment*. *Ann Surg*, 2005. **242**(3): p. 413-9; discussion 419-21.
37. Tseng, J.F., *Management of serous cystadenoma of the pancreas*. *J Gastrointest Surg*, 2008. **12**(3): p. 408-10.
38. Springer, S., et al., *A combination of molecular markers and clinical features improve the classification of pancreatic cysts*. *Gastroenterology*, 2015. **149**(6): p. 1501-10.
39. Reid, M.D., et al., *Serous cystic neoplasms of the pancreas: clinicopathologic and molecular characteristics*. *Semin Diagn Pathol*, 2014. **31**(6): p. 475-83.
40. Wood, L.D. and R.H. Hruban, *Pathology and molecular genetics of pancreatic neoplasms*. *Cancer J*, 2012. **18**(6): p. 492-501.
41. Theisen, B.K., A.I. Wald, and A.D. Singhi, *Molecular Diagnostics in the Evaluation of Pancreatic Cysts*. *Surg Pathol Clin*, 2016. **9**(3): p. 441-56.
42. Rathore, M.U., A. Arif, and B. Umair, *Serous cystadenocarcinoma of pancreas*. *J Coll Physicians Surg Pak*, 2013. **23**(6): p. 430-1.
43. Kosmahl, M., et al., *Serous cystic neoplasms of the pancreas: an immunohistochemical analysis revealing alpha-inhibin, neuron-specific enolase, and MUC6 as new markers*. *Am J Surg Pathol*, 2004. **28**(3): p. 339-46.
44. Kamei, K., et al., *Multifocal pancreatic serous cystadenoma with atypical cells and focal perineural invasion*. *Int J Pancreatol*, 1991. **10**(2): p. 161-72.

45. Machado, M.C., et al., *Synchronous resection of pancreatic serous cystadenocarcinoma and liver metastasis: First reported case and review of literature*. *Pancreatology*, 2015. **15**(6): p. 708-12.
46. Yoshimi, N., et al., *A rare case of serous cystadenocarcinoma of the pancreas*. *Cancer*, 1992. **69**(10): p. 2449-53.
47. Rossidis, G., et al., *Malignant transformation of a pancreatic serous cystadenoma*. *Am Surg*, 2012. **78**(2): p. 260-3.
48. Okada, T., et al., *[Hepatic metastasis of serous cystadenocarcinoma resected 4 years after operation of primary tumors--a case report]*. *Nihon Shokakibyō Gakkai Zasshi*, 1991. **88**(10): p. 2719-23.
49. Ishikawa, T., et al., *Immunohistochemical and molecular biological studies of serous cystadenoma of the pancreas*. *Pancreas*, 1998. **16**(1): p. 40-4.