

RESEARCH ARTICLE**Recurrent Laryngeal Nerve Paralysis - Update on Reinnervation and Neurostimulation**

Authors

Klinge, K.

Mueller A.H.*

Affiliation:

Dept. Otorhinolaryngology, Voice Center, SRH Wald-Klinikum Gera, Germany

Correspondence:

Mueller A.H.

Abstract

This article reviews the current status in vocal fold paralysis with a special focus on reinnervation and neurostimulation as promising treatment options. In both unilateral and bilateral paralysis the etiology and prognosis of recovery should be clarified as early as possible. The use of laryngeal electromyography in the course of paralysis is more important than is commonly assumed.

Because of the irreversible and static character of all recently used standard therapy options their application shall be limited to late interventions. In unilateral vocal fold paralysis with signs of thyroarytenoid muscle atrophy and wide glottic gap an early non-selective reinnervation with ansa cervicalis nerve transfer may reduce the need for laryngeal framework surgery afterwards.

For bilateral vocal fold paralysis therapeutic options with at least partial motion repair should be more emphasized in future. There is a recently progress in the concepts of selective reinnervation and neurostimulation/pacing. These new therapies have the potential to restore near normal respiratory function without compromising voice and swallowing and may contribute to the development of larynx transplantation surgery.

Keywords: Larynx, Unilateral Vocal Cord Paralysis, Bilateral Vocal Cord Paralysis, Nerve Transfer, Implantable, Neurostimulation, Laryngeal Pacing, Vocal Cord Paralysis/Therapy

Unilateral vocal fold paralysis

Unilateral vocal fold paralysis (UVFP) is in about 50 percent of the cases due to surgical procedures and intubations. Idiopathic paralysis is another relevant group with 18 percent and extralaryngeal malignant tumors in the neighborhood with 13 percent. Rosenthal et al found that since about 1995 the thyroid surgery has not longer been the main reason for a recurrent laryngeal nerve (RLN) paralysis.¹ Only one third of new paralysis are due to this kind of surgery today. The anterior approach to the neck in cervical spine surgery and carotid artery procedures are getting more popular to cause RLN paralysis.¹

Idiopathic paralysis recover in one third of the cases whereas the recovery rate is higher in iatrogenic paralysis.² Old theories to explain the resulting position of the vocal folds in RLN paralysis, like the Garcia concept, the Semon's law or the Wagner-Grossman hypothesis, cannot be applied any longer according to the actual neurophysiological knowledge.³ The clinical used terminology 'vocal fold paralysis' could be misdirecting. Compared to limb muscle paralysis with obviously loss of muscle bulk, the majority of vocal folds after RLN damage are not actually atrophic. Persisting vocal fold paralysis or better called vocal fold paresis should be understood as the endpoint of a pathologic reinnervation process, mainly

synkinetic reinnervation⁴, without recovery of mobility.

The majority of unilateral paralysis with minor glottic gaps can be rehabilitated by voice training. In case of persisting breathlessness and more extended glottis closure insufficiency injection laryngoplasty, thyroplasty type I and or arytenoid adduction could be necessary later on.

Bilateral vocal fold paralysis

Bilateral vocal fold paralysis (BVFP) is most commonly a result of surgical trauma to the recurrent laryngeal or vagal nerve (44%), followed by malignancies (17%), endotracheal intubation (15%), neurologic diseases (12%) and idiopathic etiologies (12%).⁵ Diseases of the cricoarytenoid joint, scarring of the posterior larynx or myogenic diseases are very rarely and cause bilateral immobility but definitively no paralysis. Five percent of the patients suffering from rheumatoid arthritis have an involvement of the cricoarytenoid joints with dyspnea⁶ during the course of the disease.

The position of the paralyzed vocal fold is responsible for the clinical symptoms. The degree of medialization of the vocal fold and the tightness of the vocal folds will correlate with the dyspnea the patient will present with.

The voice quality is normally not impaired. Dysphagia can occur at the onset of the

paralysis. Dyspnea at exercise is a typical finding because of the resulting inhibition of glottis opening. The grade of dyspnea depends on the size of the glottis gap, the length of the vocal folds, the tension of the paralyzed vocal fold and as well on the individual breathing volume of the patient. Only a few patients need to have a tracheotomy initially. The majority of the patients learn to adapt pretty well to the capacity of the individual body and the limitations in the profession, in daily life and finally in the quality of life. The breathing problems and the stridor are worse during nights. During airway infections these patients are at risk.

Concerning the natural history of the paralysis it is well known from medical experience that a recurrence of the movement of the vocal fold is possible at the earliest after 4-6 months⁷, but in some cases only after 12-18 months.⁸ All surgical irreversible interventions before the end of this neuromuscular regeneration time need to be looked at with a sense of proportion. An early electromyographically investigation can predict a bad regeneration prognosis but it is difficult to predict the actual recurrence of a vocal fold movement.⁹ As far as it is known the synkinetic type is the dominating form of pathological reinnervation in persistent iatrogenic RLN paralysis. The chances for an improvement of the breathing situation depend

on the synkinetic reinnervation course of the abductor and adductor muscles and the imbalance between their forces. The proof of a synkinetic reinnervation in a second laryngeal electromyography (LEMG) together with an interference patterns analysis increase the diagnostic power of this method. The significance of the LEMG is rated higher nowadays because the therapeutically consequences that it can alert to.¹⁰

Recent standards of therapy

The current surgical treatment of unilateral paralysis is focused on a narrowing of the glottis whereas in bilateral paralysis the enlargement of the glottic airway size is intended. This airway enlargement can be achieved either by vocal fold laterofixation¹¹, by unilateral laser cordotomy and or partial arytenoidectomy.¹² Today's standard surgical access is the endolaryngeal performance of the glottic airway size enlargement with the use of the microscope and the CO₂-LASER. A bright variety of modifications of the used techniques has been described in the literature.^{13,14} This article has got its focus on new therapeutic options like reinnervation and neurostimulation.

Deficits of the standard therapy

Every surgeon should be aware of the irreversible and symptomatic character of all

resecting surgical techniques of glottis airway size enlargement. The source of the breathing problems in BVFP is the inhibited glottis opening. All static glottic enlargement procedures do not adapt to the requirements of the laryngeal function during breathing, phonation and swallowing. This kind of surgery is still a compromise between breathing and voice quality with preservation of the swallowing. The results of glottic enlargement should be proven by comparison of pre- and postoperative lung function, voice and swallowing tests.¹² We took part in a multicenter therapy control study to laser surgical glottic enlargement in Germany and Austria.¹⁵

Dynamical approach of therapy

Only an at least partial restoration of the glottic movement can lead to a better adaption to the different requirements during breathing and phonation of the diseased larynx. The intrinsic laryngeal muscles are predominantly pathological (synkinetic) innervated in BVFP. Selective stimulation of the abductor or adductor muscles is the key for remobilization of synkinetic innervated vocal folds. This selective stimulation can be achieved with improved techniques of selective reinnervation

and prospectively as well with the functional electric neurostimulation (“pacing”).

Reinnervation techniques

All published techniques of laryngeal reinnervation can be divided into two groups, the selective and the non-selective procedures. As well as RLN trunk suture as the anastomosis of the ansa cervicalis nerve to the RLN lead to non-selective reinnervation. Non-selective reinnervation can enable vocal fold muscle volume preservation. Better vocal fold tension and volume result in significant better voice¹⁶. Because of simultaneously stimulation of ab- and adductor muscles a recurrence of the vocal fold movement cannot be expected in this method. But the long-term voice quality might be superior to laryngeal framework surgery or arytenoid adduction according.¹⁷ This question is the task of the randomized prospective VOCALIST study in the United Kingdom recently.¹⁸

A first approach to selective reinnervation of the only abductor muscle of the larynx, the posterior cricoarytenoid muscle (PCA), goes back to Tucker who put a nerve muscle transplant of the ansa cervicalis with a muscle patch of the omohyoid muscle into the PCA.¹⁹ Unfortunately, the following groups could not reproduce his excellent results. Crumley could

not reproduce in human beings his animal experiment results of selective reinnervation of the PCA with fibers of the phrenic nerve.²⁰

Marie and colleagues developed in a dog model a surgical procedure for bilateral selective motor reinnervation of the larynx. After transection of the RLN stem he connected the adductor branch of the RLN with terminal ansa cervicalis branches on both sides. The selective reinnervation of the PCA muscles was realized with a y-shaped free nerve graft connected to accessory phrenic nerve fibers (C5 root) inserted into the PCA muscle on both sides. This selective reinnervation concept showed reproducible laryngeal remobilization rates without relevant paralysis of the diaphragm. The phrenic nerve fibers show an ideal activity pattern to synchronize the abduction of the glottis with the breathing cycle.²¹ The Marie group has performed this challenging surgery in more than 40 patients including children until now. The published data demonstrated that the majority of the patients could be decannulated. In some cases, additional interventions like partial arytenoidectomy were needed. The dyspnea improved remarkably in all patients and in 3 out of 4 cases an active arytenoid abduction could be achieved.²²

Influenced by Marie's experiences Wang W., Li M. et al reduced the surgical procedure to the solely abductor branch reinnervation of both

PCA muscles using the whole left phrenic nerve in a large BVFP patient series.²³ The authors describe a decannulation rate of 87 %. Active bilateral and unilateral abduction were found in 72 % and 87 % of the patients respectively. A partial respiratory restriction due to hemiplegia of the diaphragm and antagonistic effects of uncontrolled reinnervated adductor muscles must be assumed according to this surgical concept. In comparison to a standard arytenoidectomy control group the reinnervation group showed significant better voice preservation²⁴. Laryngeal reinnervation was found to be less effective when patient age is more than 60 years.²⁵

Neurostimulation (Pacing)

The basic research in the field of functional electrostimulation (FES) as a dynamic treatment option in BVFP were done by Zeale and Dedo in the late 1970s.²⁶ Bergmann developed in the 1980s a human laryngeal pacing system which was breathing triggered with a breast strap. This early pacing system was tested in animals but never used in human application because of ethical concerns.²⁷ In the 1990s Zeale initiated a human pilot study including seven primarily tracheotomized BVFP patients in the USA and Europe. In this study a modified pain therapy implant (Itrel II,

Medtronic, USA) was used for PCA muscle stimulation.²⁸ After initially good results anode corruptions were found. One patient could be followed up over 6 years. The system did not include any synchronization with the breathing cycle. No swallowing or phonation problems occurred. The voluntary closing force of the adductor muscles was stronger than the stimulated abduction. This is an important aspect for upcoming projects. Zelear's clinical trials were unfortunately not continued. Recently this group focus on neuromodulation with the application of FES to improve voluntary function and avoid synkinesis by stimulating the PCA muscle during the period of regeneration following RLN injury.²⁹

In our paresis clinic the majority of BVFP patients have developed yet a synkinetic reinnervation status. Therefore, intact neuromuscular units between RLN fibers and PCA muscles exist, while the voluntary activation of the PCA muscle during inspiration is missing due to RLN synkinesis. A selective stimulation of PCA neuromuscular units will be the key for neurostimulation induced vocal fold abduction. This selective neurostimulation of terminal nerve fibers insight the PCA could be taken over by new generations of laryngeal pacemakers in future.³⁰ In contrast to direct muscle fiber stimulation the lower power demands of terminal nerve stimulation reduce

the risk of an electrochemical corrosion of the electrode material. Another aspect is that with selective neurostimulation an undesired stimulation of pharyngeal nociceptors and adductor fibers can be avoided.

Based on this concept, which was further developed together with the university hospitals in Innsbruck and Wuerzburg and in cooperation with the Med-El company (Innsbruck, Austria), a selective neurostimulation system involving a minimal invasive electrode implantation method was developed.³¹ In contrast to former used open surgery for electrode placement the integrity of the larynx is being preserved with this procedure. Acute and chronic implantations in pigs³² and in racehorses³³ had been proved the feasibility.

This so called LP System (MED-EL Innsbruck, Austria) was evaluated for the first time in human in a pilot study conducted between 2012 and 2014, which included the 3 centers involved in the LP system development. The study was approved by the relevant Ethics Committees and National Competent Authorities and contained 9 subjects. The LP System implantation and its therapeutic effect was very positively received by all the subjects enrolled in the study, including those with long-term BVFP of iatrogenic origin, who had refused any other surgical treatment. 7/9 subjects completed the post-implantation

follow-up of 6 months. The study primarily evaluated the safety of the LP System and patient's quality of life.³⁴ Furthermore the impact of the LP System on the respiratory function, voice quality, and capability to sustain physical activity was examined.³⁵

In future selective neurostimulation could not only be applied to treat BVFP but also in selected unilateral RLN paralysis with highly demands on the voice quality. Reinnervation in combination with neurostimulation will be essential requirements for the clinical establishment of laryngeal transplantation surgery.

Conclusions for the practice

Dynamic therapy options of BVFP with remobilization of at least one vocal fold could overcome the deficits of the static glottic enlargement surgery recently used. Selective

reinnervation and neurostimulation ('pacing') need to be contemplated as new therapeutic approaches in BVFP. The proved synkinetic reinnervation status is the most important requirement for new laryngeal pacing concepts. Because of its minimal invasive character, it will be applicable also in patients with comorbidities, elderly and subjects rejecting more invasive surgery. A successful selective reinnervation in BVFP requires an otherwise healthy patient and a lot of microsurgical experience in a specialist center.

Ongoing clinical trials will clarify, if newer approaches of non-selective reinnervation in unilateral RLN paralysis will produce better long-term voice results than standard thyroplasty. But it should be taken care of suturing the nerve or using a donor nerve in case of an accidental separation of the RLN trunk during thyroid or spine surgery.

Figures:

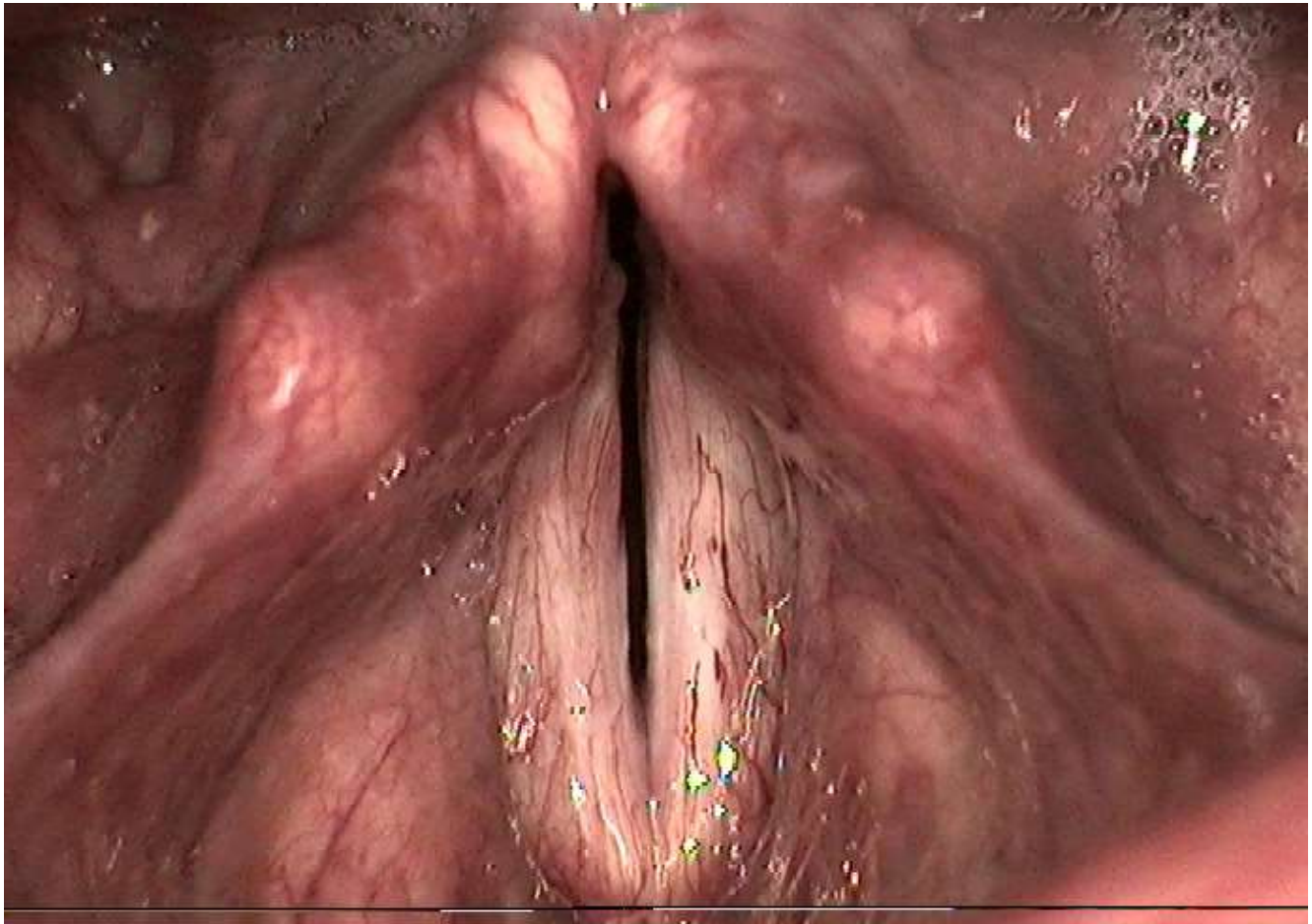


Figure 1:

Bilateral recurrent nerve paralysis with a bilateral vocal fold paralysis in paramedian position (C.C., 50 years old, male, for 18 years RLN - paralysis with dyspnea on light exertion)

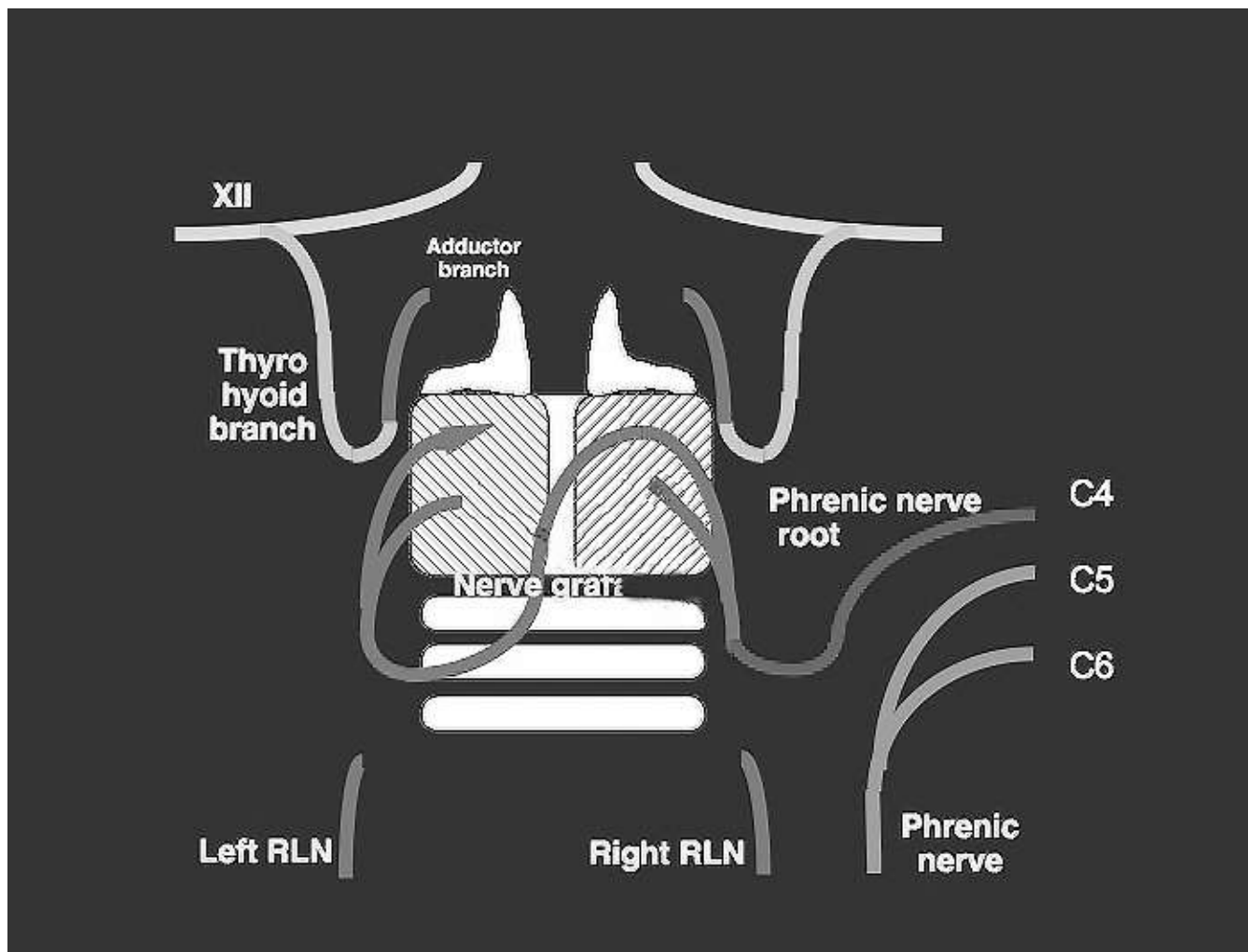


Figure 2:

Concept of the bilateral selective motoric reinnervation of the larynx with the use of the ansa cervicalis bilaterally of the right sided C5 fibers of the phrenic nerve with a free nerve interponate retrocricoidally after J.P. Marie, Rouen, France

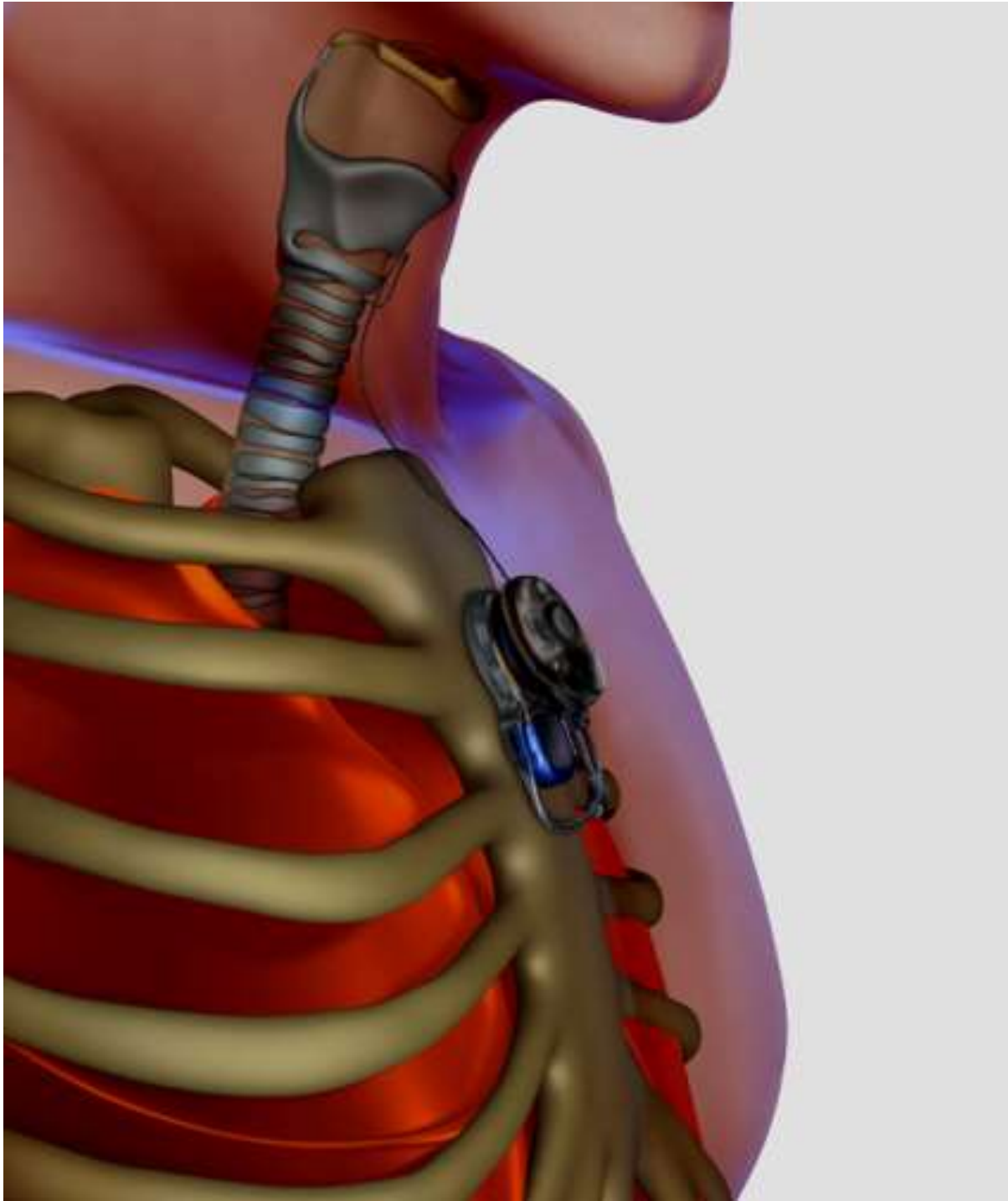


Figure 3:
Principle of selective neurostimulation (pacing) in bilateral vocal fold paralysis with synkinetic reinnervation

Literature

1. Rosenthal LH, Benninger MS, Deeb RH. Vocal fold immobility: a longitudinal analysis of etiology over 20 years. *Laryngoscope* 2007; 117:1864-1870.
2. Schuster M, Eysholdt U. [Therapy for unilateral vocal fold palsy]. *NO* 2005; 53:756-765.
3. Woodson G. Evolving concepts of laryngeal paralysis. *The Journal of laryngology and otology* 2008; 122:437-441.
4. Crumley RL. Laryngeal synkinesis revisited. *Ann Otol Rhinol Laryngol* 2000; 109:365-371.
5. Ozturk K, Turhal G, Kaya I et al. A comparison of two endoscopic posterior cordotomy techniques: Laser cordotomy vs diathermy-assisted cordotomy. *Clin Otolaryngol* 2018; 43:256-260.
6. Feraco P, Bazzocchi A, Righi S, Zampogna G, Savastio G, Salizzoni E. Involvement of cricoarytenoid joints in rheumatoid arthritis. *J Clin Rheumatol* 2009; 15:264.
7. Grosheva M, Wittekindt C, Pototschnig C, Lindenthaler W, Guntinas-Lichius O. Evaluation of peripheral vocal cord paralysis by electromyography. *Laryngoscope* 2008; 118:987-990.
8. Tsunoda K, Kikkawa YS, Kumada M, Higo R, Tayama N. Hoarseness caused by unilateral vocal fold paralysis: how long should one delay phonosurgery? *Acta oto-laryngologica* 2003; 123:555-556.
9. Sittel C, Stennert E, Thumfart WF, Dapunt U, Eckel HE. Prognostic value of laryngeal electromyography in vocal fold paralysis. *Arch Otolaryngol Head Neck Surg* 2001; 127:155-160.
10. Volk GF, Pototschnig C, Mueller A et al. Teaching laryngeal electromyography. *European archives of oto-rhino-laryngology : official journal of the European Federation of Oto-Rhino-Laryngological Societies* 2015; 272:1713-1718.
11. Woodson G. Arytenoid abduction for bilateral vocal fold immobility. *Curr Opin Otolaryngol Head Neck Surg* 2011.
12. Young VN, Rosen CA. Arytenoid and posterior vocal fold surgery for bilateral vocal fold immobility. *Curr Opin Otolaryngol Head Neck Surg* 2011.
13. Pfeiffer J, Laszig R, Maier W. [Intraluminal surgical procedures for glottic enlargement in bilateral vocal fold paralysis in adduction]. *Chirurg* 2011; 82:116, 118-124.
14. Sapundzhiev N, Lichtenberger G, Eckel HE et al. Surgery of adult bilateral vocal fold paralysis in adduction: history and trends. *European archives of oto-rhino-laryngology : official journal of the European Federation of Oto-Rhino-Laryngological Societies* 2008; 265:1501-1514.
15. Nawka T, Sittel C, Gugatschka M et al. Permanent transoral surgery of bilateral vocal fold paralysis: a prospective multi-center trial. *Laryngoscope* 2015; 125:1401-1408.
16. Wang W, Chen D, Chen S et al. Laryngeal reinnervation using ansa cervicalis for thyroid surgery-related unilateral vocal fold paralysis: a long-term outcome analysis of 237 cases. *PLOS One* 2011; 6:e19128.
17. Kodama N, Kumai Y, Sanuki T, Yumoto E. Arytenoid abduction combined with nerve-muscle pedicle flap implantation or type I thyroplasty. *Laryngoscope* 2017; 127:159-166.
18. Blackshaw H, Carding P, Jepson M et al. Does laryngeal reinnervation or type I thyroplasty give better voice results for patients with unilateral vocal fold paralysis (VOCALIST): study protocol for a feasibility randomised controlled trial. *BMJ Open* 2017; 7:e016871.

19. Tucker HM. Reinnervation of the paralyzed larynx: a review. *Head Neck Surg* 1979; 1:235-242.
20. Crumley RL. Phrenic nerve graft for bilateral vocal cord paralysis. *Laryngoscope* 1983; 93:425-428.
21. Marina MB, Marie JP, Birchall MA. Laryngeal reinnervation for bilateral vocal fold paralysis. *Curr Opin Otolaryngol Head Neck Surg* 2011.
22. Marie J-P. Nerve Reconstruction. In: Remacle M, Eckel EH, eds. *Surgery of Larynx and Trachea*. Heidelberg, Tokyo, New York: Springer, 2010:279-294.
23. Li M, Chen S, Zheng H et al. Reinnervation of bilateral posterior cricoarytenoid muscles using the left phrenic nerve in patients with bilateral vocal fold paralysis. *PloS one* 2013; 8:e77233.
24. Song W, Li M, Zheng H et al. [Treatment of bilateral vocal cord paralysis by hemi-phrenic nerve transfer]. *Zhonghua Er Bi Yan Hou Tou Jing Wai Ke Za Zhi* 2017; 52:245-252.
25. Li M, Chen D, Song X et al. The effect of patient age on the success of laryngeal reinnervation. *European archives of oto-rhino-laryngology : official journal of the European Federation of Oto-Rhino-Laryngological Societies* 2014; 271:3241-3247.
26. Zealear DL, Dedo HH. Control of paralysed axial muscles by electrical stimulation. *Acta Otolaryngol* 1977; 83:514-527.
27. Bergmann K, Warzel H, Eckhardt HU, Gerhardt HJ. Respiratory rhythmically regulated electrical stimulation of paralyzed laryngeal muscles. *Laryngoscope* 1984; 94:1376-1380.
28. Zealear DL, Billante CR, Courey M et al. Reanimation of the paralyzed human larynx with an implantable electrical stimulation device. *Laryngoscope* 2003; 113:1149-1156.
29. Li Y, Garrett G, Zealear D. Current Treatment Options for Bilateral Vocal Fold Paralysis: A State-of-the-Art Review. *Clin Exp Otorhinolaryngol* 2017; 10:203-212.
30. Mueller AH. Laryngeal pacing for bilateral vocal fold immobility. *Curr Opin Otolaryngol Head Neck Surg* 2011; 19:439-443.
31. Mueller A, Scholle HC. [Development and clinical evaluation of a laryngeal pacemaker. Final report. BMBF funding priority: Competition prizes to promote medical technology. Duration of the project: 2004-2006] Germany 2006:33 pages, 44 figures, 32 Tables, 74 citations.
32. Foerster G, Arnold D, Bischoff S et al. Pre-clinical evaluation of a minimally invasive laryngeal pacemaker system in mini-pig. *European archives of oto-rhino-laryngology : official journal of the European Federation of Oto-Rhino-Laryngological Societies* 2016; 273:151-158.
33. Cheetham J, Regner A, Jarvis J et al. Functional electrical stimulation of intrinsic laryngeal muscles under varying loads in exercising horses. *PloS one* 2011; 6:e24258.
34. Mueller AH, Hagen R, Foerster G, Grossmann W, Baumbusch K, Pototschnig C. Laryngeal pacing via an implantable stimulator for the rehabilitation of subjects suffering from bilateral vocal fold paralysis: A prospective first-in-human study. *Laryngoscope* 2016; 126:1810-1816.
35. Mueller AH, Hagen R, Pototschnig C et al. Laryngeal pacing for bilateral vocal fold paralysis: Voice and respiratory aspects. *Laryngoscope* 2017; 127:1838-1844.