

REVIEW ARTICLE

Ultrasonographic-assisted femoral nailing: a comprehensive review

Kongkhet Riansuwan*, MD; Banchong Mahaisavariya, MD

Authors' affiliations:

Department of Orthopaedic Surgery and Rehabilitation, Faculty of Medicine Siriraj Hospital, Mahidol University, Bangkok, Thailand

* **Corresponding author:** Kongkhet Riansuwan, Department of Orthopaedic Surgery and Rehabilitation, Faculty of Medicine Siriraj Hospital, Mahidol University, Bangkok, Thailand. Address: 2 Wang Lang Road, Bangkok Noi, Bangkok, Thailand 10700. Phone: +66 (0) 2419 7968; Fax: +66 (0) 2412 8172; Email: kongkhet.ria@mahidol.ac.th

Abstract

Closed intramedullary nailing has long been recognized as a standard treatment for femoral shaft fractures. Normally, a fluoroscope is used to assist in operations involving both a closed fracture reduction and nailing. However, this instrument might not be available at some hospitals, especially those in developing countries. Therefore, an idea to use an alternative modality which can display imaging of the musculoskeletal structures and which is more generally available in hospitals was developed. Ultrasound imaging not only provides a solution for the situation of limited resources but also presents no radiation hazards.

Although many publications and presentations have confirmed the successful application of ultrasound as an alternative method for use in many aspects of closed femoral nailing, no information on reviews has been published. This article therefore aims to present a comprehensive review of sonographic-assisted femoral nailing in terms of its application criteria, requirements, limitations, surgical techniques, clinical outcomes, and possible future applications.

Key words: femoral fracture, intramedullary nailing, closed nailing, ultrasound

1. Introduction

Intramedullary nailing has been recognized as a standard treatment for femoral fractures in adults for many decades. In order to achieve a closed nailing, a fluoroscope is normally used to display an image of the fracture configuration and displacement in

order to assist with fracture reduction and implant insertion. However, the radiation-induced health risks that are faced by both patients and the fluoroscopy operators remain a major concern among surgeons and other operating room personnel. Many initiatives have therefore been implemented to minimize the hazards presented by fluoros-

copy, including the usage of radiation protection equipment (for instance, lead aprons, lead gloves, and light-weight lead glasses) and the employment of other modalities (such as computer navigation, including ultrasonography) instead of an image intensifier.

Ultrasound-guided closed femoral nailing was introduced by one of our senior investigators in 1991 as an alternative methodology, especially when a fluoroscope was not available.¹ Since then, this modality has become of interest to clinicians in many countries.²⁻⁷ The technique is simple, safe, and reproducible.⁸ In order to achieve a successful outcome, however, some requirements need to be taken into consideration, such as the fracture configuration, time to surgery, learning curve, and implant design. Therefore, the present article aims to address this topic by way of a comprehensive review of the criteria for appropriate application of the method, its limitations, the original surgical technique, the outcomes, its recent usage, and its future possibilities.

2. Requirement and application criteria

The procedure was originally conceived for use only in simple femoral shaft fractures in which an ultrasonograph can clearly display the cortical bone shadow of each fracture fragment in both the longitudinal and transverse scans. With this technique, an accurate fracture displacement and the plane of reduction can be demonstrated, and successful reduction and fracture fixation can be achieved. However, sonography is unable to support distal locking screw insertion using the free-hand technique; only unlocked nailing, which is limited to simple fractures, is indicated. Another requirement is the use of a cannulated nail. This permits real-time visualization of a reaming guide-wire on the

ultrasound display screen during a longitudinal scan of the fracture site after adequate distraction and in the absence of an overriding fracture. A successful guide-wire insertion determines the success of the nail insertion. Next, the procedure should be carried out within a week of the patient's injury to ensure that the closed reduction can be performed without encountering any difficulties. If the procedure needs to be delayed beyond 1 week, then a skeletal traction should be performed in order to counteract the deforming force around the fracture site and make the soft tissue more pliable. In addition, it is recommended that this method be performed in the lateral decubitus position with the injured leg up. This affords two benefits. For one thing, it allows easier access to the entry point at the piriformis fossa; in addition, it provides more space to use both the F-shaped reduction clamp and the ultrasound probe at the same time during the closed reduction and intramedullary nailing. On the other hand, the patient needs to be able to tolerate the lateral decubitus position for the whole surgical period.

3. Limitation

The performance of this method of fracture reduction and nailing requires 2 experienced surgeons working as a team: one performing the closed nailing without radiographic visualization, while the other is doing the closed reduction under ultrasound guidance. The greater need for surgical human resources compared to that required for closed nailing under fluoroscopy could be considered to be a limitation of this procedure. Moreover, the need for high surgical expertise and the steep learning curves demanded by both maneuvers (fracture reduction under ultrasound guidance and closed nailing without fluoroscopy) are critical to success.

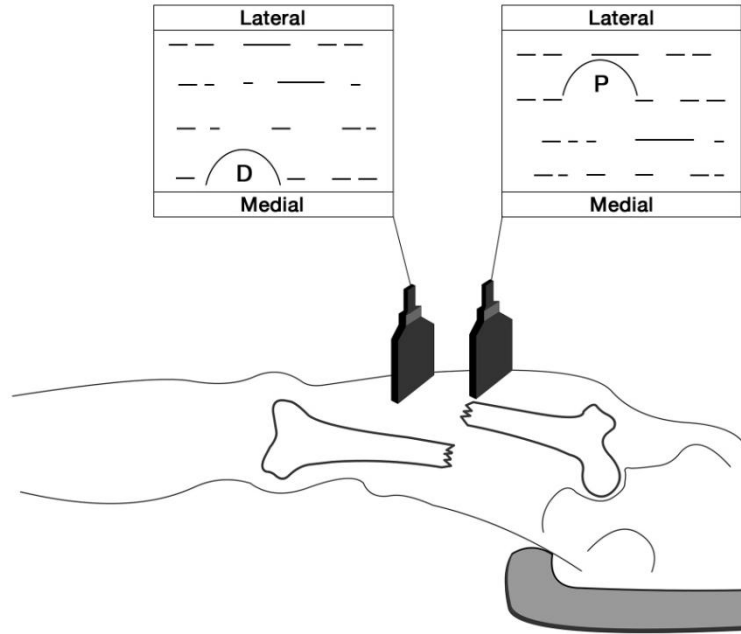


Figure 1. Diagram showing ultrasonogram in transverse scan when fracture site is adequately distracted. Bony cross-section of the distal fragment (D) is away from the probe placed on the lateral thigh, compared to the proximal fragment (P) demonstrating medial displacement of the distal fragment (D)

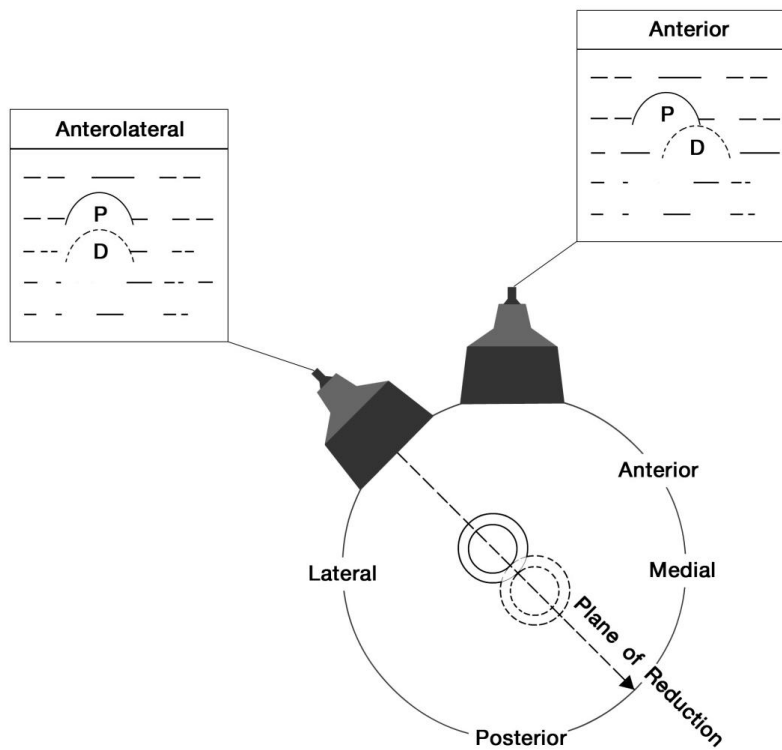


Figure 2. Diagram showing the plane of fracture displacement, representing the direction of reduction force application in transverse scan

4. Original operative technique

The patient is positioned laterally on a fracture table, with the affected limb facing upwards. Each foot is secured with a foot piece holder attached to the traction apparatus of the fracture table. In order to allow good exposure for the application of sonography, both limbs are adjusted so that they are in a zigzag position: the affected limb is placed with 30 degrees of hip flexion and zero degrees of knee extension, while the uninjured limb is left straight. Ultrasound is then applied to evaluate the fracture displacement and assist reduction. A 5MHz linear probe is used to scan the fracture alignment in both the longitudinal and transverse planes. An overriding fracture can be detected by the simultaneous presentation on the ultrasound display screen of the bony cross-section of the proximal and distal fragments in the transverse scan. In this event, traction is applied to the fracture via the foot piece and the traction apparatus against the perineal post. If adequate distraction is achieved, resulting in no overriding of the fracture fragments, the sonogram will reveal a single,

bony cross-section either from the proximal or the distal fragment on the display of the transverse scan (Figure 1). The plane of the fracture reduction is also identified on the transverse scan when the bony cross-sections of the proximal and the distal fragments are aligned in the same plane, although the probe might also reveal that they are at a different depth (Figure 2). The exact plane can be confirmed by rotating the probe to perform a longitudinal scan in the same plane as before. The display screen will show continuity of the bony shadow from the proximal fragment to the distal fragment, but at a different depth, corresponding to the transverse scan (Figure 3). Fracture reduction is carried out by using an F-shaped reduction clamp to manipulate both bony fragments into the correct plane under ultrasound guidance (Figure 4). If the fracture is reduced, the bony shadows will be aligned and continue uninterrupted from the proximal to the distal portion in both the longitudinal and transverse scans. On the other hand, if the fracture cannot be reduced at this point, a C-arm image intensifier is then utilized for the conventional surgical procedure.

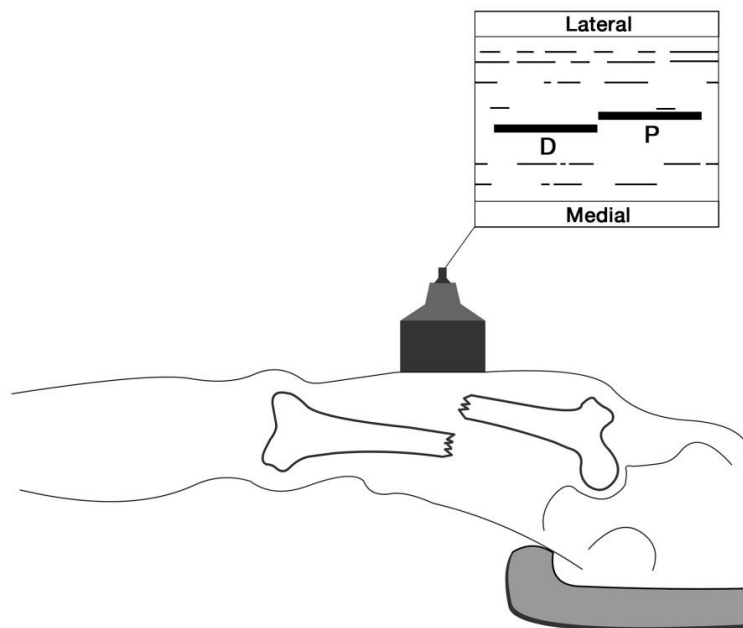


Figure 3. Diagram revealing a longitudinal scan at the fracture site, showing cortical shadows of proximal (P) and distal (D) fragments without overriding

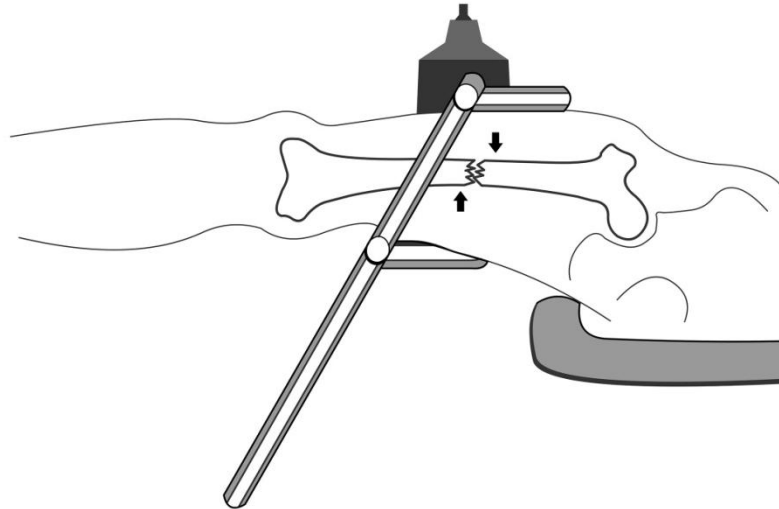


Figure 4. Diagram demonstrating fracture reduction using an F-shaped reduction tool under ultrasound guidance

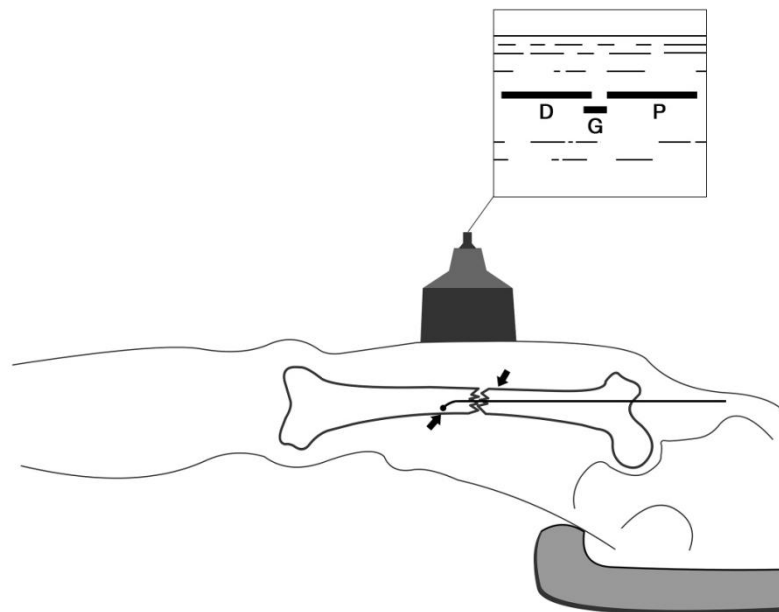


Figure 5. Diagram showing a longitudinal scan while fracture reduction is maintained with an intramedullary reaming guide-wire (G)

Once successful reduction under sonographic guidance is achieved, a sterile drape is applied to the buttock of the affected side of the body in preparation for the surgical approach to the nail entry point. The femoral canal is perforated by an Awl reamer and enlarged step-by-step using T-reamers. A reaming guide-wire is then passed into the proximal femoral canal. The tip of the guide-

wire can be visualized on the ultrasound screen in real-time during the longitudinal scan of the fracture site. The guide-wire subsequently needs to be pulled back into the proximal femoral canal to prevent it becoming an obstacle during the reduction. The fracture is therefore reduced by repeating the previous maneuver under ultrasound guidance. The guide-wire is finally passed

through the fracture site and advanced into the distal femoral canal (Figure 5). A successful guide-wire insertion can be assured by the manual sensation of a rough surface while passing the guide wire into the distal medullary canal, including the feeling of the hard end-point of the femoral canal ending. The ultrasound finally confirms that there is good alignment and continuity of the femoral cortex from the proximal to the distal end, with a guide-wire shadow visible inside the fracture gap in all planes.

Complete femoral canal reaming is then performed, followed by definitive nail insertion. The appropriate nail size and length need to be estimated ahead of the procedure by using the preoperative radiograph to measure the femoral canal size at the level of the isthmus, and to determine the length of the uninjured femur from the palpated greater trochanter to the lateral epicondyle. Intraoperatively, the nail diameter can be confirmed through feeling during the cortical canal reaming, and the nail length can be re-estimated by measuring the length of the reaming guide-wire that is able to be passed into the medullary canal. Postoperative radiographs of the anteroposterior and lateral views of the whole femur are requested immediately after the operation to confirm the procedure was successful.

5. Results

The success rate of closed non-locking nailing under ultrasound guidance for acute simple femoral shaft fractures has been shown to be about 97% (145 cases out of 150), with a mean operative time of 35.8 min (range 30–50).⁷ Failures arise from nail incarceration, broken flexible reamers, and an inability to successfully insert the reaming guide-wire within 10 min.

6. Discussion

Closed nailing is considered to be the standard treatment for femoral fractures. In general, an image intensifier is routinely used to assist with the process of reduction and nailing. However, in the situation where an image intensifier is not available (which is often the case in developing countries) or there is an attempt to minimize risks associated with radiation hazards, ultrasonography is an alternative modality that has been successfully used to aid closed femoral nailing. This technique is simple, safe, and reproducible for simple femoral shaft fractures in which non-locking nailing can be performed during the first week of injury. As ultrasound cannot detect complex fractures with comminution as clearly as simple fractures, this technique is not recommended for locked femoral nailing, especially for distal locking screw insertion using the free-hand technique.

The trend towards the increasing use of locked femoral nails to gain better control of rotational stability, to prevent shortening, and to minimize malrotation, has limited the possibility of using ultrasound for closed femoral nailing at our institute. Additionally, image intensifiers have become more available at many hospitals, even in developing countries. Given all of that, the possibility of using ultrasound to assist with femoral fracture reduction and nailing seems to be very unusual these days. Nevertheless, ultrasound has been employed to obtain a better assessment of the trochanteric entry point for femoral nailing in some specific conditions.⁹ Moreover, the recent designs of targeting devices to achieve distal locking screw insertion in femoral nailing have been promising; therefore, the possibility of doing interlocking nails in a relative simple femoral fracture might be a candidate for reducing radiation exposure. However, more investigation needs to be conducted.

Reference

1. Mahaisavariya B, Suibnugarn C, Mailiang E et al. Ultrasound for closed femoral nailing. *J Clin Ultrasound* 1991; 19: 393-7.
2. Mahaisavariya B, Laupattarakasem W. Ultrasound assisted monitoring of fracture alignment in closed femoral nailing: feasibility study in 80 cases. *Orthop Trans* 1993; 17:1169-70.
3. Mahaisavariya B, Laupattarakasem W. Ultrasound or image intensifier for closed femoral nailing. *J bone Joing Surg (Br)* 1993; 75-B: 66-8.
4. Mahaisavariya B, Laupattarakasem W, Kosuwon W. Experience of the use of ultrasound assessment for closed femoral nailing. *J Jpn Orthop Assoc* 1991; 65: S318.
5. Mahaisavariya B, Songcharoen P, Chotigavanich C. soft-tissue interposition of femoral fractures: detection by ultrasonography during closed nailing. *J Bone Joint Surg (Br)* 1995; 77-B: 788-90.
6. Mahaisavariya B. Ultrasound-guided intramedullary nailing. *Tech Orthop* 1998; 13: 61-70.
7. Mahaisavariya B, Songcharoen P, Riansuwan K. Technique of closed unlocked femoral nailing using ultrasound guidance. *Injury* 2006; 37: 1000-3.
8. Malikhao S. Closed femoral nailing under ultrasound monitoring: brief report from provincial hospital. *Thai J Orthop Surg* 2002; 27: 87-90.
9. Weinrauch P. Ultrasound assisted trochanteric entry point development for antegrade femoral nailing procedures. *Int J Adv Jt Reconstr.* 2015; 15: 7-10.