

CASE REPORT

Pathologic Talar Neck Fracture Resulting from Myxoid Chondrosarcoma of the Tibial Plafond, Talus and Calcaneus

Authors

Tyler Fraser, Ryan Voskuil, Neal Huang, Burton Dunlap, Jesse Doty

Correspondence

Email: tyler.fraser4@gmail.com

Abstract

Case: This case is presented to highlight the rare involvement of the ankle and hindfoot by myxoid chondrosarcoma. The patient was a middle aged male that was previously misdiagnosed as having pigmented villonodular synovitis (PVNS) in his ankle approximately 10 years earlier. He presented to our clinic after the acute onset of pain in his ankle after a therapy session for his lower back without direct trauma to the foot and was found to have a pathologic talar neck fracture Chondrosarcoma is rarely found about the ankle and foot with myxoid chondrosarcoma of the plafond, talus and calcaneus being exceedingly rare. The most common locations for chondrosarcoma are the pelvis, proximal femur, distal femur, and the shoulder girdle. There are only a few case reports of myxoid chondrosarcoma in the talus and calcaneus.

Conclusion: This report reflects the importance of proper diagnosis and the consequences of misdiagnosis that ultimately resulted in below knee amputation (BKA).

Keywords: chondrosarcoma, talus, plafond, calcaneus, PVNS, BKA

INTRODUCTION

Chondrosarcoma is a malignant primary bone tumor most commonly found in the pelvis, femur and shoulder girdle in middle-aged adults. It can be classified as primary or secondary, resulting from transformation from a benign primary lesion such as an osteochondroma or enchondroma. Myxoid chondrosarcoma affecting bone is a rare variant of chondrosarcoma that is considered an intermediate-grade tumor. There is minimal literature of this tumor being found in the foot and ankle. Steiner described a case of skeletal myxoid chondrosarcoma (SMC) of the calcaneus in a middle aged-women that was initially diagnosed as a lipoma for several years¹. Once correctly diagnosed by the authors, the lesion was bone grafted with marginal resection of the tumor as patient refused amputation. The patient eventually underwent below the knee amputation after recurrence. Kwon reported on a 20-year-old patient that was diagnosed

with skeletal myxoid chondrosarcoma of the calcaneus². The patient in that study underwent biopsy and curettage with eventual alcohol cauterization and cement packing. Likely due to the infrequency of this tumor, most case reports show a misdiagnosis or a significant delay in diagnosis.

CASE REPORT

A 67-year-old man presented to our clinic in December of 2018 with pain in his left ankle. On history, he was noted to have been previously diagnosed at an outside facility with PVNS of the left ankle for over 10 years. This diagnosis was based on magnetic resonance imaging (MRI) appearance and a biopsy was not performed. The patient stated he was on an inversion table to help with his back pain when he noticed a slight pain in his left ankle that got progressively worse over the next few weeks with activities. He was seen by another physician and radiographs revealed a pathologic talar

neck fracture and was referred to our clinic. On exam, he was noted to have mild swelling with prominence at the anteromedial ankle joint as well as the posterior soft tissues at the ankle. Radiographs revealed a pathologic fracture through the talar neck with osteolytic involvement of the anterior tibial plafond, nearly the entire talus except for the

proximal body, the anterior 1/3 of the calcaneus with expansion into the anterior and posterior soft tissues. We next obtained an MRI which revealed involvement suggested by the plain radiographs but also extension in the calcaneal tuber, plantar soft tissues medially to the medial cuneiform and proximally 8 cm above the ankle joint posterolaterally adjacent to the fibula.

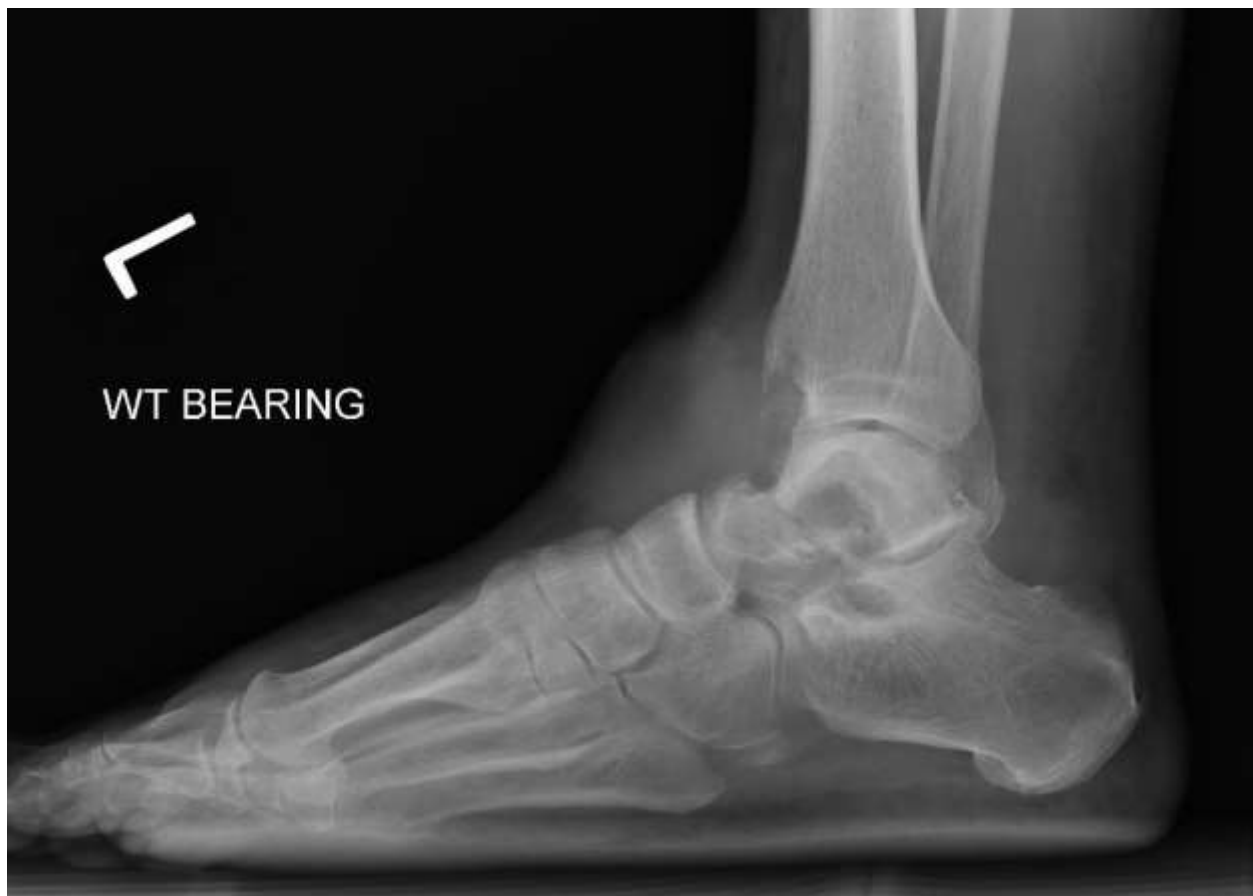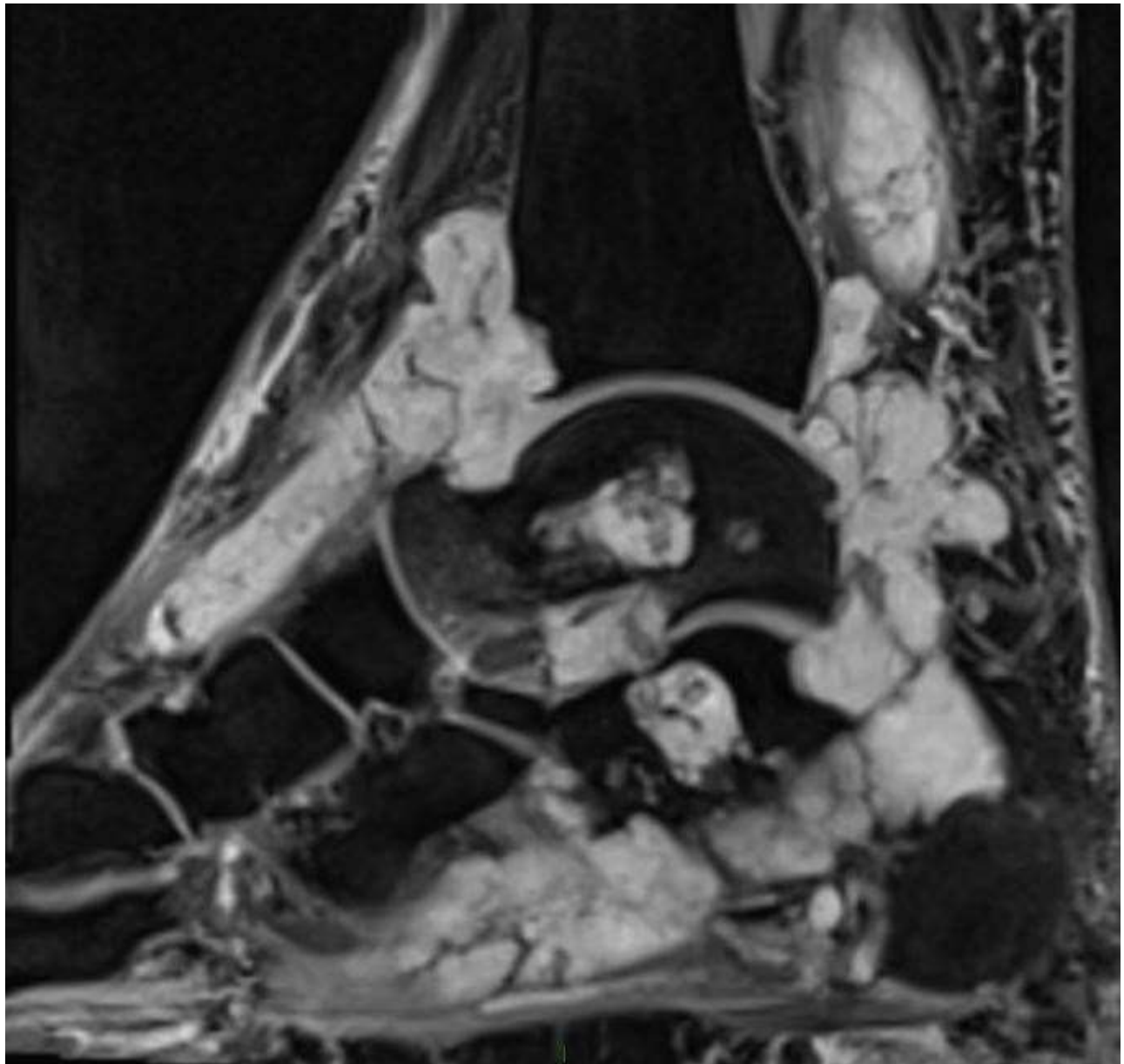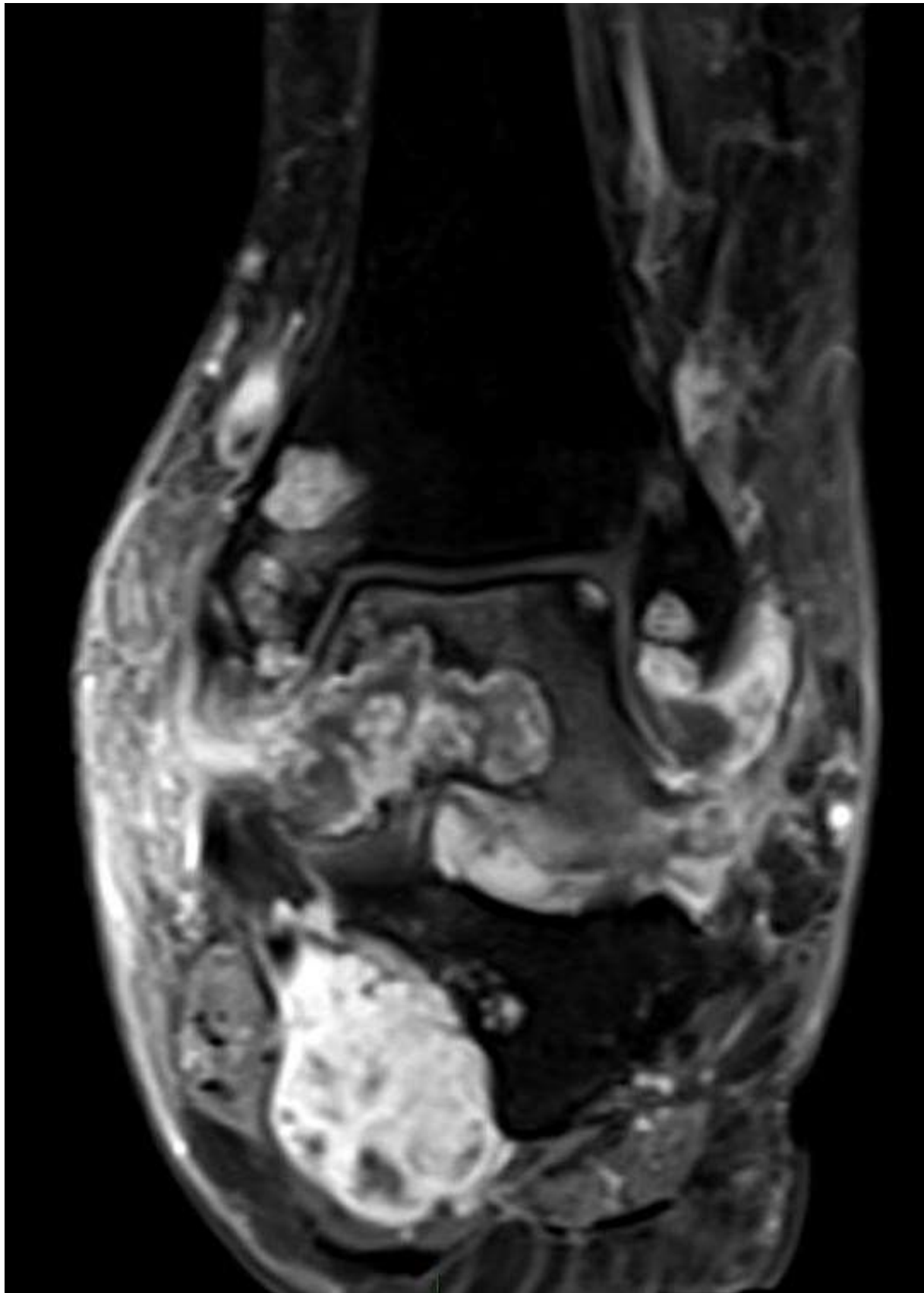


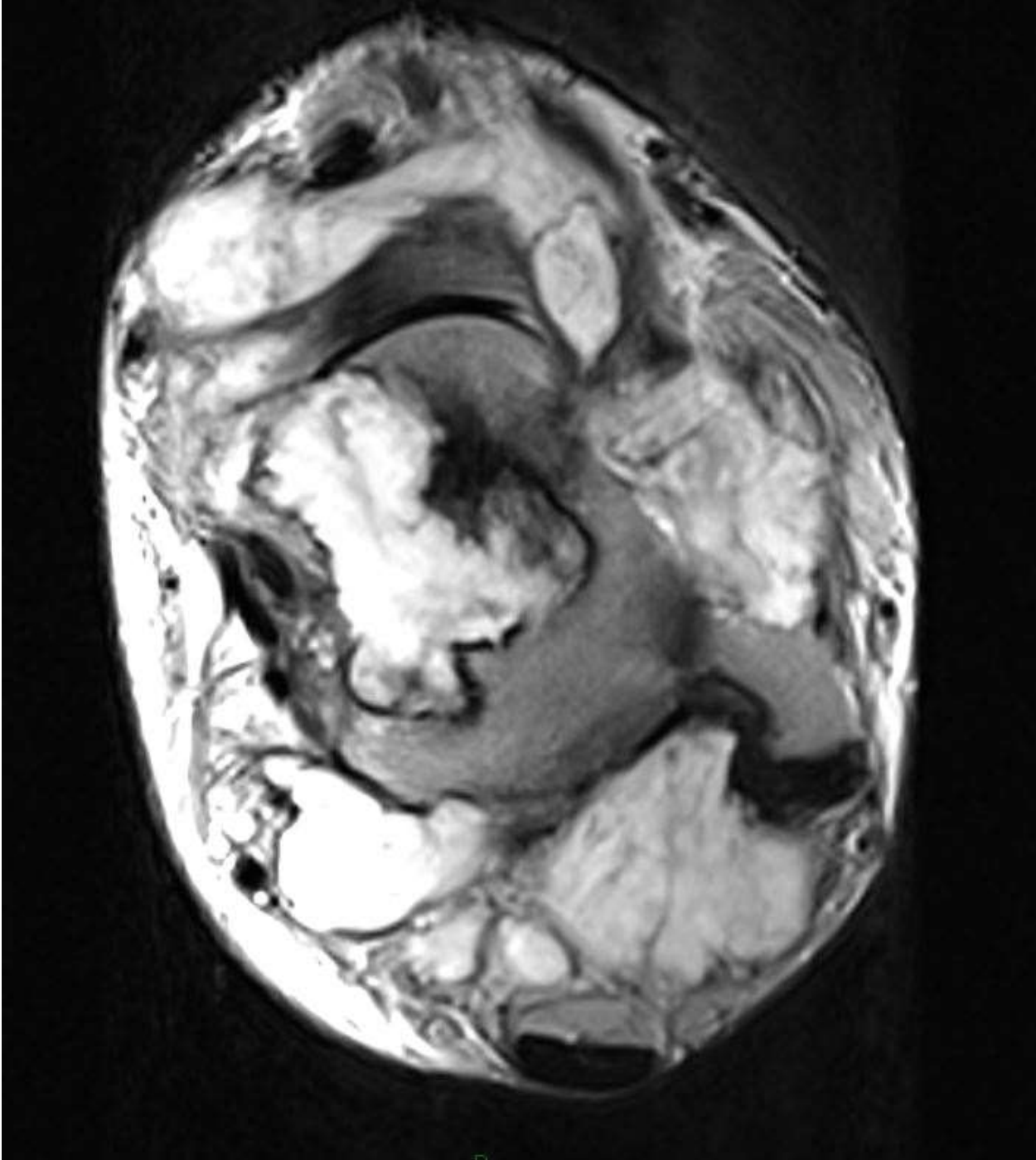
Figure 1: Preoperative lateral radiograph shows anterior soft tissue swelling with osseous destruction of the anterior tibial plafond, talar neck and calcaneus with pathologic talar neck fracture

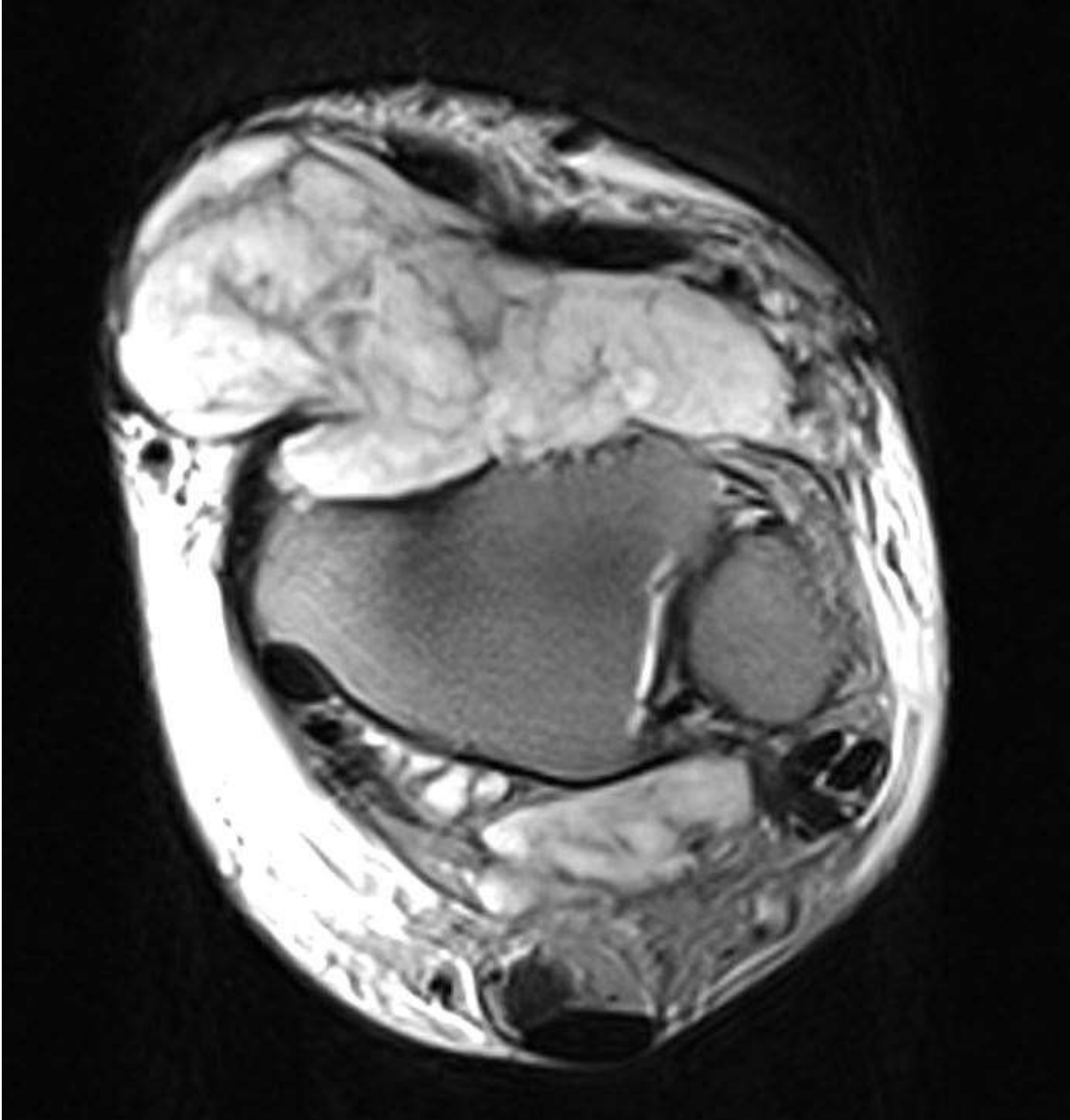
The T1 images show a fairly uniform intermediate-intensity signal. The T2 images show a lobulated heterogenous mass with

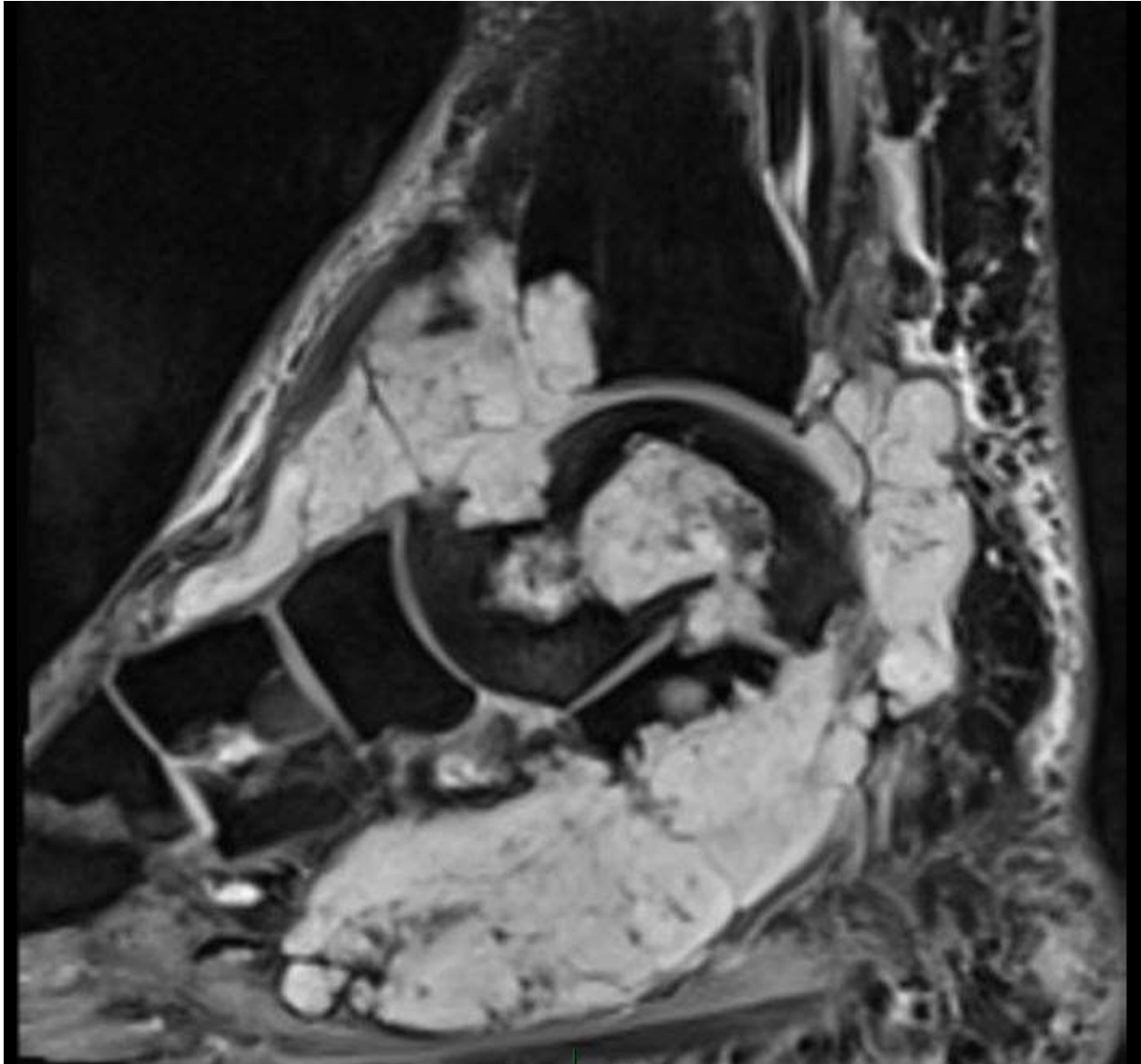
internal septations, hemorrhage and pathologic fracture through the neck of the talus.











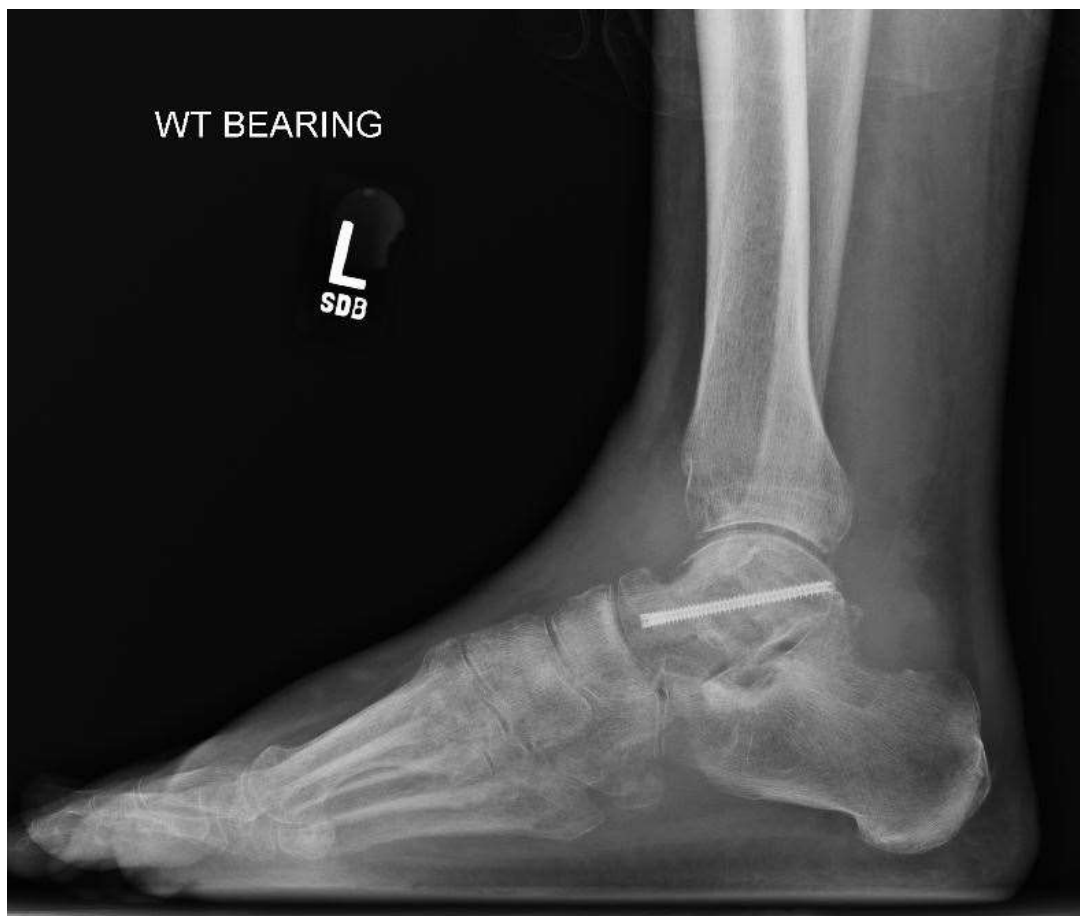Figures 2-6: Sagittal, coronal and axial MRI cuts showing significant tumor burden through the anterior tibial plafond, talar neck and calcaneus with significant soft tissue mass about the ankle

After discussion with the patient about MRI findings and pathologic fracture, the patient was taken to surgery in January of 2019. Through an anteromedial approach, the soft tissue component was removed for biopsy along with bony biopsy of the talus.

For the pathologic fracture of the talar neck, bone graft was placed into the defect and fixation was applied with a compression screw. The patient was then placed into a short leg splint and discharged from with 1-week follow-up to review the pathology

results. The biopsies were review by our pathologist as well as a regional expert on musculoskeletal pathology. The soft tissue and bony biopsies were both consistent with skeletal myxoid chondrosarcoma. Samples contained a predominantly mesenchymal neoplasm of uniform polygonal to spindle

cells arranged in anastomosing cords within a myxoid matrix that focally involved synovium. Immunostains were performed on the samples and were positive for S100 and negative for pancytokeratin, SMA, Desmin and p53.

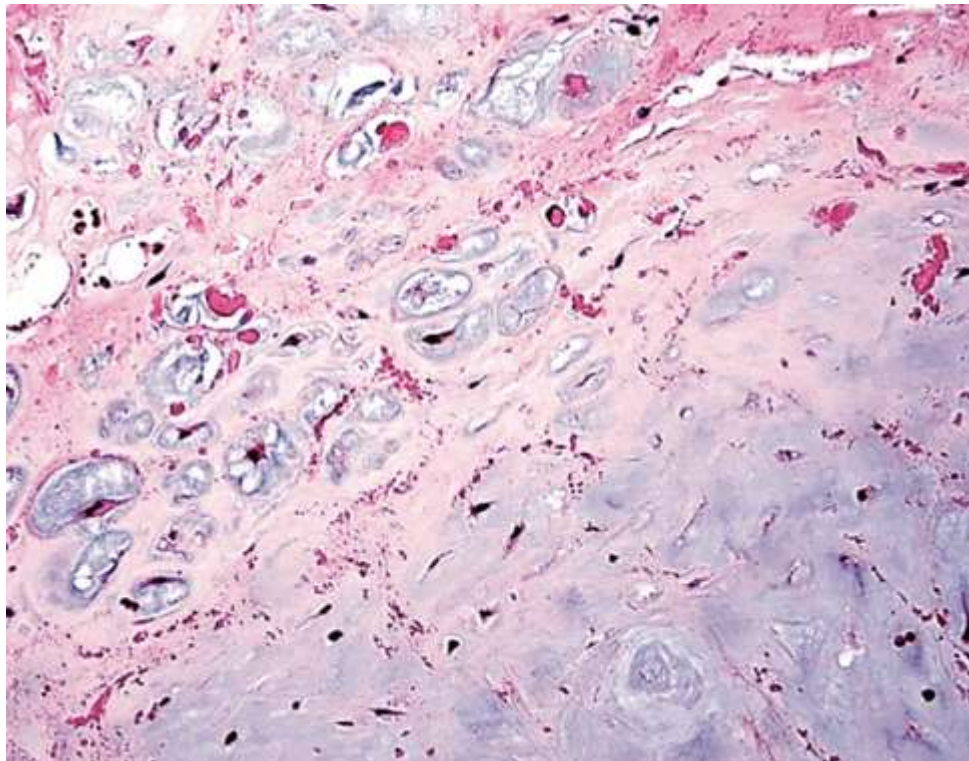


The diagnosis was discussed with the patient at his 1-week postoperative follow-up appointment once the results of the pathology were available. Our center does

not routinely treat primary bone tumors, so the patient was referred to a regional tumor center for expert consultation. The patient underwent standard staging and no evidence

of tumor was found above the distal tibia. After review of the patient history, imaging, and pathology at a tumor board conference, the recommendation for below the knee amputation was made. We discussed this with the patient who chose to have a below-the-knee amputation in April at our facility. The amputated specimen demonstrated pathology consistent with the first samples

and consistent with myxoid chondrosarcoma evident in the distal tibia plafond, talus and calcaneus. The overall size of the lesion was 9.0 x 6.0 x 12.0 cm. The closest margin was 9 cm from the end of the amputation posteriorly. The patient was last seen at 1-year follow-up and doing well, ambulating with a prosthesis.



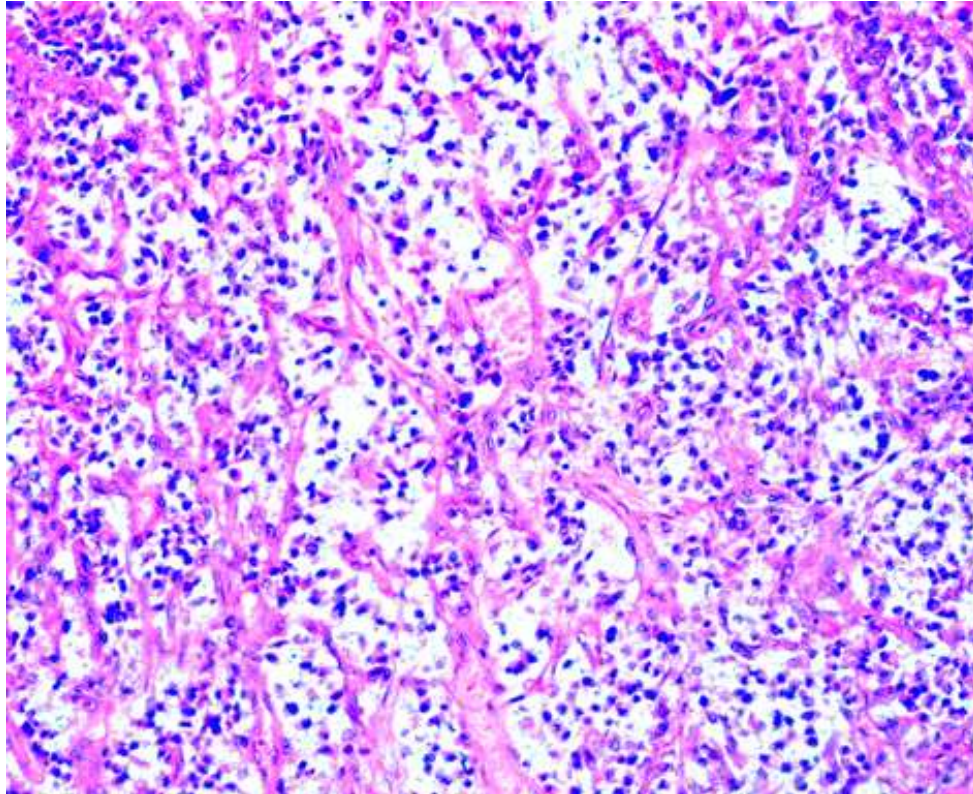


Figure 7: low-and high-power pathology images from resected tumor show predominantly mesenchymal neoplasm of uniform polygonal to spindle cells arranged in anastomosing cords within a myxoid matrix that focally involved synovium. Immunostains were performed on the samples and were positive for S100 and negative for pancytokeratin, SMA, Desmin and p53.

DISCUSSION

Skeletal myxoid chondrosarcoma (SMC) is a very uncommon subtype of chondrosarcoma. The examples of SMC involving the ankle and hindfoot is limited to only a few case reports. Antonescu et al provides an excellent discussion and review of skeletal myxoid chondrosarcoma and extraskeletal myxoid chondrosarcoma (EMC)³. They reviewed 20 consecutive

patients with each tumor. SMCs were defined as having >95% myxoid matrix with only minimal hyaline cartilage. In the SMC group, 5 of the 20 patients had metastases with 4 of the 5 metastasizing to lung. The most common locations of involvement were the long bones of the lower extremities with half of these being near the hip girdle. No patients had involvement of the foot or ankle. One patient had a predisposition to

chondrosarcoma with the diagnosis of Ollier's disease. One key molecular marker that differentiated SMC and EMC was the presence of EWS-CHN t(9;22) fusion gene. This was not present in any of the SMC samples but in 7 of the 9 EMC samples available for testing. Immunostaining for SMC showed positivity only for S-100, EMC was positive for S-100 as well as vimentin and epithelial membrane antigen (EMA). While all patients with SMC underwent en bloc resection of the involved bone, and there was 30% (6 patients) recurrence.

Steiner presents one of the first case reports of myxoid chondrosarcoma of the calcaneus in 1984¹. A 65 year old woman was initially misdiagnosed with a lipoma along the longitudinal arch of her foot. She eventually went on to below-the-knee amputation, after refusing initially, due to

recurrence after biopsy, marginal excision and bone grafting. Kwon present a 20 year-old male with SMC of the calcaneus². The tumor was well-defined and osteolytic on plain radiographs. On MRI, the mass was well-defined lobulated mass of low signal on T1 and intermediate signal on T2. Based on the imaging, the working diagnosis was a chondromyxoid fibroma. The patient was taken for biopsy which showed a proliferative lesion with myxoid stroma consistent with chondromyxoid fibroma. However, the frozen specimen show high cellularity and atypia concerning for chondrosarcoma. Further evaluation of the sample showed cellular nests in myxoid matrix with high mitoses. Staining was positive for S-100 but negative for p53, CD34, and cytokeratin. Based on this, the final diagnosis was myxoid chondrosarcoma of the calcaneus.

References

1. Steiner G., Greenspan A., Jahss M., Norman A., Myxoid Chondrosarcome of the Os Calcis: A Case Report. *Foot and Ankle*. 1984. Vol 5 (2)84-91.
2. Kwon J., Choi J., Kwack K., Oh J. et al. Myxoid chondrosarcoma in the calcaneus: a case report with MR imaging findings. *Skeletal Radiol* 2007. (36) 82-85.
3. Antonescu CR, Argani P, Erlandson RA, Healey JH, Ladanyi M, Huvos AG. Skeletal and extraskeletal myxoid chondrosarcoma: a comparative clinico-pathologic, ultrastructural, and molecular study. *Cancer* 1998;83: 1504–21.
4. Murphey M, Walker E, Wilson A, Kransdorf M, Temple T, Gannon F: Imaging of Primary Chondrosarcoma: Radiologic-Pathologic Correlation. *Radiographics* 2003 Sep-Oct;23(5):1245-78.
5. Gelderbloom H, Hagendoorn P, Dijkstra S, Rijswijk C, Krol A, Taminiau A, Bovee J: The Clinical Approach Towards Sarcoma. *The Oncologist* 2008; 13:320-329.
6. Aarons C, Potter B, Adams S, Pitcher D, Temple T: Extended Intralesional Treatment versus Resection of Low-grade Chondrosarcomas. *Clin Orthop Relat Res* 2009; 468:2105-2111.
7. Babu S., Sudhakar G., Kiran K. Babu T. et al. Calcaneal Chondrosarcoma: A Case Report. *The Foot*. 2013 (23) 166-168.
8. Murari T., Callagan J., Berrey B., Sweet D. Primary Benign and Malignant Osseous Neoplasms of the Foot. *Foot and Ankle*. 1989. (10) 2. 68-80.
9. Chou L., Ho Y., Malawer M. Tumors of the Foot and Ankle: Experience with 153 Cases. *Foot and Ankle International*. 2009 Vol 30 (9) 836-841.