

**CASE REPORT****Long-Term Maintenance of Vision and Resolution of Vitelliform Lesions with Systemic Phosphodiesterase 5/6 Treatment (Sildenafil)****Authors**

D. Jackson Coleman, Winston Lee, Vivienne C. Greenstein, Suzanne Daly, Stephen H. Tsang

**Affiliations**

Department of Ophthalmology, Columbia University Medical Center, New York, NY

**Corresponding author:**

D. Jackson Coleman

Email: djc2188@cumc.columbia.edu

**Abstract**

**Background:** Adult vitelliform macular dystrophy results in loss of central vision. The use of systemic sildenafil has been proven to increase choroidal blood flow. This is a report of a favorable long-term treatment outcome using systemic sildenafil for a patient with adult onset vitelliform macular dystrophy.

**Case Presentation:** A 55-year-old woman presenting with bilateral subretinal vitelliform lesions was initially assessed by full-field electroretinogram, electro-oculogram and direct sequencing of the RDS/PRPH2 and BEST1 genes. Best-corrected visual acuity, spectral domain-optical coherence tomography and color fundus photography were obtained and analyzed over a 5-year treatment course which included bevacizumab (Avastin) injections in the right eye and left eye and subsequent ranibizumab (Lucentis) treatments in the left eye. Lipid resolution in the right eye was seen with bevacizumab after two months of treatment, while the left eye was unresponsive to eight subsequent injections of bevacizumab, followed by ranibizumab over a period of twenty months. Off-label systemic sildenafil was started following the 20-month course of intravitreal injections. There were both measured and patient-reported improvements in the left eye at two months after the initiation of sildenafil.

**Conclusions:** These data appear to support our hypothesis that systemic phosphodiesterase (PDE)-5 and -6 inhibitors may facilitate the removal of lipid and waste from the subretinal space by increasing perfusion in patients with vitelliform lesions and aid in maintaining and/or recovering photoreceptor function.

**Keywords:** vitelliform, macular dystrophy, sildenafil, microperimetry

## **Introduction**

Adult-onset vitelliform macular dystrophy (AVMD) is designated a Rare Disease by the NIH.<sup>1</sup> It is a hereditary disorder characterized by large dome-shaped lesions of sub-retinal lipid deposition (lipofuscin) in the macula that present bilaterally in the fourth and fifth decades of life.<sup>2</sup> Mutations in the RDS/Peripherin<sup>23</sup> and BEST1<sup>4</sup> genes account for many reported cases. Despite our increased understanding of this condition since it was first described by Gass et al.,<sup>5</sup> much is still unknown.

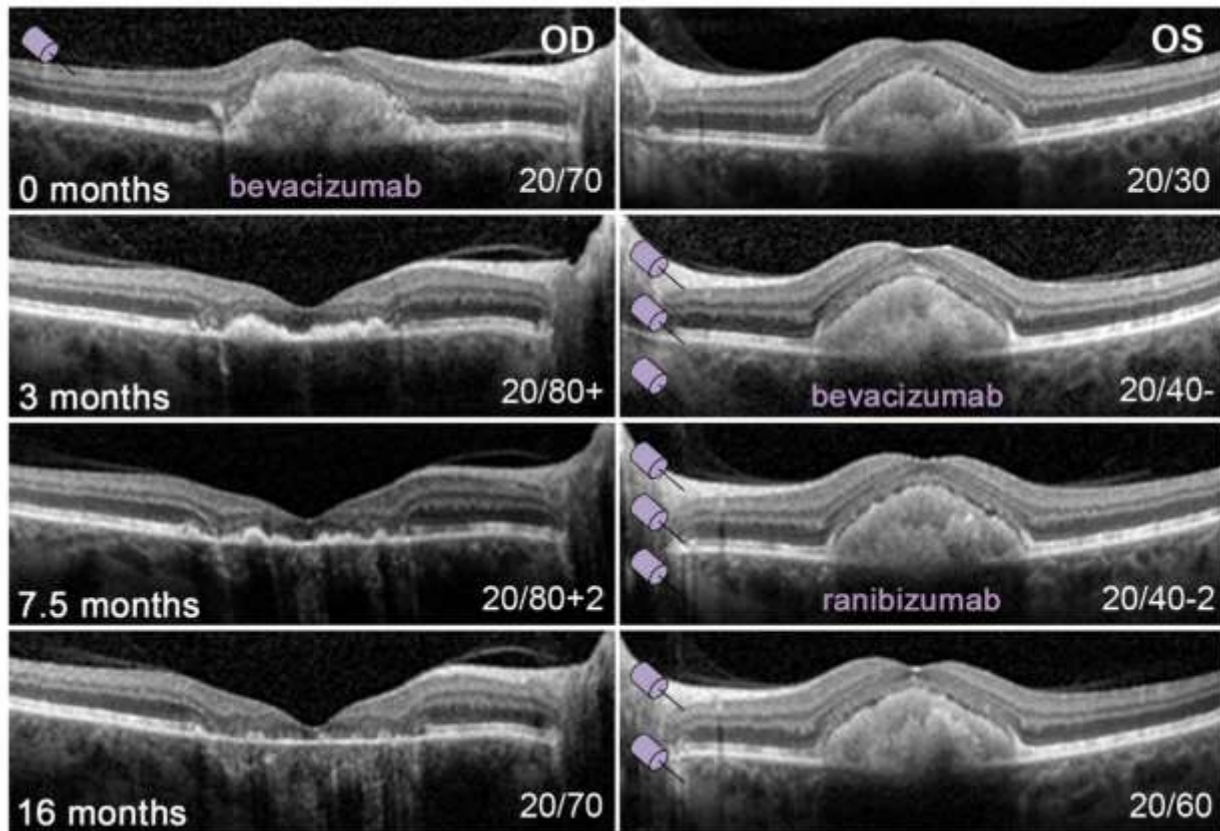
Furthermore, the clinical management of patients remains a challenge, and no reliable treatment has been proven effective with the exception of a few reported cases of concurrent vitelliform with neovascularization that were improved when treated with ranibizumab.<sup>6</sup> The precise composition of the vitelliform lesion remains unclear although it has been found to largely consist of lipofuscin, the accumulation of which in the retinal pigment epithelium (RPE) has been shown to have toxic effects.<sup>7</sup> However, accumulations of lipofuscin in vitelliform lesions have been shown to reside extracellularly between the RPE and photoreceptor layer.

Preservation of retinal layers is time-sensitive to resorption of lipid accumulation in vitelliform lesions. The stages of formation and resolution of vitelliform were described in a study by Soubrane and colleagues et al<sup>8</sup>, however, the physiological trigger remains unknown. This case report shows significant improvements in a 55-year old woman with adult-onset vitelliform macular dystrophy that we treated with systemic sildenafil over five years.

## **Case Report**

The patient was first seen 15 years prior with full field electroretinogram documentation of pattern dystrophy. Visual acuity remained stable following the initial presentation until the patient returned after 15 years with decreased BCVA of 20/40 in the right eye. No treatment was recommended at that time. The patient returned two months later with a BCVA of 20/70 in the right eye and 20/30 in the left. Spectral-domain optical coherence tomography (SD-OCT) revealed large macular sub-retinal deposits in each eye (Figure 1). Intravitreal bevacizumab was used to treat the right eye<sup>9</sup> with subsequent dramatic resolution of the sub-retinal material after 3 months (Figure 1) and which has not since recurred.

### Bevacizumab/Ranibizumab Treatment Course



**Figure 1:** Spectral domain-optical coherence tomography images of the right (OD) and left (OS) eyes recorded over a 16 month interval of a single intraocular injection of bevacizumab in the right eye. Lipid resolution was observed after 3 months. Subsequently, multiple bevacizumab and ranibizumab injections in the left eye did not result in observable resolution of lipid while visual acuity further deteriorated.

Vision in the left eye began to deteriorate shortly after the bevacizumab treatment in the right eye. Within three months BCVA diminished from 20/25 to 20/40-. A total of eight injections of bevacizumab, followed by ranibizumab were administered in the left eye over the next 16 months with no lipid resolution. BCVA remained stable but later decreased to 20/70 in the left eye.

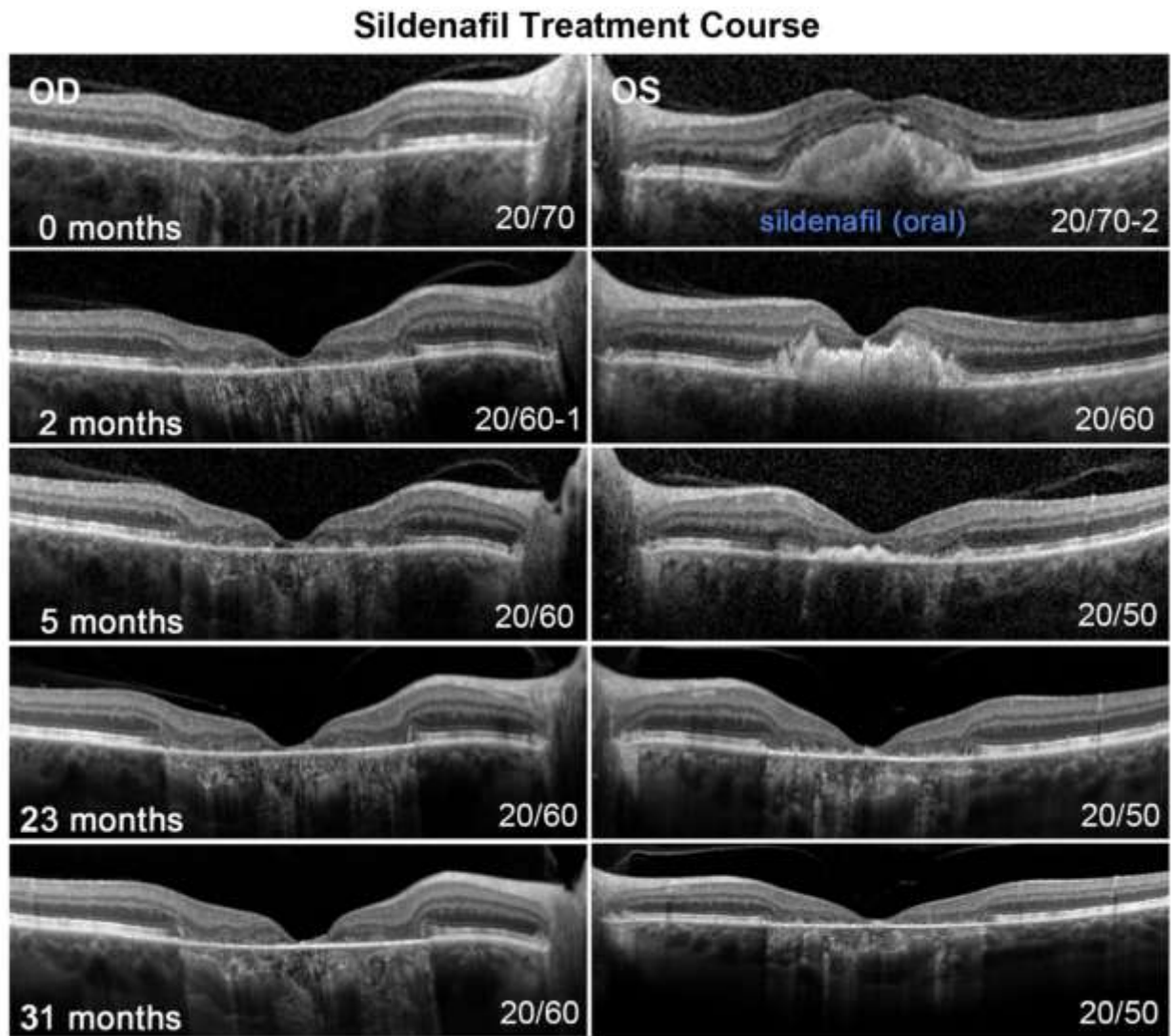
After the deterioration of BCVA in the left eye we carefully explained to the patient findings that showed an association between age-related macular degeneration (AMD) and choroidal ischemia,<sup>10</sup> the encouraging findings from a study that measured perfusion in sildenafil use,<sup>11, 12</sup> as well as the risks of systemic sildenafil use. The patient

gave informed consent to the off-label use of systemic sildenafil 25 mg daily (DJC). After three months this was replaced by Revatio (sildenafil 20 mg three times a day), which is FDA-approved for pulmonary hypertension and was more easily attainable by the patient. Initially the patient was followed and treated monthly or bimonthly. Examinations included slit lamp and dilated fundus exams, BCVA (Snellen chart) color fundus photography, fundus autofluorescence, and spectral domain optical coherence tomography (SD-OCT).

Color fundus photos were obtained using FF450plus Fundus Camera (Carl Zeiss Meditec AG,

Jena, Germany). SD-OCT scans and fundus imaging were obtained using Spectralis HRA+OCT (Heidelberg Engineering, Heidelberg, Germany). Fundus autofluorescence and near infrared reflectance images were obtained using a confocal scanning-laser ophthalmoscope (cSLO, Heidelberg Retina Angiograph 2, Heidelberg Engineering, Heidelberg, Germany).

Within two months on sildenafil, resolution of lipid was noted in the left eye similar to the resolution that occurred in the right with bevacizumab (Figure 2). BCVA improved from 20/70 to 20/50 along with clearing of drusen in the macula and complete resolution of lipid after 23 months (post- on Sildenafil (Figure 2).

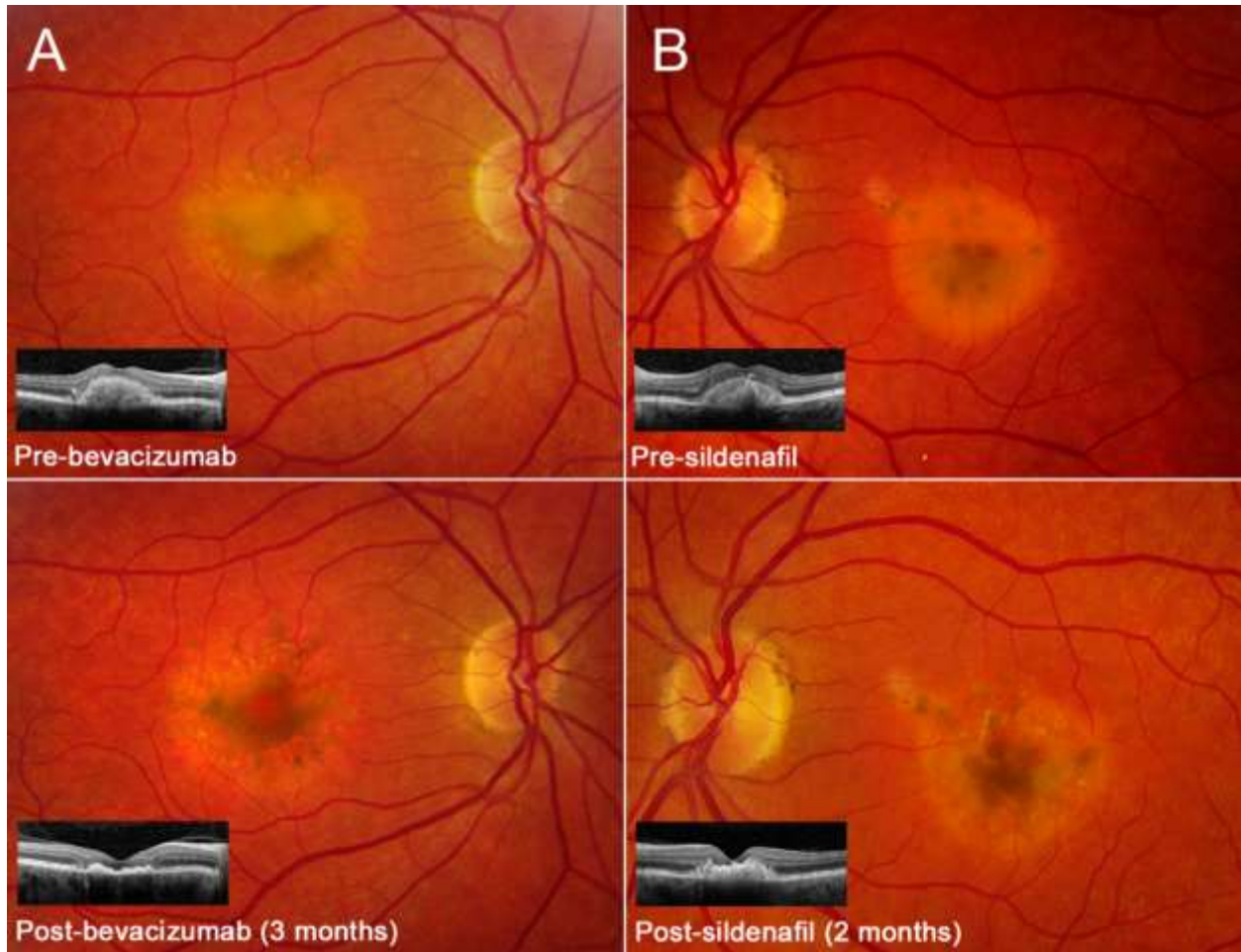


**Figure 2:** Initiation of systemic sildenafil treatment following intraocular injections documented by spectral domain-optical coherence tomography images of the right (OD) and left (OS) eyes. Observable lipid resolution and 1-line improvement in visual acuity (20/70 to 20/60) was noted in the left eye after 2 months. Long-term follow up over 31 months (from initiation of sildenafil) showed stabilization of visual acuity at 20/60 in the right eye and 20/50 in the left eye.



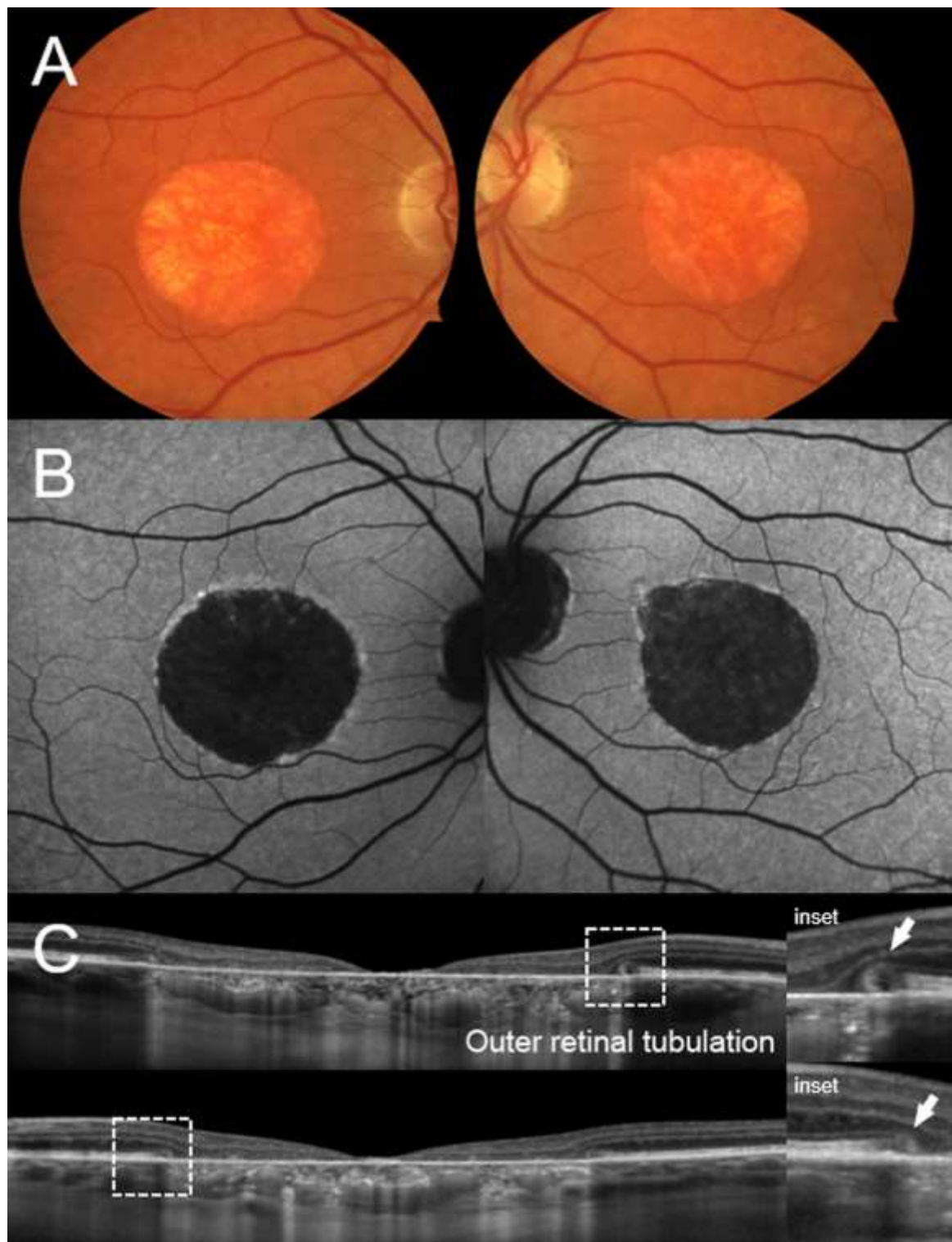
Subjective improvement in visual contrast was also reported by the patient. While lipid material had cleared there was a slight flattening of the foveal architecture on SD-OCT. A comparison of pre- and post-treatment results with bevacizumab and first oral administration of sildenafil found similar fundoscopic outcomes at 3 months in the

right eye (Figure 3A) and at 2 months in the left eye (Figure 3B). The appearance of the left macula continued to show pigment presence, unlike the right eye, which remained devoid of pigment and had the typical appearance of geographic atrophy, the expected outcome in this condition.



**Figure 3:** Comparison of color fundus photographs documenting lipid resolution in response to bevacizumab in right eye (A) and systemic sildenafil in the left eye (B). Corresponding spectral domain-optical coherence tomography (SD-OCT) insets are provided at the bottom left corner.

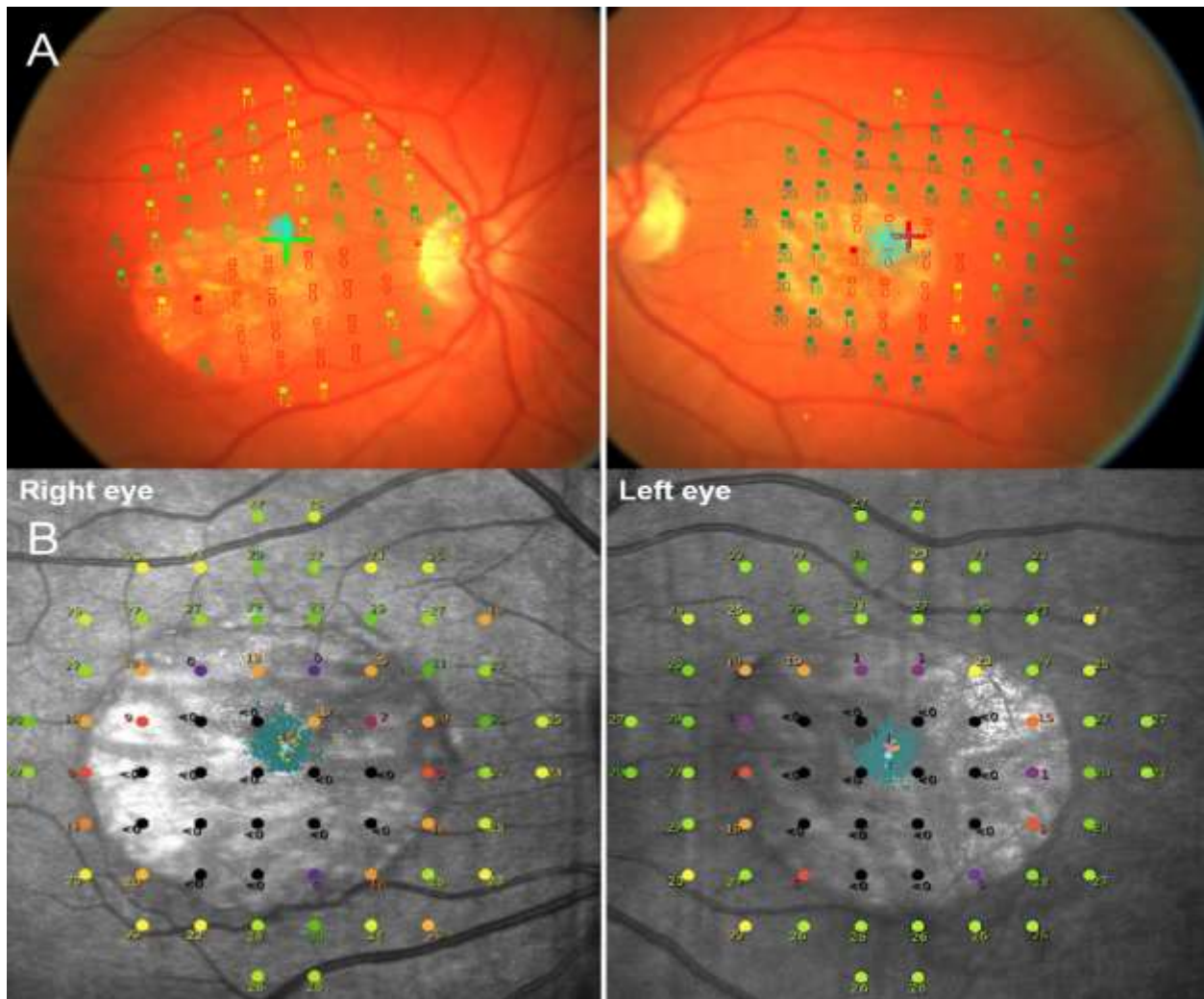
Follow-up at the most recent examination 5 years after beginning continuous sildenafil treatment, BCVA remained stable at 20/60+ in the right eye and 20/60+ in the left eye. Atrophic lesions on funduscopy corresponded to circular dark regions with a well-defined autofluorescent border (Figure 4B). SD-OCT scans revealed outer retinal tubulation at the margin of each lesion (Figure 4C, white arrows). This observation is not completely understood but is thought to indicate cone receptor weakening<sup>13</sup> but also could represent survival of cone receptors.<sup>14, 15</sup>



**Figure 4:** (A) Color fundus photos and (B) autofluorescence imaging of both eyes at the most recent follow up visit. (C) Horizontal spectral domain-optical coherence tomography (SD-OCT) through the fovea reveals hypertransmission of the OCT signal into the choroid and the formation of outer retinal tubulation (inset, white arrow) at the edge of the atrophic lesion.

Microperimetry was first performed at 23 months on Sildenafil treatment. Visual sensitivity using a 10-2 pattern, preferred retinal locus (PRL) and fixation stability were evaluated in both eyes with the Nidek MP-1 which has a dynamic range of 2 log units from 0 dB to 20dB. At that time the PRLs were at the edge of the atrophic area,

approximately 3° superior to the fovea for the right eye and 4° for the left eye. Fixation was stable for both eyes (OD BCEA 95%=0.6°<sup>2</sup>; OS BCEA 95%=1.28°<sup>2</sup>). Visual sensitivities within the atrophic area ranged from <0dB to 16 dB at the edge of the area, and from 6 to 18dB in locations surrounding the lesion.



**Figure 5:** Visual sensitivity and fixation assessed by microperimetry (MP-1) and Macular Integrity Assessment (MAIA) in the central macular area using a 10-2 pattern (68 loci). The measure of visual sensitivity ranged from 0 dB to 35 dB. Clustered turquoise points indicate locations of fixation. Regions of non-recordable sensitivities were noted at the center of the lesion. Adjacent regions exhibited diminished sensitivity; however, the patient maintained stable central fixation throughout the test

At the most recent visit the MAIA microperimeter (Centervue, Padova, Italy) was used; it has a dynamic range from 0 dB

to 35 dB. Visual sensitivity, preferred retinal locus (PRL), and fixation stability were re-evaluated following pupil dilation (0.5%



tropicamide and 2.5% phenylephrine) and 20 minutes of adaptation to dim room illumination. A 10-2 pattern with 68 locations centered on the fovea was used to determine visual sensitivity in the central macular area (Figure 5). The white test lights (stimulus size Goldmann III, 200 ms in duration) were presented on a dim white background (4 asb) using a 4-2 threshold strategy. During testing the patient was asked to maintain fixation in the center of a 1° diameter red annulus. The non-tested eye was occluded.

Fixation stability was quantified in terms of bivariate contour ellipse area (BCEA), and the PRL was defined with reference to the fovea. The sensitivity values, initial and final PRLs, and stability of fixation obtained for the right and left eyes are shown in Figure 5. For the left eye, visual sensitivity values within the atrophic area ranged from <0 dB (non-recordable) to 23 dB at the superior temporal border. For locations surrounding the macular lesion sensitivities ranged from 22 to 31dB with a mean value of 27 dB. The initial and final PRLs were within the foveal area, and fixation was stable (BCEA: 63%=0.6<sup>o2</sup>, 95%=1.8<sup>o2</sup>). The results for the right eye were similar. Sensitivity values within the atrophic area ranged from <0 dB to 19 dB, and from 17 dB to 31dB in locations surrounding the lesion with a mean value of 25 dB. The initial and final

PRLs were also within the foveal area and fixation was stable (BCEA: 63%=0.7<sup>o2</sup>, 95%=2.0<sup>o2</sup>). The sensitivity values we obtained for retinal locations surrounding the macular lesion in both eyes indicate that the underlying photoreceptor layers are relatively "healthy".

Deoxyribonucleic acid (DNA) was extracted from patient blood samples. The entire open reading frame of the BEST1 Gene (OMIM# 607854) was sequenced and analyzed (SHT). No mutations were found in the coding regions. Preliminary screening of the RDS/PRPH2 gene revealed no known

disease causing mutations; however, further analysis is in progress. In addition electro-oculography performed on both eyes using the International Society for Clinical Electrophysiology of Vision (ISCEV) standard<sup>16</sup> showed normal light peak to dark trough ratios; the results were inconsistent with a diagnosis of Best disease.

## Discussion

The reasons for the discrepant responses to bevacizumab between right eye and left eye are unclear, although the positive response in the right eye may be related to occult neovascularization.<sup>9</sup> A causal relationship to photoreceptor function with sildenafil in the left eye cannot be immediately confirmed without further physiological insight; however, given that lipid accumulation in AVMD has been described to progress through five sequential stages: pre-vitelliform vitelliform, pseudohypopyon, vitelliruptive and atrophic,<sup>17</sup> the rapid (approximately two months) resorption of lipid and relative stabilization of visual acuity in the left eye certainly warrants more study. These findings also implicate several hypotheses that may connect the systemic effect of sildenafil and vitelliform resolution. Sildenafil is a cGMP-specific phosphodiesterase type 5 (PDE5) inhibitor typically prescribed for erectile dysfunction and pulmonary arterial hypertension. Sildenafil increases systemic blood flow and includes an observed effect on the choroid<sup>11</sup> which is otherwise parasympathetically regulated by the ciliary ganglion cells through the release of nitric oxide, a messenger molecule produced in endothelial cells of arterioles and the choriocapillaris. The increased turgidity of the choriocapillaris, and particularly small arterioles of Sattler's layers, would facilitate fluid transfer between the choriocapillaris and the interstitial space surrounding RPE cells through a gradient of osmotic and



hydrostatic pressure. Such a mechanism may be governed by Starling's Law, as early proposed by Flower et al to facilitate the removal of waste products (e.g. drusen or vitelliform lipid) and thereby relieve consequent toxicity and/or inflammation in the surrounding cellular milieu.<sup>18, 19</sup> An additional explanation relates the decrease in PDE6 which produces a decrease in Warburg glycolysis to a decrease in acetyl-Gc4 which reduces lipid synthesis.<sup>20</sup> In both scenarios, lipid and drusen are reduced with the use of sildenafil. We have also shown the benefit of sildenafil in patients with central serous chorioretinopathy.<sup>21, 22</sup>

The question of possible recovery of damaged but not yet lost choriocapillaris and RPE afforded by increased choroidal perfusion and reduction of the toxic effect of drusen secondary to sildenafil will require further evaluation. Perhaps earlier removal of these deposits as well as increased perfusion would prevent or delay RPE/photoreceptor loss.

Though further studies are warranted, the choroidal perfusion effects of sildenafil are consistent with our hypothesis that prevention and/or reduction of drusen due to increased choroidal perfusion in vitelliform lesion and dry AMD may benefit from treatment with sildenafil or other PDE5, PDE6 inhibitors.

## **Declarations**

### **Ethics Approval and Consent to Participate**

Sildenafil is an FDA-approved medication. Patient consented to use sildenafil for an off-label indication.

## **Consent for Publication**

Full written consent for publication was obtained from this patient.

## **Availability of Data and Materials**

All data generated or analyzed during this study are included in this published article.

## **Competing Interests**

All authors declare no support from any organization for the submitted work; no financial relationships with any organizations that might have an interest in the submitted work in the previous 3 years; no other relationships or activities that could appear to have influenced the submitted work.

## **Funding**

This study was supported, in part, by grants from the National Eye Institute/NIH (Bethesda, Maryland) P30EY019007 (Core Support for Vision Research; Columbia University), Research to Prevent Blindness (New York, New York) and Foundation Fighting Blindness (Owings Mills, Maryland), and the Triad Foundation.

## **Author's Contributions**

DJC diagnosed and treated this patient and was the primary contributor in writing this manuscript. WL performed data collection and review. VCG analyzed microperimetry data. SD performed collation and review of data and assisted with patient care. SHT performed analysis of patient genetics. All authors read and approved the final manuscript.

## References

1. Adult-onset vitelliform macular dystrophy/Genetic and Rare Diseases Information Center (GARD) [database on the Internet]. NCATS Program. [cited 1/5/2017].
2. Puche N, Querques G, Benhamou N, Tick S, Mimoun G, Martinelli D, et al. High-resolution spectral domain optical coherence tomography features in adult-onset foveomacular vitelliform dystrophy. *Br J Ophthalmol.* 2010 Sep;94(9):1190-6. PubMed PMID: 20576764.
3. Wells J, Wroblewski J, Keen J, Inglehearn C, Jubb C, Eckstein A, et al. Mutations in the human retinal degeneration slow (RDS) gene can cause either retinitis pigmentosa or macular dystrophy. *Nat Genet.* 1993 Mar;3(3):213-8. PubMed PMID: 8485576.
4. Petrukhin K, Koisti MJ, Bakall B, Li W, Xie G, Marknell T, et al. Identification of the gene responsible for Best macular dystrophy. *Nat Genet.* 1998 Jul;19(3):241-7. PubMed PMID: 9662395.
5. Gass JD. A clinicopathologic study of a peculiar foveomacular dystrophy. *Trans Am Ophthalmol Soc.* 1974;72:139-56. PubMed PMID: 4142662. Pubmed Central PMCID: PMC1311393.
6. Heier JS, Antoszyk AN, Pavan PR, Leff SR, Rosenfeld PJ, Ciulla TA, et al. Ranibizumab for treatment of neovascular age-related macular degeneration: a phase I/II multicenter, controlled, multidose study. *Ophthalmology.* 2006 Apr;113(4):633 e1-4. PubMed PMID: 16483659.
7. Sparrow JR, Nakanishi K, Parish CA. The lipofuscin fluorophore A2E mediates blue light-induced damage to retinal pigmented epithelial cells. *Invest Ophthalmol Vis Sci.* 2000 Jun;41(7):1981-9. PubMed PMID: 10845625.
8. Benhamou N, Souied EH, Zolf R, Coscas F, Coscas G, Soubrane G. Adult-onset foveomacular vitelliform dystrophy: a study by optical coherence tomography. *Am J Ophthalmol.* 2003 Mar;135(3):362-7. PubMed PMID: 12614755.
9. Da Pozzo S, Parodi MB, Toto L, Ravalico G. Occult choroidal neovascularization in adult-onset foveomacular vitelliform dystrophy. *Ophthalmologica.* 2001 Nov-Dec;215(6):412-4. PubMed PMID: 11741106.
10. Coleman DJ, Silverman RH, Rondeau MJ, Lloyd HO, Khanifar AA, Chan RV. Age-related macular degeneration: choroidal ischaemia? *Br J Ophthalmol.* 2013 Aug;97(8):1020-3. PubMed PMID: 23740965. Pubmed Central PMCID: PMC3717761.
11. Kim DY, Silverman RH, Chan RV, Khanifar AA, Rondeau M, Lloyd H, et al. Measurement of choroidal perfusion and thickness following systemic sildenafil (Viagra((R))). *Acta Ophthalmol.* 2013 Mar;91(2):183-8. PubMed PMID: 22974308. Pubmed Central PMCID: PMC3528845.
12. Vance SK, Imamura Y, Freund KB. The effects of sildenafil citrate on choroidal thickness as determined by enhanced depth imaging optical coherence tomography. *Retina.* 2011 Feb;31(2):332-5. PubMed PMID: 20975620.
13. Jung JJ, Freund KB. Long-term follow-up of outer retinal tubulation documented by eyetracked and en face spectral-domain optical coherence tomography. *Arch Ophthalmol.* 2012 Dec;130(12):1618-9. PubMed PMID: 23229712.
14. Litts KM, Ach T, Hammack KM, Sloan KR, Zhang Y, Freund KB, et al. Quantitative Analysis of Outer Retinal Tubulation in Age-Related Macular Degeneration From Spectral-Domain Optical Coherence Tomography and Histology. *Invest Ophthalmol Vis Sci.* 2016 May

1;57(6):2647-56. PubMed PMID: 27177321. Pubmed Central PMCID: PMC4868096.

15. Schaal KB, Freund KB, Litts KM, Zhang Y, Messinger JD, Curcio CA. Outer retinal tubulation in advanced age-related macular degeneration: Optical Coherence Tomographic Findings Correspond to Histology. *Retina*. 2015 Jul;35(7):1339-50. PubMed PMID: 25635579. Pubmed Central PMCID: PMC4478232.

16. Marmor MF, Brigell MG, McCulloch DL, Westall CA, Bach M, International Society for Clinical Electrophysiology of V. ISCEV standard for clinical electro-oculography (2010 update). *Doc Ophthalmol*. 2011 Feb;122(1):1-7. PubMed PMID: 21298321.

17. Querques G, Regenbogen M, Quijano C, Delphin N, Soubrane G, Souied EH. Highdefinition optical coherence tomography features in vitelliform macular dystrophy. *Am J Ophthalmol*. 2008 Oct;146(4):501-7. PubMed PMID: 18619572.

18. Anderson DH, Mullins RF, Hageman GS, Johnson LV. A role for local inflammation in the formation of drusen in the aging eye. *Am J Ophthalmol*. 2002

Sep;134(3):411-31. PubMed PMID: 12208254.

19. Flower RW, Fryczkowski AW, McLeod DS. Variability in choriocapillaris blood flow distribution. *Invest Ophthalmol Vis Sci*. 1995 Jun;36(7):1247-58. PubMed PMID: 7775102.

20. Coleman DJ, Lee W, Chang S, Silverman RH, Lloyd HO, Daly S, et al. Treatment of Macular Degeneration with Sildenafil: Results of a Two-Year Trial. *Ophthalmologica*. 2018;240(1):45-54. PubMed PMID: 29694963.

21. Breazzano MP, Coleman DJ, Chen RWS, Chang S, Daly S, Tsang SH. Prospective impact of sildenafil on chronic central serous chorioretinopathy: PISCES Trial. *Ophthalmol Retina*. 2020 Nov;4(11):1119-1123. PubMed PMID: 32525054

22. Coleman DJ, Lee W, Daly S, Breazzano MP, Sparrow J, Tsang SH. Central serous chorioretinopathy treatment with a systemic PDE5 and PDE6 inhibitor (sildenafil). *Am J Ophthalmol Case Rep*. 2020 Dec 3;21:100998. PubMed PMID: 33364520.