

**CASE REPORT****Spontaneous Pneumomediastinum in a SARS-CoV-2 Positive Patient Treated with High-flow Nasal Cannula: A Case Report****Authors**

I. Takorov, Ts. Lukanova, S. Simeonovski, D. Vylcheva, D. Dimitrov, Ts. Stanimirov, S. Arnaudov, M. Abrasheva

**Affiliation**

First Clinic of Abdominal Surgery, Military Medical Academy, Sofia, Bulgaria

**Correspondence address:**

Tsonka Lukanova

Email: [priluki@abv.bg](mailto:priluki@abv.bg)

**Abstract**

Spontaneous pneumomediastinum is one of the few rare complications of coronavirus disease – 19 (COVID-19) pneumonia. We report a case of a male patient with COVID-19 disease, severe pneumonia and spontaneous pneumomediastinum, supported via high-flow nasal cannula (HFNC) oxygen supplementation. Factors causing pneumomediastinum are discussed, but further research is still necessary.

**Keywords:** COVID-19, high-flow nasal cannula, spontaneous pneumomediastinum

## Introduction

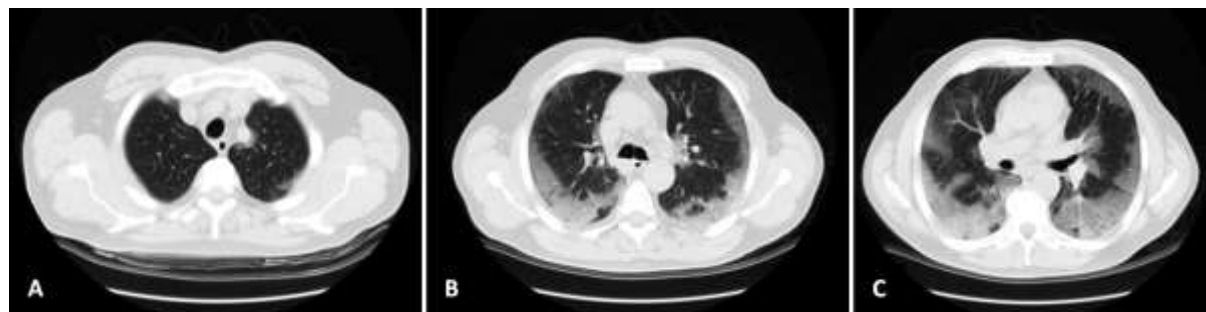The first cases of severe acute respiratory syndrome caused by the novel coronavirus 2 (SARS-CoV-2) emerged from Wuhan, China in December 2019.<sup>1</sup> The disease caused by this virus was called COVID-19 and by March 11 in 2020, the COVID-19 outbreak was declared global pandemic. The most common initial presentation symptoms of the disease are fever, cough, loss of smell or taste, fatigue, myalgia, shortness of breath or dyspnea, gastrointestinal symptoms such as diarrhea or nausea, headaches, etc.<sup>2,3</sup> Some patients deteriorate rapidly to acute respiratory distress syndrome, accompanied by a state of hypercoagulability and need to be transferred to an intensive care unit (ICU). Radiology is a cornerstone in the diagnosis and surveillance of a COVID-19 patient. Multiple patchy ground-glass opacities with peripheral distribution are typical findings at computerized tomography (CT) in patients with COVID-19 pneumonia.<sup>4</sup> The occurrence of spontaneous pneumomediastinum is an uncommon phenomenon, with an incidence rate of 3 per 100,000. As severe COVID-19 progresses to acute respiratory failure requiring high concentration of inspired oxygen, HFNC is a therapeutic strategy which improves oxygenation and carbon dioxide clearance. Spontaneous pneumomediastinum is an uncommon pathology, which is benign and self-limiting. It presents mostly with dyspnea and chest pain. It is mainly caused by sudden increase in thoracic pressure, which leads to air dissection along the bronchovascular structures inside the mediastinum. Pulmonary disease, forceful coughing or sneezing, pulmonary infections

and smoking may predispose to this condition. SARS-CoV-2, infecting type I and II pneumocytes, can lead to destruction of the integrity of the alveolar membrane, causing alveolar rupture. We present a case of spontaneous pneumomediastinum (SPM) in a patient with COVID-19 pneumonia, treated protractedly with HFNC.

## Case report

A 65-year-old patient with hypertension was admitted to our department, complaining of dry cough, shortness of breath, malaise and fever, with temperature of up to 39 degrees in the past 3 days. A nasal pharyngeal swab for real-time polymerase chain reaction (RT-PCR) detecting SARS-CoV-2 was sent and resulted positive. Upon presentation, physical examination showed decreased breath sound, deep breathing with dyspnea and temperature reaching 38 degrees. Respiratory rate was around 30 breaths per minute. Blood pressure was 160/77 mmHg and heart rate was 75 beats per minute. On pulse oximetry, the patient was oxygenating at 70% in ambient air. Oxygen support was initiated immediately with 15 liters per minute on non-rebreather mask to reach oxygen saturation (SpO<sub>2</sub>) of 96%. Blood tests results showed normal leukocyte count of  $5.6 \times 10^9/L$ . Lymphocyte count was decreased –  $0.98 \times 10^9/L$  (normal  $1.18 - 3.74 \times 10^9/L$ ). C – reactive protein (CRP), lactate dehydrogenase (LDH), serum ferritin and interleukin 6 (IL-6) were elevated as follows: 46.2 mg/L (normal 0 – 5 mg/L), 671 U/I (200 – 370 U/I), 1114 µg/L (20 – 250 µg/L) and 76.3 pg/ml (5.3 – 7.5 pg/ml). For the assessment of the severity of lung damage, a non-contrast chest CT was established (*fig. 1*),

which revealed bilateral ground-glass opacities in up to 50% of the lung parenchyma.

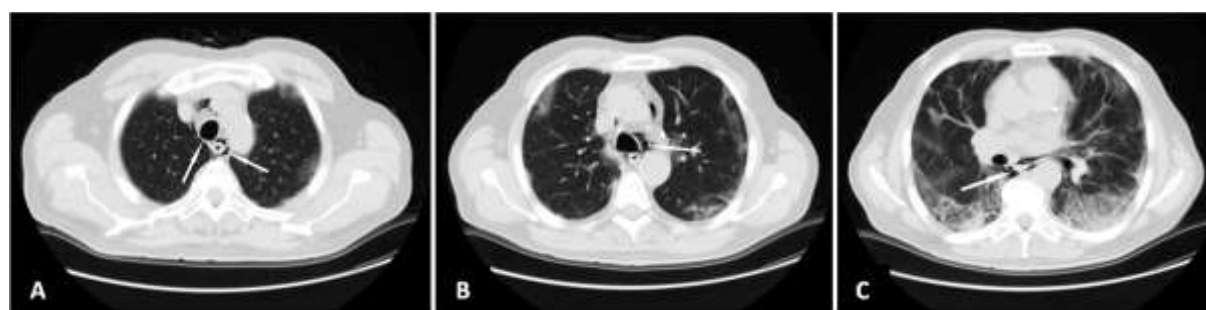

**Figure 1:** Axial CT chest images showing bilateral ground-glass opacities, predominantly in peripheral (A, B) and lower regions of the lungs (C).

Based on the patient's COVID-19 status, empiric treatment was started with antibiotics – cefoperazone/sulbactam and levofloxacin for 10 days, substituted with piperacillin/tazobactam for additional 10 days and at the end doxycycline was administered. Remdesivir and corticosteroids – methylprednisolon and dexamethasone were also given, with nadroparin as anticoagulation therapy. The patient was also instructed to self-prone. The next 48 hours the patient's condition worsened. His SpO<sub>2</sub> dropped to 89% on 15 l/min, so we were forced to start oxygen

therapy with HFNC with non-rebreather mask which in the next few days reached fraction of inspired oxygen (FiO<sub>2</sub>) of 100% on flow of 40 l/min. The patient was stable with oxygen saturation of above 95%.

18 days after admission, the patient complained of chest pain, which increased with respiratory acts. An electrocardiogram was performed and cardiac enzymes were measured. Both were normal and did not support myocardial infarction. We performed another CT scan, which showed extensive pneumomediastinum (*fig.2*).



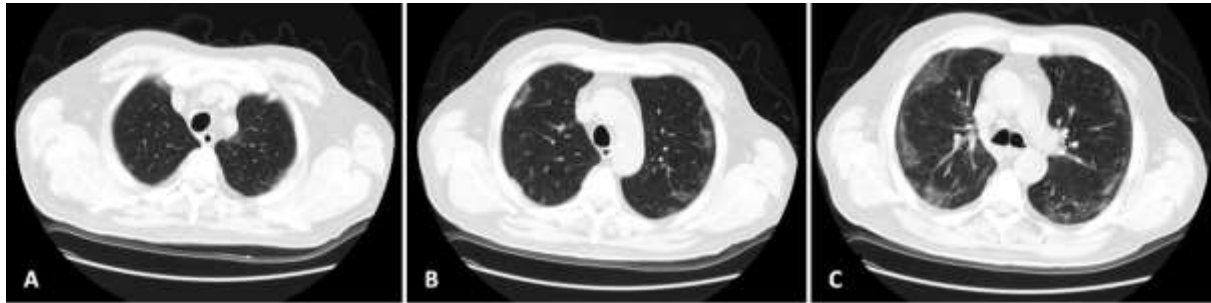
**Figure 2:** Axial CT images (A, B and C) showing the presence of air (arrows) in the mediastinal region.

The oxygen treatment with HFNC continued, as lower flow and FiO<sub>2</sub> were not affordable with the current status of the

patient. He maintained hemodynamic stability and chest pain was managed with analgetics. His condition gradually improved, HFNC was

withdrawn and chest pain disappeared. Control CT scan was performed 1 month after hospitalization, which documented complete resolution of the pneumomediastinum and partial resorbtion of the COVID-19 associated

inflammatory lung changes (*fig. 3*). 8 days later the patient was discharged eupneic, without any signs of respiratory failure and without the need of oxygen support.



**Figure 3:** Axial CT images (A, B and C) showing complete resolution of the pneumomediastinum and partial resorbtion of the ground-glass opacities.

## Discussion

Spontaneous pneumomediastinum is an uncommon pathology in general population. It occurs in young male patients in more than 75% of the cases.<sup>5</sup> It is defined as the presence of air in the mediastinum without evident causes – traumatic, iatrogenic, surgery, hollow organ perforation or gas producing infections.<sup>6</sup> Several lung infections, mainly influenza, can lead to pneumomediastinum.<sup>7-9</sup> In our case, alterations caused by SARS-COV-2 infection, favoured by HFNC and other conditions, probably caused the pneumomediastinum. Considered idiopathic in origin, SPM can be caused by factors leading to high intra-alveolar pressure such as coughing, emesis and mechanical ventilation.

SARS-COV-2 infects type I and II pneumocytes, which may cause damage to the integrity of the alveolar membrane, inhibits the production of surfactant, impairs lung compliance and concludes in rupture of the alveoli.<sup>10</sup> In addition, indirect mechanisms due

to cytokine storm and thrombosis events may play a role in weakening the alveolar membrane.<sup>11,12</sup> The released air dissects through pulmonary interstitium, along the bronchovascular hilus, where finally reaches the mediastinal region. This pathophysiological mechanism was first described in 1994 and is known as the Macklin effect.<sup>13</sup> It can occur in conditions leading to extreme respiratory effort, mimicking the Valsalva maneuver, like sneezing, coughing, marijuana smoking, rapid reduction in atmospheric pressure or diabetic ketosis.<sup>14</sup>

High-flow nasal cannula delivers a mixture of air and oxygen, heated and humidified, which can be delivered at a higher flow than the patient's inspiratory peak. As the only inhaled oxygen is that coming from the nasal cannulas, FiO<sub>2</sub> set on the high-flow device corresponds to that inhaled by the patient. HFNC also has a beneficial effect on CO<sub>2</sub> washout. It is considered to be safer and gentler than mechanical ventilation.<sup>15</sup>

However, pneumomediastinum as a rare complication of HFNC even in non-COVID-19 patients was reported.<sup>16</sup>

The clinical presentation of SPM can range from being asymptomatic to various symptoms like dysphagia, dyspnea, cough, chest pain and voice changes. Definitive diagnosis of pneumomediastinum can be established with CT, as chest X-ray may miss this pathology if lateral film is not ordered. The gas can be anterior to the pericardium, around the pulmonary artery and major aortic branches, between the parietal pleura and in the pulmonary ligaments. It is presented on a CT as dark areas of attenuation.<sup>17</sup>

Gorospe et al.<sup>18</sup> reported four cases of patients with COVID-19 pneumonia with spontaneous pneumomediastinum. In that serie of cases, no mechanical ventilation, but only non-invasive oxygen therapy was used prior to the occurrence of pneumomediastinum and in three of the patients, the condition resolved spontaneously.

SPM is generally benign, self-limiting disease. Treatment mainly consists of rest, oxygen therapy, antitussives and bronchodilators.<sup>19</sup> More invasive treatment options, but less frequently used are chest drain insertion, vacuum-assisted closure dressings and needle aspiration. Meticulous monitoring is needed in order to avoid complications as tension pneumothorax or cardiac tamponade. SPM independent of mechanical ventilation is related to high mortality index, which makes it a poor prognostic factor in cases of COVID-19 pneumonia.<sup>20</sup>

## Conclusion

Although spontaneous pneumomediastinum is a rare complication of COVID-19 disease, it requires a prompt diagnosis and meticulous monitoring, as it can be an aggravating factor of the patient's prognosis.

## References

1. The World Health Organization, Coronavirus disease 2019 (COVID-19) pandemic. <https://www.who.int/emergencies/diseases/novel-coronavirus-2019>. (Accessed 3 May 2020).
2. Li H, Liu S-M, Yu X-H, et al. Coronavirus disease 2019 (COVID-19): current status and future perspective. *Int J Antimicrob Agents*. 2020;55:3105951.
3. Chen N, Zhou M, Dong X, et al. Epidemiological and clinical characteristics of 99 cases of 2019 novel coronavirus pneumonia in Wuhan, China: a descriptive study. *Lancet*. 2020;395(10223):507-513.
4. Xu XI, Yu C, Qu J, et al. Imaging and clinical features of patients with 2019 novel coronavirus SARS-CoV-2. *Eur J Nucl Med Mol Imaging*. 2020;47:1-6.
5. Macia I, Moya J, Ramos R, et al. Spontaneous pneumomediastinum: 41 cases. *Eur J Cardiothorac Surg*. 2007;31:1110-4.
6. Kolani S, Houari N, Haloua M, et al. Spontaneous pneumomediastinum occurring in the SARS-COV-2 infection. *IDCases*. 2020;21:e00806.
7. Chekkoth SM, Supreeth RN, Valsala N, et al. Spontaneous pneumomediastinum in H1N1 infection: uncommon complication of a common infection. *JR Coll Physicians Edinb*. 2019;49(4):298-300.
8. Padhy AK, Gupta A, Aiyer P, et al. Spontaneous pneumomediastinum: a complication of swine flu. *Asian Cardiovasc Thorac Ann*. 2015;23(8):998-1000.
9. She WH, Chok KSH, Li IWS, et al. Pneumocystis jirovecii-related spontaneous pneumothorax, pneumomediastinum and subcutaneous emphysema in a liver transplant recipient: a case report. *BMC Infect Dis*. 2019;19(1):66.
10. Manna S, Wruble J, Maron SZ, et al. COVID-19: a multimodality review of radiologic techniques, clinical utility and imaging features. *Radiology: Cardiothoracic Imaging*. 2020;2(3):e200210.
11. Becker RC, et al. COVID-19 update: Covid-19-associated coagulopathy. *J Thromb Thrombolysis*. 2020;50(1):54-67.
12. Channappanavar R, Perlman S, et al. Pathogenic human coronavirus infections: causes and consequences of cytokine storm and immunopathology. *Semin Immunopathol*. 2017;39(5):529-539.
13. Macklin MT, Macklin CC, et al. Malignant interstitial emphysema of the lungs and mediastinum as an important occult complication in many respiratory diseases and other conditions: interpretation of the clinical literature in the light of laboratory experiment. *Medicine*. 1944;23:281-358.
14. Maunder RJ, Pierson DJ, Hudson LD, et al. Subcutaneous and mediastinal emphysema: pathophysiology, diagnosis and management. *Arch Intern Med*. 1984;144:1447-1453.
15. Sztrymf B, Messika J, Bertrand F, et al. Beneficial effects of humidified high flow nasal oxygen in critical care patients: a prospective pilot study. *Intensive Care Med*. 2011;37:1780-1786.

16. Sonobe S, Inoue S, Nishiwada T, et al. A case of subcutaneous emphysema/mediastinal emphysema during the use of humidified high-flow nasal cannula. *JA Clinical Reports*. 2019;5:85.
17. Wali A, Rizzo V, Bille A, et al. Pneumomediastinum following intubation in COVID-19 patients: a case series. *Anaesthesia*. 2020;75(8):1076-1081.
18. Gorospe L, Ayala-Carbonero A, et al. Pneumomediastino espontáneo en pacientes con COVID-19: una serie de cuatro casos. *Arch Bronconeumol*. 2020;56:754-756.
19. Perna V, Vila E, Guelbenzu JJ, et al. Pneumomediastinum: is this really a benign entity? When it can be considered as spontaneous? Our experience in 47 adult patients. *Eur J Cardiothorac Surg*. 2010;37(3):573-5.
20. Chu CM, Leung YY, Hui JY, et al. Spontaneous pneumomediastinum in patients with severe acute respiratory syndrome. *Eur Respir J*. 2004;23(6):802-4.