

**Published:** May 31, 2022

**Citation:** Panagopoulos D, Strantzalis G, et al., 2022. The Entity of Chiari Malformation: Literature Overview and Presentation of the 50 Most Cited Relevant Papers, Medical Research Archives, [online] 10(4).

<https://doi.org/10.18103/mra.v10i5.2811>

**Copyright:** © 2022 European Society of Medicine. This is an open-access article distributed under the terms of the Creative Commons Attribution License, which permits unrestricted use, distribution, and reproduction in any medium, provided the original author and source are credited.

**DOI:**  
<https://doi.org/10.18103/mra.v10i5.2811>

**ISSN:** 2375-1924

## REVIEW ARTICLE

# The Entity of Chiari Malformation: Literature Overview and Presentation of the 50 Most Cited Relevant Papers.

**Dimitrios Panagopoulos<sup>1</sup>, Georgios Strantzalis<sup>1</sup>, Maro Gavra<sup>1</sup>, Efstathios Boviatis<sup>1</sup>, Stefanos Korfias<sup>1</sup>, Ploutarchos Karydakis<sup>1</sup>**

<sup>1</sup>Consultant Pediatric Neurosurgeon, Neurosurgical Department, Pediatric Hospital of Athens, Agia

\*[dimpanayop@gmail.com](mailto:dimpanayop@gmail.com)

## ABSTRACT

Chiari malformations comprise a group of disorders, which share in common inherent anatomical abnormalities that involve the region of the brain stem and cerebellum, eventually coexisting with entities such as hydrocephalus, spina bifida, syringomyelia and tethered cord syndrome. In the mean-time, from the original description of this syndrome, several researchers have focused on an effort to elucidate the pathogenesis of Chiari malformation from a point of view that it is a primary neural anomaly.

The aim of the current review is to investigate the time course of our knowledge regarding Chiari malformation, which has expanded significantly in the past decades. As new insight has occurred regarding the pathophysiology and natural history of Chiari I malformation (CIM), in association with the widespread availability of MRI, the treatment modalities and algorithm for this patient population has been substantially evolved. Our purpose is to present a review of CIM and its most significant associated comorbidities, comment on techniques for surgical intervention and their expected outcomes.

There is a bulk of literature reviews centered on Chiari malformations; in this context, we attempted a literature review, including a discussion centered on the historical background, anatomical forms, pathophysiology, clinical presentation, relationships with other diseases and diagnostic procedures for these abnormalities. Moreover, a bibliographic search was performed, using Thomson Reuters web of Science and Pubmed databases, in order to identify the most noteworthy papers about Chiari Syndrome. The following parameters were recorded: article titles, number of total citations and citations per year, authors' names, authors' h-index, institution and country where the research took place, year of publication, the journal of publication and journal's impact factor. In addition, we reviewed the journals' Impact Factor and SCImago Journal Rank (SJR). To obtain all those parameters, besides Web of sciences, we utilized Scopus, SCImago Journal and Country rankings, and In Cites Journal Citation Reports.

Our search resulted in 9,972 articles, published from 1855 until now (March 2022). All articles are in English. The 50 most cited papers are presented in Table S1. All of them combined have been cited 8,999 times, in 3,262 different articles, with an average citation per item of 179.98.

We have attempted to present a thorough overview of this group of disorders, as well as to trace the evolution of our knowledge regarding the anatomical abnormalities associated with this condition, imaging and treatment gold standards and future perspectives.

The real pathophysiology, embryological background and natural history of CM have still not been entirely elucidated. This is in concordance with the fact that new suggestions have been submitted for the management of this malformation and more sophisticated imaging techniques have been introduced, in order to investigate in more details, the diagnosis. However, a lot of controversies remain, mainly centered on the optimum strategy which should be selected for selection of the appropriate surgical candidates and most efficacious treatment protocols, in order to obtain efficient decompression of the cranio-cervical junction.

**Keywords:** Analysis, Articles, Bibliometric, Citation, Chiari malformation, syringomyelia, duraplasty, suboccipital decompression

## Abbreviations

CY: Citation per year

CM: Chiari Malformations

MRI: Magnetic Resonance Imaging

ICP: Intracranial Pressure

CSF: Cerebrospinal Fluid

CM 0: Chiari Malformation 0

CM: Chiari I Malformation

CM1: Chiari Malformation 1

CM1.5: Chiari Malformation 1.5

CM3.5: Chiari Malformation 3.5

CMIII: Chiari Malformation 3

## Introduction

### Definition of Chiari malformations

Chiari malformation comprises a heterogeneous group of pathological entities which are attributed, as a whole, to inherent anatomical abnormalities in the territory of the brainstem and cerebellum. In the early 1890s, Professor Hans Chiari (1851–1916), an anatomopathologist at the German University in Prague, Czechoslovakia, was the first to present this spectrum of congenital disorders, that were subsequently unified under the term Chiari malformation types I–IV<sup>1-4</sup>. Moreover, it is common belief that he has laid the foundations of our contemporary data regarding this malformation. These pathological entities share in common a constellation of characteristics, including downward displacement or elongation of the cerebellar tonsils and even of the vermis into the cervical spinal dural sac, eventually associated with hydrocephalus. Syringomyelia, spina bifida, hydromyelia, kyphosis, scoliosis and tethered cord syndrome are considered to be a group of pathological features that, most commonly, in total or in isolation, are associated with CM.

### Scope of manuscript

In this paper, we attempt a review of the literature centered on the historical background, anatomical forms, pathophysiology, clinical presentation, relationships to other diseases and diagnostic procedures for these abnormalities. We would like to specify that this manuscript is concentrated on Chiari in children's patients. The main aim of this manuscript is to summarize our current knowledge regarding the entity of Chiari malformation, including its categorization, relevant comorbidities, offending embryo-pathologic abnormalities and pathobiologic mechanisms, relevant diagnostic modalities and treatment algorithms. We attempt a historical overview

through the most cited relevant papers, aiming at elucidating the effect of dominating pathogenetic theories on the determination of the most appropriate treatment protocols, over the years. Additionally, the contribution of modern versus more compatible imaging modalities in the determination of the operation protocol, the appropriate selection of patients most likely to respond to surgical therapy, the timing of surgery as well as the postoperative follow up, needs to be overviewed and summarized. Additionally, a relevant bibliographic review was executed, based on Thomson Reuters web of Science and Pubmed databases, aiming toward the identification and notification of the 50 most noteworthy papers about Chiari Syndrome.

## Materials and Methods

### Search Strategy

We performed a search on March 2022, using Thomson Reuters web of Science and Pubmed databases to identify the most noteworthy papers about Chiari Syndrome. We used the key words: "Chiari Syndrome", "Chiari Malformation", "Arnold-Chiari". Afterwards, we review the results in order to clarify that they were relevant to the purposes of our research. The 50 most cited papers, based on Web of Knowledge statistics were chosen and further analyzed. In addition, recent articles were reviewed in order to discuss the most trending aspects of this challenging syndrome.

### Data

Our search resulted in 9.972 articles, published from 1855 until now (March 2022). All articles are in English. The 50 most cited papers are presented in Table S1. All of them combined have been cited 8.999 times, in 3.262 different articles, with an average citation per item of 179.98.

**Table S1**

ArticleTitle	Authors	SourceTitle	Publication Year	TimesCited
Chiari I Malformation Redefined: Clinical And Radiographic Findings For 364 Symptomatic Patients <sup>(5)</sup>	Milhorat, TH; Chou, MW; Trinidad, EM; Kula, RW; Mandell, M; Wolpert, C; Speer, MC	NEUROSURGERY	1999	777
Pathophysiology Of Syringomyelia Associated With Chiari I Malformation Of The Cerebellar Tonsils - Implications For Diagnosis And Treatment <sup>(17)</sup>	Oldfield, Eh; Muraszko, K; Shawker, Th; Patronas, Nj	JOURNAL OF NEUROSURGERY	1994	571
Pathogenesis Of Chiari Malformation: A Morphometric Study Of The Posterior Cranial Fossa <sup>(13)</sup>	Nishikawa, M; Sakamoto, H; Hakuba, A; Nakanishi, N; Inoue, Y	JOURNAL OF NEUROSURGERY	1997	400
Asymptomatic Chiari Type I Malformations Identified On Magnetic Resonance Imaging <sup>(38)</sup>	Meadows, J; Kraut, M; Guarnieri, M; Haroun, R; Carson, BS	JOURNAL OF NEUROSURGERY	2000	337
Symptomatic Chiari Malformations - An Analysis Of Presentation, Management, And Long-Term Outcome <sup>(29)</sup>	Dyste, Gn; Menezes, Ah; Vangilder, Jc	JOURNAL OF NEUROSURGERY	1989	324
Chiari-I Malformations - Clinical And Radiologic Reappraisal	Elster, Ad; Chen, Mym	RADIOLOGY	1992	312
The Cause Of Chiari-Ii Malformation - A Unified Theory <sup>(11)</sup>	Mclone, Dg; Knepper, Pa	PEDIATRIC NEUROSCIENCE	1989	288
Arnold-Chiari Malformation - Review Of 71 Cases	Paul, Ks; Lye, Rh; Strang, Fa; Dutton, J	JOURNAL OF NEUROSURGERY	1983	273
Morphogenesis Of Experimentally Induced Arnold-Chiari Malformation	Marinpadilla, M; Marinpadilla, Tm	JOURNAL OF THE NEUROLOGICAL SCIENCES	1981	263
Position Of Cerebellar Tonsils In The Normal Population And In Patients With Chiari Malformation - A Quantitative Approach With Mrlmaging <sup>(32)</sup>	Aboulezz, Ao; Sartor, K; Geyer, Ca; Gado, Mh	JOURNAL OF COMPUTER ASSISTED TOMOGRAPHY	1985	233
Chiari Malformation Presenting In Adults - A Surgical Experience In 127 Cases <sup>(26)</sup>	Levy, Wj; Mason, L; Hahn, Jf	NEUROSURGERY	1983	227
Surgical Experience In 130 Pediatric Patients With Chiari I Malformations <sup>(45)</sup>	Tubbs, RS; Mcgirt, MJ; Oakes, WJ	JOURNAL OF NEUROSURGERY	2003	224
Posterior-Fossa Volume And Response To Suboccipital Decompression In Patients With Chiari-I Malformation	Badie, B; Mendoza, D; Batzdorf, U	NEUROSURGERY	1995	208
Effects Of Posterior Fossa Decompression With And Without Duraplasty On Chiari Malformation-Associated Hydromyelia	Munshi, I; Frim, D; Stine-Reyes, R; Weir, BKA; Hekmatpanah, J; Brown, F	NEUROSURGERY	2000	195
Symptomatic Chiari Malformation In Adults - A New Classification Based On Magnetic-Resonance-Imaging With Clinical And Prognostic-Significance	Pillay, Pk; Awad, Ia; Little, Jr; Hahn, Jf	NEUROSURGERY	1991	184
Experience With Arnold-Chiari Malformation, 1960 To 1970	Saez, Rj; Onofrio, Bm; Yanagihara, T	JOURNAL OF NEUROSURGERY	1976	183

Central-Nervous-System Anomalies Associated With Meningocele, Hydrocephalus, And The Arnold-Chiari Malformation - Reappraisal O Theories Regarding The Pathogenesis Of Posterior Neural-Tube Closure Defects	Gilbert, Jn; Jones, Kl; Rorke, Lb; Chernoff, Gf; James, He	NEUROSURGERY	1986	180
Chiari-I Malformation With Syringomyelia - Evaluation Of Surgical Therapy By Magnetic-Resonance Imaging	Batzdorf, U	JOURNAL OF NEUROSURGERY	1988	177
Posterior Cranial Fossa Dimensions In The Chiari-I Malformation - Relation To Pathogenesis And Clinical Presentation	Stovner, Lj; Bergan, U; Nilsen, G; Sjaastad, O	NEURORADIOLOGY	1993	168
Institutional Experience With 500 Cases Of Surgically Treated Pediatric Chiari Malformation Type I Clinical Article <sup>(75)</sup>	Tubbs, RS; Beckman, J; Naftel, RP; Chern, JJ; Wellons, JC; Rozzelle, CJ; Blount, JP; Oakes, WJ	JOURNAL OF NEUROSURGERY-PEDIATRICS	2011	168
Comparison Of Posterior Fossa Decompression With And Without Duraplasty For The Surgical Treatment Of Chiari Malformation Type I In Pediatric Patients: A Meta-Analysis <sup>(76)</sup>	Durham, SR; Fjeld-Olinec, K	JOURNAL OF NEUROSURGERY-PEDIATRICS	2008	152
Quantitative Cine-Mode Magnetic-Resonance-Imaging Of Chiari-I Malformations - An Analysis Of Cerebrospinal-Fluid Dynamics	Armonda, Ra; Citrin, Cm; Foley, Kt; Ellenbogen, Rg	NEUROSURGERY	1994	151
Considerations In The Diagnosis And Treatment Of Syringomyelia And The Chiari Malformation	Cahan, Ld; Bentson, Jr	JOURNAL OF NEUROSURGERY	1982	144
Chiari-I Malformation - An Acquired Disorder	Welch, K; Shillito, J; Strand, R; Fischer, Eg; Winston, Kr	JOURNAL OF NEUROSURGERY	1981	143
Surgical Indication And Results Of Foramen Magnum Decompression Versus Syringosubarachnoid Shunting For Syringomyelia Associated With Chiari-I Malformation	Hida, K; Iwasaki, Y; Koyanagi, I; Sawamura, Y; Abe, H	NEUROSURGERY	1995	143
Surgical Results Of Posterior Fossa Decompression For Patients With Chiari I Malformation	Navarro, R; Olavarria, G; Seshadri, R; Gonzales-Portillo, G; Mclone, DG; Tomita, T	CHILDS NERVOUS SYSTEM	2004	139
International Survey On The Management Of Chiari I Malformation And Syringomyelia	Schijman, E; Steinbok, P	CHILDS NERVOUS SYSTEM	2004	139
ChiariMalformation In Craniosynostosis	Cinalli, G; Spennato, P; Sainte-Rose, C; Arnaud, E; Aliberti, F; Brunelle, F; Cianciulli, E; Renier, D	CHILDS NERVOUS SYSTEM	2005	139
Chiari Type I Malformation In A Pediatric Population	Aitken, LA; Lindan, CE; Sidney, S; Gupta, N; Barkovich, AJ; Sorel, M; Wu, YW	PEDIATRIC NEUROLOGY	2009	137

Posterior-Fossa Reconstruction - A Surgical Technique For The Treatment Of Chiari-I Malformation And Chiari-I-Syringomyelia Complex - Preliminary-Results And Magnetic-Resonance-Imaging Quantitative Assessment Of Hindbrain Migration	Sahuquillo, J; Rubio, E; Poca, Ma; Rovira, A; Rodriguezbaeza, A; Cervera, C	NEUROSURGERY	1994	133
Mechanisms Of Cerebellar Tonsil Herniation In Patients With Chiari Malformations As Guide To Clinical Management	Milhorat, TH; Nishikawa, M; Kula, RW; Dlugacz, YD	ACTA NEUROCHIRURGICA	2010	132
The Natural History Of The Chiari Type I Anomaly <sup>(85)</sup>	Novegno, F; Caldarelli, M; Massa, A; Chieffo, D; Massimi, L; Pettorini, B; Tamburrini, G; Di Rocco, C	JOURNAL OF NEUROSURGERY-PEDIATRICS	2008	130
The Surgical Treatment Of Chiari I Malformation	Klekamp, J; Batzdorf, U; Samii, M; Bothe, HW	ACTA NEUROCHIRURGICA	1996	130
The Chiari II Malformation: Cause And Impact	Mclone, DG; Dias, MS	CHILDS NERVOUS SYSTEM	2003	130
Foramen Magnum Decompression With Removal Of The Outer Layer Of The Dura As Treatment For Syringomyelia Occurring With Chiari-I Malformation	Isu, T; Sasaki, H; Takamura, H; Kobayashi, N; Batzdorf, U; Milhorat, Th	NEUROSURGERY	1993	128
Basichondrocranium Anomalies In Adult Chiari Type-I Malformation - A Morphometric Study <sup>(15)</sup>	Vega, A; Quintana, F; Berciano, J	JOURNAL OF THE NEUROLOGICAL SCIENCES	1990	127
Chiari-I Malformation - Classification And Management	Bindal, Ak; Dunsker, Sb; Tew, Jm	NEUROSURGERY	1995	125
Primary Craniovertebral Anomalies And The Hindbrain Herniation Syndrome (Chiari): Data Base Analysis	Menezes, AH	PEDIATRIC NEUROSURGERY	1995	124
Chiari I Malformation Associated With Syringomyelia And Scoliosis - A Twenty-Year Review Of Surgical And Nonsurgical Treatment In A Pediatric Population	Eule, JM; Erickson, MA; O'Brien, MF; Handler, M	SPINE	2002	123
Acquired Chiari Malformations - Incidence, Diagnosis, And Management	Payner, Td; Prenger, E; Berger, Ts; Crone, Kr	NEUROSURGERY	1994	120
Is Atlantoaxial Instability The Cause Of Chiari Malformation? Outcome Analysis Of 65 Patients Treated By Atlantoaxial Fixation <sup>(46)</sup>	Goel, A	JOURNAL OF NEUROSURGERY-SPINE	2015	117
Analysis Of The Posterior Fossa In Children With The Chiari 0 Malformation <sup>(52)</sup>	Tubbs, RS; Elton, S; Grabb, P; Dockery, SE; Bartolucci, AA; Oakes, WJ	NEUROSURGERY	2001	110
Syndrome Of Occipito-atlantoaxial Hypermobility, Cranial Settling, And Chiari Malformation Type I In Patients With Hereditary Disorders Of Connective Tissue	Milhorat, TH; Bolognese, PA; Nishikawa, M; McDonnell, NB; Francomano, CA	JOURNAL OF NEUROSURGERY-SPINE	2007	110

Experience With Surgical Decompression Of The Arnold-Chiari Malformation In Young Infants With Myelomeningocele	Park, Ts; Hoffman, Hj; Hendrick, Eb; Humphreys, Rp	NEUROSURGERY	1983	108
The Role Of Limited Posterior Fossa Craniectomy In The Surgical Treatment Of Chiari Malformation Type I: Experience With A Pediatric Series <sup>(77)</sup>	Caldarelli, M; Novegno, F; Massimi, L; Romani, R; Tamburrini, G; Di Rocco, C	JOURNAL OF NEUROSURGERY	2007	108
The Incidence OfCraniocervical Bony Anomalies In The Adult Chiari Malformation	Schady, W; Metcalfe, Ra; Butler, P	JOURNAL OF THE NEUROLOGICAL SCIENCES	1987	106
Ventral Brain Stem Compression In Pediatric And Young Adult Patients With Chiari I Malformations <sup>(39)</sup>	Grabb, PA; Mapstone, TB; Oakes, WJ	NEUROSURGERY	1999	106
Phase-Contrast MR Imaging Of The Cervical CSF And Spinal Cord: Volumetric Motion Analysis In Patients With Chiari I Malformation	Hofmann, E; Warmuth-Metz, M; Bendszus, M; Solymosi, L	AMERICAN JOURNAL OF NEURORADIOLOGY	2000	106
Syringomyelia Associated With Type I Chiari Malformation A 21-Year Retrospective Study On 75 Cases Treated By Foramen Magnum Decompression With A Special Emphasis On The Value Of Tonsils Resection	Guyotat, J; Bret, P; Jouanneau, E; Ricci, AC; Lapras, C	ACTA NEUROCHIRURGICA	1998	105

The most cited article was published by Milhorat, TH, et al. in 1999<sup>5</sup>. The paper has received 777 citations, with an average 70.63 citations per year, while the last in our list was published by Guyotat, J, et al, in 1998, with 105 total citations, and an average of 2 citations per year. It was centered on the clinical and radiographic findings (MRI, cine MRI) of symptomatic Chiari patients. They summarized the clinical findings which constitute the malformation, as well as the relevant neuroimaging features, namely MRI and cine-MRI imaging characteristics, along with volumetric calculations of the posterior cranial fossa, which revealed a significant reduction of its total volume. Their survey's data supported the existing, growing evidence that CM type I is a disorder of the para-axial mesoderm, characterized by underdevelopment of the posterior

cranial fossa and overcrowding of the normally developed hindbrain. Another important notification with clinical application is that tonsillar herniation of less than 5 mm does not exclude the diagnosis. They also emphasized on the fact that clinical manifestations of CMI should be related to cerebrospinal fluid disturbances and direct compression of nervous tissue, in order to establish the diagnosis of Chiari I malformation.

### Results

Additionally, we attempted to perform another categorization of the most cited articles, and we rearranged our list based on CY. (Table S2).

**Table S2.**

ArticleTitle	Authors	TimesCited	Average per Year
Chiari I Malformation Redefined: Clinical And Radiographic Findings For 364 Symptomatic Patients <sup>(5)</sup>	Milhorat, Th	777	37
Is Atlantoaxial Instability The Cause Of Chiari Malformation? Outcome Analysis Of 65 Patients Treated By Atlantoaxial Fixation <sup>(43)</sup>	Goel, A	117	23.4
Pathophysiology Of Syringomyelia Associated With Chiari I Malformation Of The Cerebellar Tonsils - Implications For Diagnosis And Treatment <sup>(16)</sup>	Oldfield, Eh	571	21.96

Pathogenesis Of Chiari Malformation: A Morphometric Study Of The Posterior Cranial Fossa <sup>(12)</sup>	Nishikawa, M	400	17.39
Asymptomatic Chiari Type I Malformations Identified On Magnetic Resonance Imaging <sup>(35)</sup>	Meadows, J	337	16.85
Surgical Experience In 130 Pediatric Patients With Chiari I Malformations <sup>(42)</sup>	Tubbs, RS	224	13.17
Mechanisms Of Cerebellar Tonsil Herniation In Patients With Chiari Malformations As Guide To Clinical Management	Milhorat, Th	132	13.2
Comparison Of Posterior Fossa Decompression With And Without Duraplasty For The Surgical Treatment Of Chiari Malformation Type I In Pediatric Patients: A Meta-Analysis <sup>(72)</sup>	Durham, Sr	152	12.66
Chiari Type I Malformation In A Pediatric Population	Aitken, La	137	12.45
Chiari-I Malformations - Clinical And Radiologic Reappraisal	Elster, Ad	312	11.14

More specifically, in order to calculate the CY, we divided the number of received citations for a given article by the number of years since its publication. Although the number of citations relevant to a specific article is currently considered to be an objective and reproducible method in order to standardize and ascertain quantifying the quality of any given article, there exists a widely recognized review bias toward accumulated citations for older studies. Individually, this could be considered as an independent factor, providing an inaccurate reflection of the articles' impacts; as this limitation is considered, we addressed this by using CY.

The 50 papers of our list originate from 12 different countries. More specific, 34 out of the 50 papers have been published in the USA, followed by Italy with 3 publications. A list of the countries with more than 3 records in our list is shown in table S3.

**Table S3**

Countries/Regions	Records
USA	34
ITALY	3
JAPAN	3

These high-impact articles have been published in 15 different Journals. "Neurosurgery" is the one with the most publications. Journals with more than 3 publications are shown in table S4.

**Table S4**

Journals	Records
NEUROSURGERY	15
JOURNAL OF NEUROSURGERY	11
CHILDS NERVOUS SYSTEM	5
ACTA NEUROCHIRURGICA	3
JOURNAL OF NEUROSURGERY PEDIATRICS	3
JOURNAL OF THE NEUROLOGICAL SCIENCES	3

## Discussion

### Historical considerations

In 1883, Cleland was the first author to notify an entity which was widely reported later and described under the term of Chiari malformation type II or Arnold–Chiari malformation. His original report was referring on a single infant with myelomeningocele and hindbrain abnormalities<sup>6</sup>. In 1891, Chiari described his own experience, which was based on the collation and subsequent analysis of his relevant data, coming from over 40 postmortem inspections of hindbrain malformations<sup>3</sup> and described CM types I, II, and III<sup>7</sup>. In 1894, Arnold reported a case of a child with elongation and descent of the inferior part of the cerebellum into the spinal canal and spina bifida<sup>7</sup>. After that, the entity of type IV malformation was established with another publication of Chiari in 1895<sup>4</sup>, who supported the concept that "other factors must play a role in this condition"—more specifically, insufficient skull growth, which was implicated by increased ICP—in

contradistinction to his previous report, in which he supported that CM was a secondary sequelae of hydrocephalus.

Milhorat<sup>5</sup> et al examined a prospective cohort of 364 symptomatic patients, all of whom underwent MRI of the head and spine; a smaller subgroup was investigated via CINE-MRI. They also calculated for another portion of patients and for age- and gender-matched control subjects, the volumetric characteristics of their posterior cranial fossa. Authors calculated the mean age of onset for the patients, as well as any commonly associated comorbidities. These mainly included syringomyelia, scoliosis and basilar invagination. Additionally, the main characteristics of the clinical syndrome associated with CM I were described with clarity, and the most consistent MRI findings were reviewed. According to their survey, their data were in concordance with existing evidence which support the fact that CMI is a disorder of the para-axial mesoderm, which includes an underdevelopment of the posterior cranial fossa with resultant overcrowding of the normally developed hindbrain structures. They also suggested that the existence of tonsillar herniation that does not exceed 5 mm could not be considered as a safe criterion that precludes that diagnosis. Regarding the etiology of the clinical signs and symptoms associated with CMI, they concluded that they could be related to cerebrospinal fluid flow disturbances, along with direct compression of neural elements.

A recently published retrospective analysis<sup>8</sup> was mainly focused on the natural history of Chiari I malformation in children and not on the surgical indications, technique, and outcomes, which are mainly analyzed in the literature. This study concluded that the natural history of asymptomatic CM I is relatively benign. This means that the subgroup of patients that were managed conservatively are not prone to clinical and neurological deterioration. There is a small subgroup which can exhibit signs of clinical progression, which are expected to come back to clinical attention within 2 years of initial consultation. To the best of their knowledge, they were unable to recognize any specific factors that were capable to predict the development of any new symptomatology or the worsening of the clinical status of these patients over time.

### Background and Pathophysiology

These four traditional subdivisions are believed to be the final outcome related to the involvement of rhombencephalic derivatives in a pathophysiologic process which is characterized by various degrees of severity of expression. The first three types (I-III) share as a common feature a progressively more severe degree of herniation of the aforementioned structures below the lower

boundary of the posterior fossa, namely the foramen magnum. Moreover, another common feature implicated in their pathogenetic cascade, is related to the paucity of unobstructed flow of CSF out of the normal outlet foramina of the fourth ventricle. Pathological differentiation which is recorded between Chiari I and II malformations are thought to be etiologically related to the differential time schedule related to the generation of the vector of force in the anatomic vicinity of the foramen magnum.

Even though the vast majority of reported cases of Chiari malformations are categorized under the term of congenital anomalies, acquired type I Chiari malformations have repeatedly been described but are not under consideration in this manuscript. These refer to cases who display downward displacement of the cerebellar tonsils as a result of pathology centered on the posterior fossa. Although these patients share in common their imaging characteristics to those harboring original Chiari I, the offending underlying pathology is discretely different.

Although the different types of Chiari malformations involve anatomical structures localized in the same anatomic territory and in close vicinity of one another, the patho-embryological origins of each relevant subtype seem to be distinct. It is essential to attempt a historical overview of the dominant pathobiological theories which are targeting to subserve a unified concept which could describe the characteristics of the first two subtypes of Chiari malformations. This is helpful in order to understand the anatomical substrate, which could enhance our effort in order to explain the other associated brain and spinal cord malformations, as well as the background behind the different therapeutic strategies.

With his initial description, Chiari proposed that hindbrain hernias are the end result of pre-existing hydrocephalus, and that the different, and evolving, degrees of severity of Chiari malformations are the net reflection of the degrees of expression of that same mechanism.

Since then, the recognition of the entity of acquired Chiari malformations, along with the verification of dynamic shifts via the utilization of cine-mode MRI, suggest that these malformations could not be considered as merely fixed dysraphic lesions, but rather represent dynamic entities, exhibiting the potential to evolve with time. Chiari believed that the first three types of malformations resulted directly and exclusively from chronic hydrocephalus, stating at his original article that he had never seen a hindbrain hernia not been associated with hydrocephalus. He also assumed that chronic hydrocephalus could be responsible for the abnormal development of the cerebellum, thus resulting in its herniation through the foramen magnum.



There are several elements that argue against the universal acceptance of this theory, as it is insufficient to explain all the abnormalities that coexist in the context of this malformation. The recognition of Chiari malformations without hydrocephalus, the coexistence of anomalies as myelomeningoceles and split cord malformations that could not be pathologically attributed to this concept, as well as the upward herniation of posterior fossa structures through the tentorial notch into the supratentorial compartment, representing one of the most significant components of Chiari II malformation, are not consistent with Chiari theory. Because of that, newer theories about the pathogenesis of Chiari have emerged, including the hindbrain dysgenesis and developmental arrest theory, the caudal traction theory, the hydrocephalic and hydrodynamic theory of Gardner in the 1950s and early 1960s<sup>9</sup>, its later modification by Williams<sup>10</sup>, the small posterior fossa/hindbrain overgrowth theory, and the lack of embryological ventricular distention theory or 'unified theory' of McLone and Knepper<sup>11</sup>. A recent comprehensive review focused on the embryology and pathophysiology of Chiari I and II malformations is available<sup>12</sup>.

So far, we presented investigations which were focused on explaining the pathogenesis of Chiari malformation from the standpoint of primary neural tissue anomaly. Another group of researchers, based on morphometric studies focusing on the bony part of the posterior cranial fossa in adult patients with Chiari malformation<sup>13</sup> introduced the concept that the primary small and shallow posterior cranial fossa could be attributed to an underdevelopment of the occipital bone<sup>14,15</sup>. They concluded that adult type Chiari malformation could be causally related to underdevelopment of the occipital enchondrium, which could be the end result of underdevelopment of the occipital somite originating from the paraxial mesoderm<sup>16</sup>. Regarding the pathophysiology of Chiari malformations, there is a matter that is not fully elucidated and is related to our inability to correlate the severity of the symptomatology that is due to medullary dysfunction in patients who appear to have a minimum degree of tonsillar herniation. There have been reports of patients, mainly toddlers and infants, who came to medical attention due to central sleep apnea and aspiration and these findings were not matched with traditional radiographic criteria of Chiari. When MRI of these patients were reviewed, ventrolateral wrapping of the tonsils was mentioned. A novel concept was developed, based on the assumption that this abnormality could be considered the explanation of these defects, despite the absence of downward herniation. These authors<sup>68</sup> claim that their findings indicate a newly recognized subgroup of patients harboring a condition which they defined as

Chiari type 0.5 malformation. Their suspicion is supported by the existence of a strong relationship between different patterns in presentation and treatment options, with the identification (or not) of ventral herniation. According to them, this pathology is intimately associated with a novel entity which is considered under the general classification of the Chiari malformation. It seems that all the subgroups incorporated under the general term of Chiari malformation, which harbor unique anatomic and imaging characteristics, symptomatology, and even surgical treatment protocols, should be considered to represent a constellation of malformations that are related with a wide array of clinical presentations.

### **Comorbidity associated with Chiari malformations**

Another peculiar feature, inherently associated with Chiari malformation, is its association with syringomyelia: there are a lot of reviews that are dedicated to this comorbidity<sup>17-19</sup>. The prevalence of syringomyelia in patients with Chiari malformation varies, ranging between 69% in adults and 40% in children<sup>20</sup>. Previous investigations, aimed at elucidating the etiology of Chiari-related syringomyelia, were focused on the assumption of a communication of the syrinx cavity with the fourth ventricle, which led to the concept of "communicating syringomyelia." Based on that, Gardner's operative procedure was developed, who placed a tissue plug at the most inferior point of the fourth ventricle<sup>21</sup>. The favorable outcome of this procedure in a subgroup of patients could be the result of the posterior fossa bony and intradural exposure, instead of the net effect of the "obex plug".

It is well known that the entity of Chiari malformation is associated with a variety of pathological conditions and symptoms, which constitute a wide spectrum of disabilities and comorbidities<sup>22</sup>. These patients can come to clinical attention because of an associated craniovertebral instability, syringomyelia, as well as hydrocephalus, or other causes<sup>22,23</sup>. It has been argued that a proportion of 25% of CM1 patients could suffer from syringomyelia, that is a cystic fluid collection within the substance of the spinal cord. The ultimate adverse effect that could be attributed to its presence consists of the establishment of motor and sensory deficits of the upper and lower extremities, along with urinary incontinence. It can be established in a significant proportion of patients (~75%) suffering from CM I and are undergoing surgical management. This is the reason that decompressive surgery is performed to these patients, as is the only method that can reverse or reduce the ongoing spinal cord compression<sup>24</sup>.

As far as the comorbidities of Chiari malformations are been considered, special attention should be considered

regarding the development of scoliosis. Current literature reports that a subpopulation in the order of 20% of CM I patients suffer from scoliosis, a percentage that can be increased in the order of 60%, in case syringomyelia is concurrently present<sup>25</sup>. Another study was based on MRI investigations in order to examine the co-existence of associated abnormalities in patients suffering from CMI. It concluded that approximately 25% of these patients were harboring a syrinx in the spinal cord and in 35%, Klippel-Feil or platybasia were recorded, in the context of incidental radiographic findings<sup>24</sup>. Apart from that evidence, another publication exists that it mentions more than 50 disorders associated with CM1<sup>26</sup>, a finding that could be attributed to significant genetic heterogeneity.

A recent survey<sup>27</sup> evaluated a large group of patients with an incidentally discovered Chiari malformation and stated that most patients should not be considered as surgical candidates, especially in the absence of syringomyelia. Nevertheless, there is a subgroup of affected individuals who are prone to the development of a de novo syrinx or neurological signs. These could be of new onset or progressive during subsequent follow-up, a fact which deserves evaluation by neuroimaging of the entire neuroaxis. Although the presence of syringomyelia was associated with need for an emergent surgical intervention, our plan for the rest of these patients is not so straightforward. More precisely, the absence of syringomyelia argues against surgical intervention but this is not always the case. Indeed, surgical intervention may be delayed up to several years after initial presentation and long-term clinical follow-up is recommended. Another relevant review article is available<sup>28</sup>.

### Imaging

Autopsy specimens<sup>29</sup> verified the paucity of communication between the fourth ventricle and the syrinx cavity in most cases of Chiari-related syringomyelia, an observation that was certified and validated with the widespread availability of MRI. Based on that assumption, a more integrated explanation is that proposed by Oldfield and colleagues<sup>17</sup>, who supposed that the pulsatile movement of the cerebellar tonsils, as it is continuously acting in the context of an enclosed spinal subarachnoid space, extrudes fluid into the cord parenchyma. Stoodley's research was centered on the role of arterial pulsations in the spinal subarachnoid space, as a considerable and independent contributor, to the trans-parenchymal propagation of CSF<sup>30,31</sup>.

Another aspect of Chiari malformation that deserves special mention is its association with atlantoaxial subluxation, which varies from 26 to 38% in relevant literature<sup>5,32-36</sup>. These children may or not have an

associated syrinx and there is assuredness that CSF circulation is impeded by the hindbrain herniation, along with the anteriorly directed compression, caused by the atlanto-axial dislocation.

An important aspect of the management of Chiari malformations is related to the diagnostic evaluation of these cases. After the advent of MRI, this modality has become the gold standard for diagnosis of syringomyelia and CM. In 1985, Aboulezz et al. used MRI to certify that the tonsil tips, in normal individuals, can propagate up to 3 mm below the foramen magnum, in contrast with patients suffering from CM, in which their downward displacement can exceed 5 mm<sup>37</sup>. This measurement, along with the 'peg-like' aspect of the tonsils and narrowing or complete effacement of the subarachnoid space at the foramen magnum, constitute a constellation of imaging criteria for the reliable and reproductive distinguishment of these patients. They are a relatively capable aid and a valuable tool in distinguishing Chiari malformations from another subgroup of individuals, in whom the migration of the tonsils was reported to be 5 mm below the level of the foramen magnum<sup>38</sup>. Additionally, an important aid in our effort to understand the pathophysiology of CM type I is offered by cine-flow MRI, which allows us to study the dynamics of CSF flow at the posterior fossa and foramen magnum region<sup>39-41</sup>. Cardiac-gated phase contrast MRI is studying dynamic processes, such as blood and CSF flow and there are studies that assume to be a correlation between postoperative symptom relief and improved CSF flow on cine MRI at the foramen magnum<sup>42,43</sup>.

With the advent and widespread availability of MRI, another subcategory of Chiari patient arose, namely that constituting the group of asymptomatic individuals. CMIs are an increasingly recognized incidental finding on neuroimaging studies, the significance of which is not well investigated. Researchers found that within a population of individuals who underwent MR imaging, 0.77% possessed sufficient tonsillar herniation to meet generally accepted criteria for the CMI. Among them, 14% did not report any relevant symptomatology<sup>44</sup>. According to them, the extent of tonsillar herniation and the overall MR imaging features recorded in this population is similar to that observed in symptomatic patients, suffering from CM. Based on that, it was proposed that isolated tonsillar herniation is of limited prognostic utility, and should be evaluated as a whole, along with all available clinical and imaging data, including assessment of CSF obstruction and the occurrence or not of syringomyelia. Finally, we would like to mention another subcategory of this entity that was added relatively recently, and was introduced by Grabb and colleagues<sup>45</sup>. This subgroup of patients was further analyzed by Bollo and colleagues<sup>46</sup>. They constituted a

unique subgroup of patients, as they exhibited unique radiographic findings and share in common the concept of necessitating cranio-cervical fusion. The selection criteria for the incorporation of patients in the aforementioned subgroup included the presence of a C1.5 malformation (that is, brainstem herniation through the foramen magnum, an abnormal clival-cervical angle (which is less than  $125^\circ$ ) and basilar invagination.

It is well known that several studies were centered on the evaluation of the utility of a wide spectrum of divergent preoperative MRI parameters in the prediction of outcome in patients suffering from Chiari I malformation. Relatively recently<sup>47</sup>, a systematic review and meta-analysis was performed, aiming to the determination of specific preoperative imaging features that really matter, regarding the course of the disease. More precisely, they attempted to recognize if there was a constellation of imaging characteristics that could correlate with the existence of preoperative symptoms, the necessity of surgical decompression, as well as the possibility to predict the degree of improvement after surgical decompression.

This meta-analysis revealed that the degree of tonsillar herniation, the extent of clivus gradient, and a degree of scoliotic curve of  $> 20^\circ$  were positively correlated with the presence of preoperative syrinx. Apart from that, preoperative findings consistent with a centrally located syringomyelic cavity, shorter length of the syrinx, as well as a scoliotic curve  $< 20^\circ$  were predictors of a postoperative stability and improvement.

#### Historical review of surgical treatment of Chiari malformations

Another important and evolving issue about Chiari malformations is centered on its surgical treatment and the evolution of the surgical techniques and goals, which partly mirrors the acquisition of new data regarding the embryopathology, pathogenesis, neuroimaging and surgical techniques in general. Attempting a historical overview, we can discern a lot of modifications of the applied surgical techniques.

In 1932, Van Houweninge-Graafthdijk was the first author who suggested surgical treatment of CM<sup>1</sup> patients, which comprised of suboccipital decompression and resection of cerebellar tonsils. His basic tenet was to relieve CSF flow obstruction at the level of the foramen magnum. All of the patients described in his monograph died, either immediate postoperatively, or due to postoperative complications. Another surgical approach was reported in 1934 by Ebenius, who announced a case of basilar impression, treated with suboccipital decompression<sup>48</sup>. Unfortunately, the confusion regarding the nomenclature and relevant definition of the underlying pathology was evident. Because of that, and attempting to better order

and categorize the existing evidence and establish a better definition of the known relevant entities Russell suggested in 1949 that the 'Arnold–Chiari' term should be used only for patients with concomitant by spina bifida<sup>49</sup>. Later on, Baker<sup>50</sup> presented 11 cases as Arnold–Chiari malformations, which exhibited tonsil descent to the C1 level. He stated that, in order to consider that the cerebellar tonsils are located in a normal level, their tips should lie above a line which is demarcated by the clivus tip and the posterior rim of the foramen magnum, on a lateral X-ray.

The next step in the surgical approach of the malformation constitutes the adoption of another surgical protocol, which is one of the accepted treatment strategies nowadays. This consists of a midline suboccipital approach, bone opening limited to the lower part of the occipital bone and the posterior arch of the atlas, dura opening in a T- or Y-shaped fashion, and, depending on the extent of the tonsillar herniation, the damaged parts may be shrunk with electrocautery. The aim of this shrinkage is the elimination of the blockage of CSF flow at the level of the fourth ventricle. To enhance the dura opening and the available space around the tonsils, a patch is utilized. A relevant detailed monograph, presenting the obtained surgical experience with the management of Chiari malformations, is available<sup>51</sup>.

As the real offending pathophysiology and origin of CM have still not been entirely elucidated, new suggestions have been presented for treatment of this malformation. One of the most important theories was suggested by Goel in 2015<sup>52</sup>. He proposed a new concept regarding CM (with or without concomitant basilar invagination), based on the assumption that it is secondary to atlantoaxial instability. Based on that acceptance, he performed C1–C2 posterior instrumented fusion alone, without concomitant posterior fossa decompression. Although there are reports regarding patients treated only with atlantoaxial fixation which state that the tonsils migrate back to their original position and the syrinx cavity collapses following the surgical procedure, this surgical approach will require further bulk of evidence in order to be widely accepted and validated<sup>53</sup>. Because of that, we consider that this manuscript and the approach described therein are highly controversial. According to our opinion, this controversy should be mentioned.

As we have already mentioned, after the initial description of the entity of Chiari malformation in 1891, there have been added several descriptions across the literature which display several features that are unable to match accurately with the initial descriptions of these malformations. Based on that, there was a tendency to expand our description regarding the conditions that are

classified under this general term (e.g., Chiari 0, Chiari 1.5, and Chiari 3.5 malformations). Additionally, a considerable debate exists about the entity of Chiari IV malformation, regarding its pathophysiology and what exactly is encompassed under this term. In order to review all these points of interest, a recent review has arisen in the literature which is intended to declare the anatomical, pathophysiological, and clinical aspects of the newly recognized entities, entitled under the term of Chiari malformations<sup>53</sup>. A more detailed discussion, centered on the options of surgical treatment in conjunction with the specific subtype of Chiari malformation, follows.

### Chiari malformation type 0

This term responds to a pathological entity which incorporates syringo-hydromyelia which responds to craniocervical decompression but is not accompanied necessarily with tonsillar herniation. Alternatively, a minimum herniation (<3 mm) could be revealed<sup>54</sup>. The relevant symptomatology is attributed to a disruption of CSF flow at the level of the craniocervical junction, as it is considered to be the case in CM I. Based on that, there was a confusion regarding the most appropriate terminology, with terms such as “borderline Chiari”, “Chiari-like pathophysiology” and “tight cisterna magna” adopted to describe this entity<sup>55</sup>. Newton reported another variation of this pathology, which constituted of syringo-hydromyelia without hindbrain herniation<sup>56</sup>. Later on, in 1998, this condition was referred as Chiari malformation type 0 by Iskandar. He reported a small group of patients who underwent posterior cranial fossa decompression, after which the relevant symptomatology along with the dimensions of the syrinx were substantially ameliorated<sup>54</sup>.

Considerable studies have been accomplished, centered on the effort to elucidate the underlying anatomy of this condition. A relevant analysis was published by Tubbs<sup>57</sup>, who attempted to measure the dimensions of the posterior cranial fossa in patients harboring Chiari 0 malformation. The study revealed distorted/compromised contents of the posterior cranial fossa, along with caudal descent of the brain stem. Their remarks were consistently verified and expanded by other researchers<sup>55,58-60</sup>. Attempts have been performed in order to investigate the underlying pathogenetic mechanism of this condition. Regarding the formation of the syrinx cavity, it should be attributed to a disturbance of CSF circulation, although cerebellar herniation is not a prerequisite. The combination of disturbances of CSF circulation with the absence of tonsillar herniation may be due to a crowded posterior fossa, along with intraoperative findings, consisting of veils and/or arachnoidal adhesions at the vicinity of the outlets of the

fourth ventricle<sup>54,55,57</sup>. More precisely, the foramen of Magendie is most commonly involved, whereas the foramina of Luschka are not usually impaired. Based on that data, a hypothesis has been formulated, which states that CM0 and CMI share a common pathophysiological substrate as such, they should be rather regarded as a continuation of a common underlying process rather than separate entities. Regarding the clinical presentation of Chiari 0, it follows the pattern of manifestations that is attributed to CMI, that is scoliosis, torticollis, neck pain, limited neck movement, gait disturbance, extremity weakness and paresthesias, accompanied by intermittent headaches.

Regarding the optimum surgical management of this entity, the ultimate goal of our treatment strategy is to the establishment of normal CSF flow, via the means of posterior cranial fossa decompression. There is evidence which supports that all patients reported amelioration of their symptoms, accompanied with resolution of the relevant syringomyelia, to a lesser or greater extent<sup>53</sup>. Operative treatment consists of craniectomy at the posterior margin of the foramen magnum along with resection of most of the posterior arch of C1, in order to relieve the congestion of the elements of the posterior cranial fossa. This is augmented with a dural incision and lysis of arachnoid adhesions, to establish sufficient CSF flow from the foramen of Magendie, as well as with duraplasty, achieved with autologous or allogeneic pericranium. The latter manipulation is not universally been accepted as a constituent of the operative treatment.

### Chiari Malformation 1.5

This entity is defined as incorporating the combination of cerebellar herniation, with features constituent with them characterizing Chiari type 1, along with elongation and caudal displacement of the brain stem, as it is verified by the displacement of the obex inferior to the foramen magnum, combined with elongation of the fourth ventricle<sup>61,62</sup>. Despite the fact that the exact incidence of CM1.5 is yet to be verified, it is considered that this malformation is more rarely found relatively to the CMI variant<sup>63</sup>. Although CMI and CM1.5 share in common a lot of features regarding their anatomic and morphological counterparts, we should distinguish them as the operative outcomes differ substantially<sup>64</sup>. CM1.5 is regarded as being intimately related with CMI as there have been described cases of patients whose initial presentation was consistent with CMI (caudal displacement of the cerebellar tonsils >3-5 mm). During their follow-up, rhombencephalic caudal herniation was added, and they fulfill the criteria for subordination under the term of CM1.5<sup>64</sup>. Regarding their clinical characteristics, there is lack of a circumscribed

constellation of symptoms that could be regarded as diagnostic of this entity: the presentation resembles that of CMI. More precisely, relevant reports have mentioned that Valsalva maneuver-induced headache, dyspnea, jaw pain, dysarthria, opisthotonos, peri-oral numbness, negative gag reflex, lethargy, drop attacks, and upper or lower limb weaknesses constitute the usual mode of presentation<sup>61,65</sup>. As there is a possibility that an underlying etiology is hindered in these patients, such as hydrocephalus, craniosynostosis, and/or a brain tumor, it is of outmost importance to clarify that before any treatment decisions are undertaken. Although it is supported that posterior fossa decompression is suitable for the subgroup of patients suffering from craniosynostosis<sup>66</sup>, syringo-subarachnoid shunting has been included in the therapeutic armamentarium of these patients<sup>67</sup>. Another factor that differentiates CM1.5 from CM1 is related to the fact that the risk of re-developing syringomyelia is more significant in CM1.5, compared with CM1<sup>62</sup> and that the existence of tonsillar ectopia along with medullary descent are considered as negative prognostic factors, as these patients display a limited recovery following posterior cranial fossa decompression<sup>62</sup>.

### Chiari II Malformation

This malformation is considered an anomaly that is associated with a myelomeningocele and hydrocephalus in the vast majority of patients, and it consists of downward displacement of hindbrain<sup>68-70</sup>. Symptoms can arise in a subgroup of patients, in the order of 10–30%, with infants been more severely impaired<sup>68,71,72</sup>. According to McLone and Knepper<sup>11</sup>, CM-II development is the ultimate result of the underdevelopment of the posterior fossa, due to chronic CSF subtraction by the myelomeningocele. Symptomatology that appears in neonates and are already established at birth, being refractory to treatment, could be attributed to congenital cerebaldysplasia<sup>68-70</sup>. Autopsy studies identified defective myelination, associated with hypoplastic brainstem nuclei<sup>73</sup>, and this constellation of pathological features should be regarded as the end result of a chronic prenatal compression process<sup>68-74</sup>. According to a recent report<sup>75</sup>, respiratory impairment is considered the main indication for treatment. Regarding the most appropriate surgical treatment, a recent study states that bone decompression alone may be efficient in CM-II patients. Nevertheless, dural augmentation seems to be a useful surgical adjunct, as it offers a more extensive decompression<sup>68</sup>. Furthermore, in cases in which this pathology is complicated with syringomyelia, some authors have proposed the addition of intradural dissection,

aiming at identification of the normal spinal cord<sup>68,76</sup>. According to authors' experience<sup>68</sup>, this maneuver is associated with increased morbidity, due to distorted anatomy and eminent arachnoid adhesions. A proposed strategy suggests that this surgical manipulation is offered in the subgroup of patients that are characterized by the existence of syringomyelia<sup>68,74,77</sup>. Regardless of the adopted surgical treatment, overall mortality continues to be relatively high, throughout the patient life, as its course is invariably progressive.

### Chiari III Malformation

It is regarded as being the less commonly encountered subgroup of these patients since its initial referral by Chiari in 1891 to the best of our knowledge, about 60 cases have been reported<sup>53</sup>. Chiari described this entity as involving a herniation of the cerebellum through the foramen magnum into a cervical spina bifida. Additionally, he noted down a group of anatomical disorders which CMIII and CMII share in common: these include a small posterior cranial fossa associated with herniation of its contents, a deformed medulla, as well as hydrocephalus. A wide spectrum of other relevant anomalies has been attributed to this entity and this is probably related to the observation that the neurological deficiencies and the mortality rate are remarkably more severe in this population of patients, when they are compared with other subtypes of Chiari malformation<sup>78</sup>.

### Chiari Malformation 3.5

This entity refers to a recently recognized, albeit rare, variation of CMIII, which seems to be initially mentioned was in 1894 by Muscatello<sup>79</sup>. Recently<sup>80</sup>, a new classification protocol was adopted which considered this variant of CMIII, and referred to that as "Chiari 3.5". It is believed that CM3.5 and CMIII share in common an identical pathogenetic mechanism: although Chiari stated that CMIII should be attributed to hydrocephalus, newer theories have been adopted, which implicate a disruption of mesodermal development or that the pathogenetic substrate which is the offending mechanism for CMII may get involved in CMIII. More precisely, CSF leakage that occurs during neurulation process may be responsible for the incomplete development of the primitive ventricular system: consistent with that, a small posterior develops and this is the underlying cause for herniation of its elements through an encephalocele<sup>65,81</sup>. A distinguishing feature between CM3.5 and CMIII is the pathologic communication that exists in cases of CM3.5 between the neural tube and the foregut (neurenteric fistula)<sup>82</sup>.

### Chiari IV Malformation

In 1895, Hans Chiari added a fourth type to the already defined group of congenital anomalies, introducing the term "Chiari IV"<sup>83</sup>. Apart from that, there was an antecedent report<sup>84</sup> regarding this entity, which was known as Chiari IV malformation.

As far as the anatomic substrate is being considered, the major finding consists of an occipital encephalocele, protruding through the posterior fontanelle, incorporating the occipital lobe and its horns, as well as the choroid plexuses of the lateral ventricles, along with a constellation of other pathological features<sup>53</sup>. Researchers<sup>53</sup> have mentioned that the term Chiari IV malformation has been used incorrectly in the meantime, since the initial original description of this entity from Chiari. Because of that, a common error has become evident, that is the adoption of the concept that Chiari IV is basically characterized by cerebellar hypoplasia with or without pontine hypoplasia<sup>85</sup>. This could be attributed to the fact that cerebellar hypoplasia is erroneously considered as the most important abnormality which could be encountered in Chiari IV malformation<sup>86</sup>. Because of that, we would like to state that the primary and distinguishing feature which is unique in patients harboring Chiari IV malformation should be considered the existence of occipital encephalocele with supratentorial contents, as this is consistent with Chiari's original description.

Recently<sup>87</sup>, a group of authors introduced a novel subdivision of Chiari malformation, that is referred to as Chiari 0.5 malformation. They shared in a common a newly described feature, termed 'ventrolateral herniation' of the tonsils. According to them, it consists of crossing of the tonsils through a novel anatomic boundary, which bisects the caudal medulla at the level of the foramen magnum, unilaterally or bilaterally. In their initial description, the authors state that this finding is not able to preclude the existence of downward herniation of the cerebellar tonsils. Regarding their clinical presentation, the most prominent presenting feature was dysphagia, followed by sleep apnea, behavioral problems, macrocephaly, scoliosis, or back pain. Another observation that deserves special notion is the fact that headache was a more prominent feature of patients that are classified under the term CM-I, than in patients with ventrolateral herniation<sup>87</sup>. Regarding the proposed surgical treatment in the aforementioned group of patients, the authors<sup>87</sup> supported that suboccipital craniectomy alone, or combined with removal of the posterior arch of C1 without C2 laminectomy were more commonly performed in patients with ventrolateral herniation.

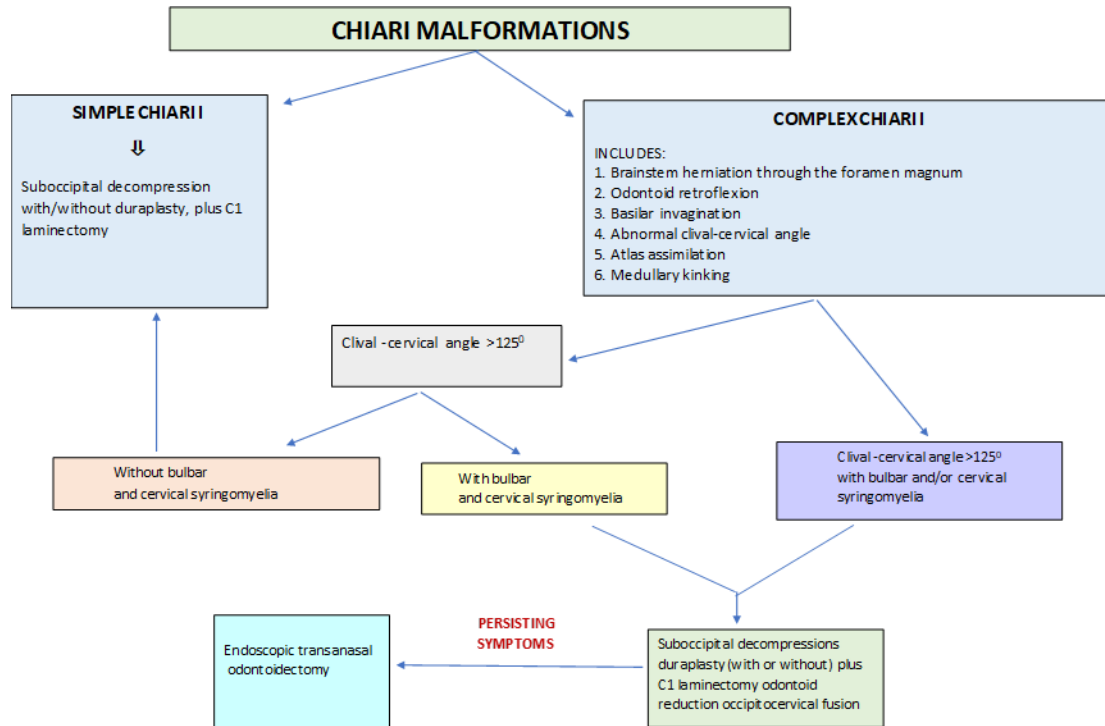
Regarding the other subtypes of Chiari malformations, it is common concept that surgical management should be

offered for CM-I, as it offers improvement of symptomatology; however, the recommended and optimal approach remains to be ascertained. Among the proposed alternatives, some authors advocate dural-sparing techniques, whereas duraplasty is preconceived by others<sup>88-95</sup>. Studies which are centered on the natural history of CM-I patients have stated that there is a possibility of spontaneous improvement of the relevant symptomatology in a subgroup of patients, a notification which does not stand for another group of patients, harboring dysphagia, sleep apnea, ataxia, sensory disturbances, or syringomyelia<sup>96-101</sup>. This selected category seems to be more appropriate for the application of surgical management, instead of offering the option of conservative follow-up. This constellation of symptoms is, in their majority, identical with that accompanying patient with CM-0.5. This could be considered as an indication that the surgical option should be our first line treatment in children who do not present with tonsillar herniation but medullary symptoms are consistent. Taking into consideration all of these parameters, it is supported that a multidisciplinary and cost-benefit analysis of observation versus surgery is necessary to determine which option should be offered to each individual patient. Whereas the combination of CM-I and central sleep apnea strongly indicates that posterior fossa decompression is the option which offers the best opportunity to ameliorate the clinical picture<sup>89,96,102,103,104</sup>, nausea and headache may respond positively to an observation-based protocol management<sup>105</sup>. It seems that operative management, following a detailed investigation along with a trial of conservative management, constituting of cervicomedullary decompression, remains the best treatment modality for the majority of symptomatic individuals<sup>106,107</sup>. There is ongoing controversy regarding the usefulness of duraplasty in association with decompression<sup>106</sup>. A recent relevant report exists which states that there is lack of convincing evidence capable to support a beneficial outcome associated with the addition of duraplasty<sup>108,109</sup>. Another surgical adjunct remains the opening of the arachnoid and lysis of the relevant adhesions, as well as the execution of tonsillar resection. Even though they are not performed in all patients who are considered as surgical candidates, they should be incorporated in our surgical plan whenever they are necessary in order to accomplish the intended decompression<sup>88</sup>.

It is postulated that central sleep apnea is positively correlated with tonsillar descent, along with effacement of the perimedullary subarachnoid space, evident on MRI<sup>53</sup>. According to a recent protocol<sup>53</sup>, it is postulated that duraplasty should be performed whenever is attainable. Otherwise, performing only posterior fossa decompression

should be regarded as a potentially palliative option, as it may be the only operation that should be performed, but we should never exclude the possibility to reoperate the patient at a later stage. The final decision could be taken intraoperatively in selected cases, and we can either

open the dura, perform a dural-splitting procedure, or a duraplasty based on the relevant anatomy of the underlying venous sinuses encountered in the posterior fossa. Figure S1 provides a proposed treatment algorithm for the management of Chiari malformations.



### Complications and Outcome

An important aim of our review was to provide quantitative information and reference on complications and outcome of surgical treatment: we have used information based on 50 plus important papers. According to a research-clinical study<sup>110</sup>, the estimated complication rate was 21.8%, with associated permanent surgical morbidity 3.2% and surgical mortality 1.3%. Regarding the short and long-term outcome of these patients, 73.6% of them reported improvement after 3 months, while 21% were unchanged. An overall neurological deterioration was recorded after a follow-up period that reaches 10 years. Another important clinical note was related to the fact that there was a straightforward correlation between the degree of neurological deficits and the underlying severity of arachnoid pathology. When data were recorded that were relevant to the ultimate patient outcome, that study revealed that the number of previous decompressions, the severity of arachnoid adhesions and their management, the type of duraplasty performed and surgical experience were the main determinant factors. This study concluded that suboccipital decompression that was performed for the first time, combined with arachnoid dissection, opening

of the foramen of Magendie, and an alloplastic duraplasty offered the optimum postoperative outcome. More precisely, this surgical strategy was associated with the lowest surgical morbidity and mortality rate, the most significant postoperative improvement, as well as the lowest rate of neurological recurrence in the long term. On the contrary, the adoption of decompression protocols that do not incorporate arachnoid opening along with duraplasty seems that does not confront with a subset of pathophysiological parameters that are of paramount importance for a significant proportion of patients. In concordance to that, these researchers support that the severity of arachnoid fibrosis and scarring is correlated with neurological signs at the time of initial diagnosis, as well as the postoperative outcome. They also state that this could be the most crucial factor in order to attribute the cause for the lower success rate of secondary decompressions. In accordance with the previous report, another study<sup>111</sup> proposed the combination of bone decompression along with duraplasty as the mostly recommended technique for the management of patients with CM. In patients with complex CM (that is, the subgroup of patients with associated syringomyelia), this study

revealed that the combination of bony decompression along with tonsillar resection resulted in an improved patient outcome, in terms of a higher rate of resolution of clinical signs and symptoms. Nevertheless, this technique was accompanied with the highest rate of complications among all methods, including intracranial infection, aseptic meningitis and CSF leak.

We strongly consider that it might be very interesting to use information given based on 50 plus important papers and to graphically illustrate the actual practical concept of subtypes in a unifying view. The 'Complications and Outcome' section of our manuscript is based on that data and a graphical illustration regarding the main surgical strategy is presented under Table S5.

**Table S5**

Chiari Subtype	Surgical Treatment Options
I	Suboccipital decompression ± outer layer of dura open
II	Suboccipital decompression + outer layer of dura open ± arachnoid bands dissection
III	Suboccipital decompression + Tonsillectomy ± Shunt
IV	Shunt ± Suboccipital decompression

A pathological entity which is characterized by a pathologic, ectopic position of the cerebellar tonsils, under the level of the foramen magnum, which may or may not be accompanied by syringomyelia, is described under the term Chiari malformation, based on the anatomical studies of the Austrian pathologist Hans Chiari (1851–1916). He was the first to denote this anatomical anomaly, as it was denoted from his autopsy studies.

More than one century after the original description, different types of relevant malformations have been studied. Nevertheless, the distinction which has the most fundamental importance refers to type I on one hand and types II-IV on the other hand. The concept under this differentiation is based on the assumption that the latter types are strongly and almost exclusively associated with embryonal defects of the neural tube (i.e., cranial or spinal dysraphism). This circumstance constitutes the underlying condition that is capable of distinguishing Chiari malformations type I versus types II-IV, in terms of clinical presentation, presenting symptoms, natural history, and treatment options. The detailed examination of all cases that are included under the general term Chiari malformations highlights that the entity of hindbrain herniation, with or without an accompanying syringomyelia, represents the common denominator in the vast majority of types of Chiari malformation. The only remarkable differentiation relates to the entity of type IV, which consists of an occipital encephalocele, associated with supratentorial contents and cerebellar hypoplasia<sup>112,113</sup>. Apart from that, the entity type 0 has recently been introduced, in order to comprise a subgroup of patients who are suffering from isolated syringomyelia, along with compromised and/or distorted contents of the posterior cranial fossa. A prerequisite in order to fulfill the

induction criteria to this entity is the absence of tonsillar herniation, as well as the exclusion of all other potential causes of syringomyelia<sup>54,57,58</sup>.

Besides that, the term type 1.5 has been introduced in order to classify all cases presenting with tonsillar herniation, as described in cases with type I, which share in common another feature, that is herniation of the elongated brainstem and the fourth ventricle. Although the latter finding is consistent with Chiari II, no other elements of dysraphism are coexistent. Bibliographic reports suggest that this subtype should be considered as an advanced ('bulbar variant') and more excessive form of type I<sup>62,64</sup>. Apart from that, any evidence of differentiation regarding their clinical signs and symptoms, as well as their ultimate outcome after surgery, are lacking<sup>114</sup>, but they are still considered as distinct pathologic entities. Although in the past several authors seemed to group all these cases into variations on a single pathologic entity, this is not appropriate, albeit they share in common several morphological features.

There is recent bulk of evidence that are derived from experimental<sup>115,116</sup> and radiological<sup>117,118</sup> studies, which have suggested a new model of paravascular and interstitial flow of CSF, termed as 'glia-lymphatic' circulation. When this concept is applied in cases that are included under the term Chiari malformation type I', it may work as corroborative evidence that supports the concept that the offending cause of reduced cerebral compliance may be intrinsic, i.e., within the brain interstitium.

## Conclusions

As the natural history of this complex malformation is still under investigation, it is natural consequence that its



management is not static but, instead, is continuously evolving. It is common concept that the current trend is shifted toward operative treatment at earlier stages, mainly in selected patients, harboring milder symptomatology. Our preliminary experience leads to the conclusion that this concept results to improved long-term neurological outcomes. The diagnostic evaluation has accordingly evolved, as it has been shifted from simple morphometric measurements using X-ray tomography, to more sophisticated modalities as cine MRI. In concordance to that, the available treatment options have evolved from simple bone decompression of the posterior fossa to the addition of duraplasty with patch graft and management of the associated atlanto-axial instability with realignment and reduction via the aid of anterior or posterior fixation.

New terminology, such as asymptomatic Chiari and complex Chiari malformations has been adopted, being adapted to more sophisticated diagnostic evaluation techniques, and new treatment algorithms are created. Even though a lot of unresolved issues remain so far, as Chiari malformations are investigated, the progression that has been achieved regarding our knowledge of this clinical entity is considerable, and its effect on the overall outcome of our patients could be regarded as more than impressive. Comparing current data with the preliminary ones, we can support the conviction that hope and potential resolution has already been offered to a group of patients previously doomed to a life of disability and discomfort.

### Supplementary Materials:

**Figure S1:** Proposed treatment algorithm for management of Chiari malformations

**Table S1:** List of the 50 most cited papers, centered on Chiari malformations.

**Table S2:** List of 10 most cited relevant papers, rearranged, based on citations per year.

**Table S3:** List of the countries with more than 3 records in our list.

**Table S4:** List of journals with more than 3 publications, dedicated to Chiari malformations.

**Table S5:** Graphical illustration regarding the main surgical strategy, regarding any specific subtype of Chiari malformation.

**Funding:** This research received no external funding

**Acknowledgments:** Not applicable

### Author Contributions:

**Conceptualization:** Dimitrios Panagopoulos, Georgios Strantzalis, Efstathios Boviatsis, Stephanos Korfiatis.

**Methodology:** Dimitrios Panagopoulos

**Software:** Dimitrios Panagopoulos, Maro Gavra

**Validation:** Dimitrios Panagopoulos, Georgios Strantzalis, Efstathios Boviatsis, Stephanos Korfiatis, Maro Gavra

**Formal Analysis:** Dimitrios Panagopoulos, Ploutarchos Karydakakis

**Investigation:** Dimitrios Panagopoulos, Ploutarchos Karydakakis

**Resources:** Dimitrios Panagopoulos, Maro Gavra

**Data Curation:** Dimitrios Panagopoulos, Ploutarchos Karydakakis

**Writing – Original Draft Preparation:** Dimitrios Panagopoulos, Georgios Strantzalis, Efstathios Boviatsis, Stephanos Korfiatis

**Writing – Review & Editing:** Dimitrios Panagopoulos, Georgios Strantzalis, Efstathios Boviatsis, Stephanos Korfiatis, Maro Gavra

**Visualization:** Maro Gavra, Ploutarchos Karydakakis

**Supervision:** Dimitrios Panagopoulos

**Project Administration:** Not applicable

**Funding Acquisition:** Not applicable

**Data Availability Statement:** Data is contained within the article or supplementary material

**Conflicts of Interest:** The authors declare no conflict of interest

## References

- Mancarella C, Delfini R, Landi A. Chiari Malformations. *Acta Neurochir Suppl.* 2019;(125):89-95. doi: 10.1007/978-3-319-62515-7\_13.
- Chiari H. Concerning alterations in the cerebellum resulting from cerebral hydrocephalus (translated by A. Radkowski). *PediatrNeurosci* 1987;(13):3-8.
- Chiari H. Über Veränderungen des Kleinhirns infolge von Hydrocephalie des Grosshims. *Dtsch Med Wochenschr* 1891;(17):1172-5.
- Chiari H. Über Veränderungen des Kleinhirns, der Pons und der Medulla oblongata infolge von congenitaler Hydrocephalie des Grosshirns. *Denkschr Akad Wiss Wien.* 1895;(63):71-115.
- Milhorat TH, Chou M.W, Trinidad EM, Kula RW, Mandell M, Wolpert C, Speer MC. Chiari I Malformation Redefined: Clinical and Radiographic Findings for 364 Symptomatic Patients. *Neurosurgery* 1999; 44(5):1005-1017 <https://doi.org/10.1097/00006123-199905000-00042>.
- Cleland J. Contribution to the study of spina bifida, encephalocele, and anencephalus. *J Anat Physiol.* 1883;(17) (Pt 3):257-92 PMID: PMC1310092.
- Bejjani GK. Definition of the adult Chiari malformation: a brief historical overview. *Neurosurg Focus* 2001;(11):1-8.
- Carey M, Fuell W, Harkey T, Gregory W. Albert G.W. Natural history of Chiari I malformation in children: a retrospective analysis. *Childs Nerv Syst.* 2021;37(4):1185-1190.
- Gardner WJ. Hydrodynamic mechanism of syringomyelia: its relationship to myelocoele. *J Neurol Neurosurg Psychiatry* 1965;28(3):247-59. doi: 10.1136/jnnp.28.3.247.
- Williams B. Cerebrospinal fluid pressure-gradients in spina bifida cystica, with special reference to the Arnold-Chiari malformation and aqueductal stenosis. *Dev Med Child Neurol Suppl* 1975;(35):138-50. doi: 10.1111/j.1469-8749.1975.tb03594.x.
- McLone DG, Knepper PA. The cause of Chiari II malformation: a unified theory. *PediatrNeurosci.* 1989;15(1):1-12. doi: 10.1159/000120432.
- Shoja MM, Johal J, Oakes JW, Tubbs SR. Embryology and pathophysiology of the Chiari I and II malformations: A comprehensive review. *Clin Anat* 2018;31(2):202-215 doi: 10.1002/ca.22939. Epub 2017 Dec 4.
- Nishikawa M, Sakamoto H, Hakuba A, Nakanishi N, Inoue Y. Pathogenesis of Chiari malformation: a morphometric study of the posterior cranial fossa. *J Neurosurg* 1997;86(1):40-7. doi: 10.3171/jns.1997.86.1.0040.
- Stovner U, Bergan U, Nilsen G, Sjaastad O: Posterior cranial fossa dimensions in the Chiari I malformation: relation to pathogenesis and clinical presentation. *Neuroradiol* 1993;(35):113-118.
- Vega A, Quintana F, Berciano J: Basichondrocranium III anomalies in adult Chiari type I malformation: a morphometric study. *J Neurol Sci* 1990;(99):137-145.
- O'Rahilly R, Muller F, Meyer DB: The human vertebral column at the end of the embryonic period proper. The occipito-cervical region. *J. Anat* 1983;(136):181-195.
- Oldfield EH, Muraszko K, Shawker TH, Patronas NJ. Pathophysiology of syringomyelia associated with Chiari I malformation of the cerebellar tonsils. Implications for diagnosis and treatment. *J Neurosurg* 1994;80(1):3-15 doi: 10.3171/jns.1994.80.1.0003.
- Sekula Jr RF, Arnone GD, Crocker C, Aziz KM, Alperin N. The pathogenesis of Chiari I malformation and syringomyelia. *Neurol Res* 2011;33(3):232-9
- Holly LT, Batzdorf U. Chiari malformation and syringomyelia. The pathogenesis of Chiari I malformation and syringomyelia. *J Neurosurg Spine* 2019;(31):619-628.
- Arnautovic A, Splavski B, Boop FA, Arnautovic KI: Pediatric and adult Chiari malformation Type I surgical series 1965-2013: a review of demographics, operative treatment, and outcomes. *J Neurosurg Pediatr* 2015;(15):161-177.
- Gardner WJ, Angel J: The mechanism of syringomyelia and its surgical correction. *Clin Neurosurg* 1958;(6):131-140.
- Sadler B, Kuensting T, Strahle J, Sung Park T, Smyth M, Limbrick D.D, Dobbs M.B, Haller G, Gurnett C.A. Prevalence and Impact of Underlying Diagnosis and Comorbidities on Chiari I Malformation. *Pediatr Neurol* 2020;(106):32-37 doi: 10.1016/j.pediatrneurol.2019.12.005.
- Urbizu A, Toma C, Poca MA, Sahuquillo J, Cuenca-Leon E, Cormand B, and Macaya A. Chiari malformation type I: a case-control association study of 58 developmental genes. *PLoS One* 2013;(8), e57241.
- Strahle J, Muraszko KM, Kapurch J, Bapuraj JR, Garton HJ, Maher CO. Chiari malformation Type I and syrinx in children undergoing magnetic resonance imaging. *J Neurosurg Pediatr* 2011;(8):205-213.
- Kelly MP, Guillaume TJ, and Lenke LG. Spinal Deformity Associated with Chiari Malformation. *Neurosurg Clin N Am* 2015;(26):579-585.
- Loukas M, Shayota BJ, Oelhafen K, Miller JH, Chern JJ, Tubbs RS, Oakes WJ. Associated disorders of Chiari

- Type I malformations: a review. *Neurosurg Focus* 2011;(31), E3.
27. Davidson L, Phan T.N, Myseros J.S, Magge S.N, Oluigbo C, Sanchez C.E, Keating R.F. Long-term outcomes for children with an incidentally discovered Chiari malformation type 1: what is the clinical significance? *Childs Nerv Syst* 2021;37(4):1191-1197.
  28. Albert G.W. Chiari Malformation in Children. *Pediatr Clin North Am.* 2021 ;68(4):783-792. doi: 10.1016/j.pcl.2021.04.015.
  29. Milhorat TH, Capocelli AL Jr, Anzil AP, Kotzen RM, Milhorat RH: Pathological basis of spinal cord cavitation in syringomyelia: analysis of 105 autopsy cases. *J Neurosurg* 1995;(82):802–812.
  30. Bilston LE, Stoodley MA, Fletcher DF: The influence of the relative timing of arterial and subarachnoid space pulse waves on spinal perivascular cerebrospinal fluid flow as a possible factor in syrinx development. *J Neurosurg* 2010;(112):808–813.
  31. Stoodley MA, Brown SA, Brown CJ, Jones NR: Arterial pulsation-dependent perivascular cerebrospinal fluid flow into the central canal in the sheep spinal cord. *J Neurosurg* 1997;(86):686–693.
  32. Chatterjee S, Shivhare P, Verma SG. Chiari malformation and atlantoaxial instability: problems of co-existence. *Childs Nerv Syst* 2019;35(10):1755-1761 doi: 10.1007/s00381-019-04284-z.
  33. Levy WJ, Mason L, Hahn JF. Chiari malformation presenting in adults: a surgical experience in 127 cases. *Neurosurgery* 1983;(12):377–390.
  34. Dyste GN, Menezes AH, VanGilder JC. Symptomatic Chiari malformations. *J Neurosurg* 1989;(71):159–168.
  35. Menezes AH. Primary craniovertebral anomalies and the hindbrain herniation syndrome (Chiari I): data base analysis. *Pediatr Neurosurg* 1995;(23):260–269.
  36. Menezes AH, Greenlee JDW, Donovan KA. Honored guest presentation: lifetime experiences and where we are going: Chiari I with syringohydromyelia—controversies and development of decision trees. *Clin Neurosurg* 2005;(52):297–305.
  37. Aboulezz AO, Sartor K, Geyer CA, Gado MH. Position of cerebellar tonsils in the normal population and in patients with Chiari malformation: a quantitative approach with MR imaging. *J Comput Assist Tomogr* 1985;9(6):1033–6.
  38. Barkovich AJ, Wippold FJ, Sherman JL, Citrin CM. Significance of cerebellar tonsillar position on MR. *Am J Neuroradiol* 1986;7(5):795–9.
  39. McCluggage SG, Oakes WJ. The Chiari I malformation. *J Neurosurg Pediatr* 2019;(1);24(3):217-226. doi: 10.3171/2019.5.PEDS18382.
  40. Battal B, Kocaoglu M, Bulakbasi N, Husmen G, Sanal TH, Tayfun C: Cerebrospinal fluid flow imaging by using phase-contrast MR technique. *Br J Radiol* 2011;(84):758–765.
  41. Armonda RA, Citrin CM, Foley KT, Ellenbogen RG: Quantitative cine-mode magnetic resonance imaging of Chiari I malformations: an analysis of cerebrospinal fluid dynamics. *Neurosurgery* 1994;(35):214–224.
  42. McGirt MJ, Nimjee SM, Fuchs HE, George TM: Relationship of cine phase-contrast magnetic resonance imaging with outcome after decompression for Chiari I malformations. *Neurosurgery* 2006;(59):140–146.
  43. J Meadows J, Kraut M, Guarnieri M, Haroun RI, Carson BS. Asymptomatic Chiari Type I malformations identified on magnetic resonance imaging. *J Neurosurg* 2000;92(6):920-6. doi: 10.3171/jns.2000.92.6.0920.
  44. Brockmeyer DL, Spader HS. Complex Chiari Malformations in children: Diagnosis and management. *Neurosurgery Clinics of North America* 2015;(26)(4):555-560.
  45. Grabb PA, Mapstone TB, Oakes WJ. Ventral brain stem compression in pediatric and young adult patients with Chiari I malformations. *Neurosurgery* 1999;44(3):520–7 [discussion: 527–8].
  46. Bollo RJ, Riva-Cambrin J, Brockmeyer MM, Brockmeyer DL. Complex Chiari malformations in children: an analysis of preoperative risk factors for occipitocervical fusion. *J Neurosurg Pediatr* 2012;10(2):134–41.
  47. Atchley T.J, Elizabeth N, Alford E.N, Rocque B.G. Systematic review and meta-analysis of imaging characteristics in Chiari I malformation: does anything really matter? *Childs Nerv Syst* 2020;36(3):525-534.
  48. Ebenius B. The roentgen appearance in four cases of basilar impression. *Acta Radiol (Stockolm)* 1934;(15):652–6.
  49. Russell DS. Observations on the pathology of hydrocephalus. MRC Special Report No. 265. London: Her Majesty's Stationery Office; 1949. 4th impression 1968.
  50. Baker WC. Infantile hydrocephalus. Some clinical and pathological aspects. II. Pathological aspects. *East Afr Med J.* 1963;(40):544–51.
  51. Tubbs RS, McGirt MJ, Oakes W.J. Surgical experience in 130 pediatric patients with Chiari I malformations. *J Neurosurg* 2003;(99):291–296 <https://doi.org/10.3171/jns.2003.99.2.0291>.
  52. Goel A. Is atlantoaxial instability the cause of Chiari malformation? Outcome analysis of 65 patients treated by atlantoaxial fixation. *J Neurosurg Spine* 2015;22(2):116–27.
  53. Haddad F.A, Qaisi I, Joudeh N, Dajani H, Jumah F, Elmashala A, Adeeb N, Chern J.J, Tubbs RS. The newer classifications of the chiari malformations with clarifications: An anatomical review. *Clin Anat*

- 2018;31(3):314-322. doi: 10.1002/ca.23051. Epub 2018 Feb 20.
54. Iskandar BJ, Hedlund GL, Grabb PA, Oakes WJ. The resolution of syringohydromyelia without hindbrain herniation after posterior fossa decompression. *J Neurosurg* 1998;(89):212-216.
  55. Kyoshima K, Kuroyanagi T, Oya F, Kamijo Y, El-Noamany H, Kobayashi S. Syringomyelia without hindbrain herniation: tight cisterna magna. Report of four cases and a review of the literature. *J Neurosurg* 2002;(96):239-249.
  56. Newton EJ. Syringomyelia as a manifestation of defective fourth ventricular drainage. *Ann R Coll Surg Engl* 1969;(44):194-213.
  57. Tubbs RS, Elton S, Grabb P, Dockery SE, Bartolucci AA, Oakes WJ. Analysis of the posterior fossa in children with the Chiari 0 malformation. *Neurosurgery* 2001;(48):1050-1054; discussion 1054-1055.
  58. Chern JJ, Gordon AJ, Mortazavi MM, Tubbs RS, Oakes WJ. 2011. Pediatric Chiari malformation Type 0: a 12-year institutional experience. *J NeurosurgPediatr* 2011;(8):1-5.
  59. Isik N, Elmaci I, Kaksi M, Gokben B, Isik N, Celik M. A new entity: Chiari zero malformation and its surgical method. *Turk Neurosurg* 2011;(21):264-268.
  60. Sekula RF, Jr., Jannetta PJ, Casey KF, Marchan EM, Sekula LK, McCrady CS. Dimensions of the posterior fossa in patients symptomatic for Chiari I malformation but without cerebellar tonsillar descent. *Cerebrospinal Fluid Res* 2005;(2):11.
  61. Capra V, De Marco P, Merello E, Baffico AM, Baldi M, Divizia MT, Gimelli S, Mallet D, Raso A, Mascelli S, Toma P, Rossi A, Pavanello M, Cama A, Magnani C. Craniosynostosis, hydrocephalus, Chiari I malformation and radioulnar synostosis: probably a new syndrome. *Eur J Med Genet* 2009;(52):17-22.
  62. Tubbs RS, Iskandar BJ, Bartolucci AA, Oakes WJ. A critical analysis of the Chiari 1.5 malformation. *J Neurosurg* 2004;(101):179-183.
  63. Deng X, Yang C, Gan J, Yang B, Wu L, Yang T, Xu Y. Chiari malformation type 1.5 in male monozygotic twins: case report and literature review. *Clin Neurol Neurosurg* 2015;(130):155-158.
  64. Kim IK, Wang KC, Kim IO, Cho BK. Chiari 1.5 malformation: an advanced form of Chiari I malformation. *J Korean Neurosurg Soc* 2010;(48):375-379.
  65. Cesmebasi A, Loukas M, Hogan E, Kralovic S, Tubbs RS, Cohen-Gadol AA. The Chiari malformations: a review with emphasis on anatomical traits. *Clin Anat* 2015;(28):184-194.
  66. Scott WW, Fearon JA, Swift DM, Sacco DJ. Suboccipital decompression during posterior cranial vault remodeling for selected cases of Chiari malformations associated with craniosynostosis. *J NeurosurgPediatr* 2013;(12):166-170.
  67. Ömer N, Kisi MO, YurdalGezercan, Tahsin Erman. 2014. Chiari Malformation Type 1.5-related syringomyelia: treatment options differentiate this new entity from classic tonsillar ectopia: case report. *Neurosurgery Quarterly* 2014;(24):183-185.
  68. Talamonti G, Marcati E, Mastino L, Meccariello G, Picano M, D'Aliberti G. Surgical management of Chiari malformation type II. *Childs Nerv Syst* 2020;36(8):1621-1634.
  69. Kim I, Hopson B, Aban I, Rizk EB, Dias MS, Bowman R, Ackerman LL, Partington MD, Castillo H, Castillo J, Peterson PR, Blount JP, Rocque BG. Decompression for Chiari malformation type II in individuals with myelomeningocele in the National Spina Bifida Patient Registry. *J NeurosurgPediatr* 2018;(22):652-658.
  70. McDowell MM, Blatt JE, Deibert CP, Zwagerman NT, Tempel ZJ, Greene S. Predictors of mortality in children with myelomeningocele and symptomatic Chiari type II malformation. *J NeurosurgPediatr* 2018;(21):587-596.
  71. Talamonti G, D'Aliberti G, Collice M. Myelomeningocele: long-term neurosurgical treatment and follow-up in 202 patients. *J Neurosurg* 2007;(107) (5 Suppl Pediatrics):368-386.
  72. Protzenko T, Bellas A, Pousa MS, Protzenko M, Fontes JM, de Lima Silveira AM, Sá CA, Pereira JP, ManganelliSalomão RM, Salomão JF, dos Santos Gomes SC. Reviewing the prognostic factors in myelomeningocele. *Neurosurg Focus* 2019;(47) (4):E2.
  73. Gilbert JN, Jones KL, Rorke LB, Chernoff GF, James HE. Central nervous system anomalies associated with meningomyelocele, hydrocephalus, and the Arnold-Chiari malformation: reappraisal of theories regarding the pathogenesis of posterior neural tube closure defects. *Neurosurgery* 1986;(18):559-564.
  74. Vandertop WP, Asai A, Hoffman HJ, Drake JM, Humphreys RP, Rutka JT, Decker LE. Surgical decompression for symptomatic Chiari II malformation in neonates with myelomeningocele. *J Neurosurg* 1992;(77):541-544.
  75. Alford EN, Hopson BD, Safyanov F, Arynchyna A, Bollo RJ, Hankinson TC, Rocque BG, Blount JP. Care management and contemporary challenges in spina: a practice preference survey of the American Society of Pediatric Neurosurgery. *J NeurosurgPediatr* 2019;(24):548.
  76. Stevenson K. Chiari type II malformation: past, present, and future. *Neurosurg Focus* 2004;(16) (E5):1-7.
  77. Sacco D, Scott RM. Reoperation for Chiari malformations. *PediatrNeurosurg* 2003;(39):171-178.

78. Cakirer S. Chiari III malformation: varieties of MRI appearances in two patients. *Clin Imaging* 2003;(27):1-4.
79. Muscatello G. Ueber die angeborenen Spalten des Schädels und der Wirbelsäule. *Archiv fkliln Chir Bd* 1894;(47):162-301.
80. Fisahn C, Shoja MM, Turgut M, Oskouian RJ, Oakes WJ, Tubbs RS. The Chiari 3.5 malformation: a review of the only reported case. *Childs Nerv Syst* 2016;(32):2317-2319.
81. Ivashchuk G, Loukas M, Blount JP, Tubbs RS, Oakes WJ. Chiari III malformation: a comprehensive review of this enigmatic anomaly. *Childs Nerv Syst* 2015;(31):2035-2040.
82. Birinyi PV, Bieser S, Reis M, Guzman MA, Agarwal A, Abdel-Baki MS, Elbabaa SK. Impact of DTI tractography on surgical planning for resection of a pediatric prepontine neurenteric cyst: a case discussion and literature review. *Childs Nerv Syst* 2015;(31):457-463.
83. Chiari H. Überveränderungen des kleinhirns, des pons und der medulla oblongata infolge von congenitalerhydrocephalie des grosshirns. *Nature* 1895;(63):71-116.
84. Bayer. Zur Technik der Operation der Spina bifida und Encephalocele. *Prag med Woch* 1892;(4):346.
85. Poretti A, Boltshausen E, Huisman TA. Chiari Malformations and Syringohydromyelia in Children. *Semin Ultrasound CT MR* 2016;(37):129-142.
86. Tekin D US, Iyigun O. Primary cerebellar agenesis-Chiari IV malformation. *OMU Tip Derg* 2002;(19):213-216.
87. Morgenstern P.F, Tosi U, Cardenas R.U, Greenfield J.P. Ventrolateral Tonsillar Position Defines Novel Chiari 0.5 Classification. *World Neurosurg* 2020;(136):444-453.
88. Arnautovic A, Splavski B, Boop FA, Arnautovic Kl. Pediatric and adult Chiari malformation type I surgical series 1965-2013: a review of demographics, operative treatment, and outcomes. *J NeurosurgPediatr* 2015;(15):161-177.
89. Kennedy BC, Kelly KM, Phan MQ, et al. Outcomes after suboccipital decompression without dural opening in children with Chiari malformation type I. *J NeurosurgPediatr* 2015;(16):150-158.
90. Tubbs RS, Beckman J, Naftel RP, et al. Institutional experience with 500 cases of surgically treated pediatric Chiari malformation Type I. *J NeurosurgPediatr* 2011;(7):248-256.
91. Durham SR, Fjeld-Olenec K. Comparison of posterior fossa decompression with and without duraplasty for the surgical treatment of Chiari malformation type I in pediatric patients: a metaanalysis. *J NeurosurgPediatr* 2008;(2):42-49.
92. Caldarelli M, Novegno F, Vassimi L, Romani R, Tamburrini G, Di Rocco C. The role of limited posterior fossa craniectomy in the surgical treatment of Chiari malformation type I: experience with a pediatric series. *J Neurosurg* 2007;106(3 Suppl):187-195.
93. Galarza M, Sood S, Ham S. Relevance of surgical strategies for the management of pediatric Chiari type I malformation. *Child Nerv Syst* 2007;(23): 691-696.
94. Tubbs RS, McGirt MJ, Oakes WJ. Surgical experience in 130 pediatric patients with Chiari I malformations. *J Neurosurg* 2003;(99):291-296.
95. Lee A, Yarbrough CK, Greenberg JK, Barber J, Limbrick DD, Smyth MD. Comparison of posterior fossa decompression with or without duraplasty in children with Type I Chiari malformation. *Child Nerv Syst* 2014;(30):1419-1424.
96. Pomeraniec IJ, Ksendzovsky A, Awad AJ, Fezeu F, Jane JA Jr. Natural and surgical history of Chiari malformation type I in the pediatric population. *J NeurosurgPediatr* 2016;(17):343-352.
97. Strahle J, Muraszko KM, Kapurch J, Bapuraj JR, Garton HJ, Maher CO. Chiari malformation type I and syrinx in children undergoing magnetic resonance imaging. *J NeurosurgPediatr* 2011;(8):205-213.
98. Massimi L, Caldarelli M, Frassanito P, Di Rocco C. Natural history of Chiari type I malformation in children. *Neurol Sci* 2011;(32) (Suppl 3): S275-S277.
99. Strahle J, Muraszko KM, Kapurch J, Bapuraj JR, Garton HJ, Maher CO. Natural history of Chiari malformation type I following decision for conservative treatment. *J NeurosurgPediatr* 2011;(8):214-221.
100. Novegno F, Caldarelli M, Massa A, Chieffo D, Massimi L, Pettorini B, Tamburrini G, Di Rocco C. The natural history of the Chiari type I anomaly. *J NeurosurgPediatr* 2008;(2):179-187.
101. Gagnadoux F, Meslier N, Svab I, Menei P, Racineux JL. Sleep-disordered breathing in patients with Chiari malformation: improvement after surgery. *Neurology* 2006;(66):136-138.
102. Liu C, Ulualp SO. Type I Chiari malformation presenting with laryngomalacia and dysphagia. *Pediatr Int* 2015;(57):795-797.
103. Addo NK, Javadpour S, Kandasamy J, Sillifant P, May P, Sinha A. Central sleep apnea and associated Chiari malformation in children with syndromic craniosynostosis: treatment and outcome data from a supraregional national craniofacial center. *J NeurosurgPediatr* 2013;(11):296-301.
104. Dhamija R, Wetjen NM, Slocumb NL, Mandrekar J, Kotagal S. The role of nocturnal polysomnography in assessing children with Chiari type I malformation. *Clin Neurol Neurosurg* 2013;(115):1837-1841.

105. Langridge B, Phillips E, Choi D. Chiari malformation type 1: a systematic review of natural history and conservative management. *World Neurosurg* 2017;(104):213-219.
106. Curone M, Valentini LG, Vetrano I, Beretta E, Furlanetto M, Chiapparini L, Erbetta A, Bussone G. Chiari malformation type 1-related headache: the importance of a multidisciplinary study. *Neurol Sci* 2017;(38) (Suppl 1):91-93.
107. Beretta E, Vetrano IG, Curone M, Chiapparini L, Furlanetto M, Bussone G, Valentini LG. Chiari malformation-related headache: outcome after surgical treatment. *Neurol Sci* 2017;(38) (Suppl 1): 95-98.
108. Kalb S, Perez-Orribo L, Mahan M, Theodore N, Nakaji P, Bristol RE. Evaluation of operative procedures for symptomatic outcome after decompression surgery for Chiari type I malformation. *J Clin Neurosci* 2012;(19):1268-1272.
109. Chen J, Li Y, Wang T, Gao J, Xu J, Lai R, Tan D. Comparison of posterior fossa decompression with and without duraplasty for the surgical treatment of Chiari malformation type I in adult patients. *Medicine* 2017;(96): e5945.
110. Klekamp J. Surgical treatment of Chiari I malformation--analysis of intraoperative findings, complications, and outcome for 371 foramen magnum decompressions. *Neurosurgery* 2012;71(2):365-80; discussion 380.
111. Zhao JL, Li MH, Wang CL, Meng W. A Systematic Review of Chiari I Malformation: Techniques and Outcomes. *World Neurosurg* 2016;(88):7-14.
112. Frič R, Eide PK. Chiari type 1-a malformation or a syndrome? A critical review. *Acta Neurochir (Wien)*. 2020;162(7):1513-1525.
113. Tubbs RS, Demerdash A, Vahedi P, Griessenauer CJ, Oakes WJ. Chiari IV malformation: correcting an over one century long historical error. *Childs Nerv Syst* 2016; 32(7):1175–1179.
114. Liu W, Wu H, Aikebaier Y, Wulabieke M, Paerhati R, Yang X. No significant difference between chiari malformation type 1.5 and type I. *Clin Neurol Neurosurg* 2017;(157):34-39.
115. Iliff JJ, Nedergaard M. Is there a cerebral lymphatic system? *Stroke* 2013;(44)(6 Suppl 1): S93–S95.
116. Iliff JJ, Wang M, Liao Y, Plogg BA, Peng W, Gundersen GA, Benveniste H, Vates GE, Deane R, Goldman SA, Nagelhus EA, Nedergaard M. *Sci Transl Med* 2012;(15);4(147):147ra111.
117. Eide PK, Vatnehol SAS, Emblem KE, Ringstad G. Magnetic resonance imaging provides evidence of glymphatic drainage from human brain to cervical lymph nodes. *Sci Rep* 2018(8);8(1):7194.
118. Ringstad G, Vatnehol SAS, Eide PK. Glymphatic MRI in idiopathic normal pressure hydrocephalus. *Brain* 2017;(1);140(10):2691-2705.