

Published: July 31, 2022

**Citation:** Probowo NA, Dewi HI, et al., 2022. Diabetic Ketoacidosis and Acute Coronary Syndrome Due to Neck Abscess, Medical Research Archives, [online] 10(7).  
<https://doi.org/10.18103/mra.v10i7.2896>

Copyright: © 2022 European Society of Medicine. This is an open- access article distributed under the terms of the Creative Commons Attribution License, which permits unrestricted use, distribution, and reproduction in any medium, provided the original author and source are credited.

DOI  
<https://doi.org/10.18103/mra.v10i7.2896>

ISSN: 2375-1924

## CASE REPORT

### Diabetic Ketoacidosis and Acute Coronary Syndrome Due to Neck Abscess

Nurhasan Agung Prabowo\*<sup>1</sup>, Hana Indriyah Dewi<sup>1</sup>, Adhizti Naluriannisa Edya Nugraha<sup>1</sup>, Tonang Dwi Ardyanto<sup>1</sup>

<sup>1</sup> Sebelas Maret University

\* [dr.Nurhasan21@staff.uns.ac.id](mailto:dr.Nurhasan21@staff.uns.ac.id)

## SUMMARY

Diabetic ketoacidosis (DKA) is a life-threatening consequence of diabetes mellitus. Infection is the most common cause of DKA. A 41-year-old man came to the hospital emergency department with shortness of breath the day before, nausea, vomiting, coughing, pain and swelling in the left neck. The patient has a history of uncontrolled diabetes. A physical examination revealed Kussmaul's breathing and a lump the size of a tennis ball on the left side of his neck. Laboratory findings are: leukocytosis, an increase in blood sugar of 512 mg/dL; blood gas analysis shows acidosis, ketone examination reveals ketonuria; Electrocardiography shows waves of ischemic heart disease, with elevated Hs Troponin. Fine needle examination of the lump shows a neck abscess. The patient was diagnosed with DKA in type 2 diabetes mellitus, with the acute coronary syndrome and neck abscess. Surgical debridement, antibiotics, acute coronary syndrome therapy, and DKA therapy are treatments. The patient responded well to treatment.

## BACKGROUND

Type 2 diabetes mellitus (T2DM) patients with uncontrolled glucose levels are particularly vulnerable to bacterial infections<sup>1,2</sup>. A bacterial infection causes blood sugar levels to become uncontrollably high. Infection lead to diabetic ketoacidosis (DKA)<sup>3</sup>. DKA is a diabetic condition that produces significant metabolic abnormalities and can be fatal if left untreated. Diabetes is also an important cause of worldwide coronary artery disease (CAD). In diabetic people, the risk of CAD is estimated to be as high as 50%. The most important thing to remember about cardiovascular disease and diabetes is that the symptoms aren't always obvious or even felt<sup>4</sup>. Acute infections can inflame atherosclerotic plaques and coronary arteries and trigger systemic inflammatory responses. Acute infections may limit the lumen of atherosclerotic coronary segments and constrict the coronary vessels, inducing shear-induced platelet activity field<sup>5</sup>. The troponin increase is a phenomenon that has been linked to DKA patients and could be caused by metabolic stress, an acidosis-related toxin, an insulin deficiency, or the presence of free fatty acids on the myocyte. An already present coronary pathology could also cause hidden metabolic stress. A troponin rise in a diabetic patient should always be regarded as a cardiac anomaly. Even after a delay, the troponin kinetics do not allow us to determine if the aetiology is coronary or not<sup>6</sup>. Follow-up examination with angiography in this patient showed acute coronary syndrome. While CAD is a well-known precipitant factor for DKA, CAD may all develop as a result of DKA. It has a very high death rate if these two factors are combined. A surge in counter-regulating hormones, including adrenaline, cortisol, and glucagon, leads to a supply-demand mismatch, which causes myocardial necrosis. This is one of several hypothesized pathways for the complicated pathophysiology of 3 MI owing to DKA. Fatty acids are incorporated into the lipid structure of the myocyte membrane with the creation of

micelles, leading to the instability and rupture of this membrane when there is a high amount of free fatty acids in the blood during DKA. Additionally, a lack of insulin is linked to excessive levels of free fatty acids and ketone bodies, which prevent cells from absorbing glucose and deprive the heart of its energy source<sup>7</sup>. Case reports of DKA associated with neck abscess are relatively uncommon. If not treated promptly, DKA with neck abscess followed by acute coronary syndrome episodes will surely raise the risk of death. This case report aims to offer an overview of cases of DKA in T2DM caused by neck abscess, which then leads to acute coronary syndrome. The patient in this case report showed improvement after surgical debridement and antibiotics therapy. This case is interesting because the presence of a neck abscess induces the occurrence of diabetic ketoacidosis along with acute coronary syndrome. This condition is a rare case.

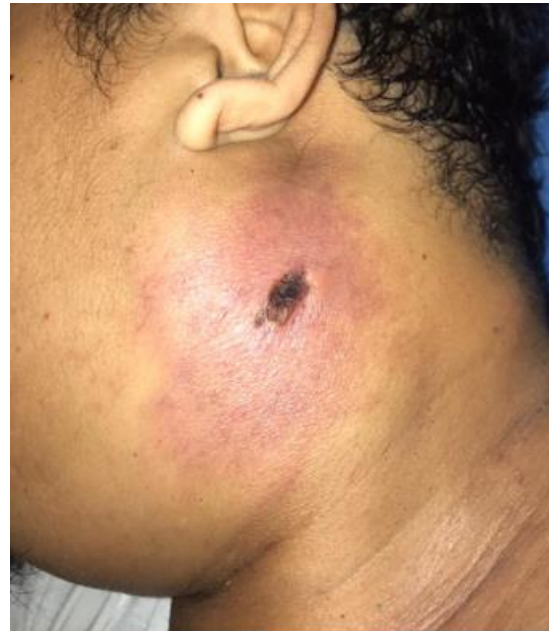## CASE PRESENTATION

A 41-year-old male patient was brought to the emergency department with shortness of breath one day before admission to the hospital. Shortness of breath neither improved with sitting position nor worsened by physical exercise. The patient complained of nausea, vomiting, and coughing, but no chest or epigastric pain was mentioned. The patient has a medical history of high blood glucose with no treatment. Three days before admission to the hospital, the patient mentioned a swelling on the left neck. The patient underwent an ultrasound examination at the previous hospital. The result was parotitis with an infection-like mass on the left neck. The patient received therapy as mentioned: Methylprednisolone 8mg b.i.d (twice in day), Cefixime 100mg b.i.d, Domperidone 10 mg t.i.d (three times in a day), Paracetamol 500mg t.i.d, Celecoxib 100mg b.i.d, and Ranitidine 150mg b.i.d, but the complaint did not improve.

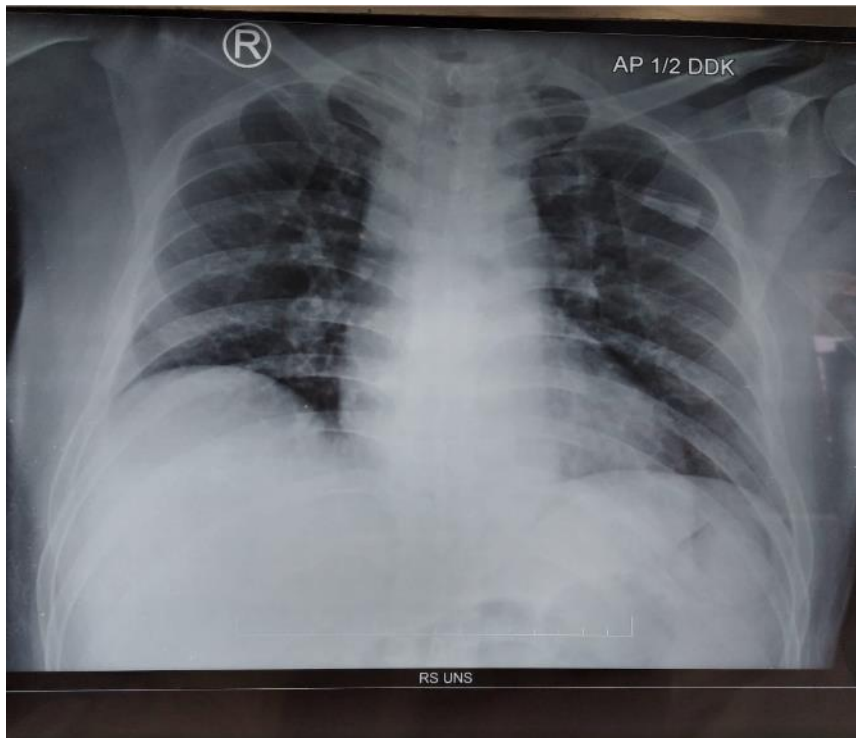
## INVESTIGATIONS

The patient came with *compos mentis* consciousness. Clinical examination revealed a dehydrated male with a pulse of 161x/min, a temperature of 36,6°C and blood pressure of 127/87 mmHg. Physical examination revealed Kussmaul's breathing with a respiratory rate of 42x/minute and a tennis ball-sized lump on the left side of his neck (figure 1). Complete blood count results were: hemoglobin 16.6 g/dL, hematocrit 49%, leukocytes 29,71.103/ul, platelets 394.103/ul. Blood glucose was 512 mg/dL. Kidney function examination showed that urea was 84 mg/dL, and creatinine was 1,2. The patient's electrolyte results were sodium 125,56; potassium 5,38; chloride 86,77; calcium 1,08. The results of blood gas analysis were pH 7,09; pCO<sub>2</sub> 9; HCO<sub>3</sub> <3. The urinalysis showed +2 ketonuria, +3 glucosuria, and +1 bacteria. The results of the chest plain X-ray showed mild bilateral pneumonia (figure 2). ECG examination revealed sinus tachycardia 150x/min, T inverted in the lead II, and pathological Q in lead III and

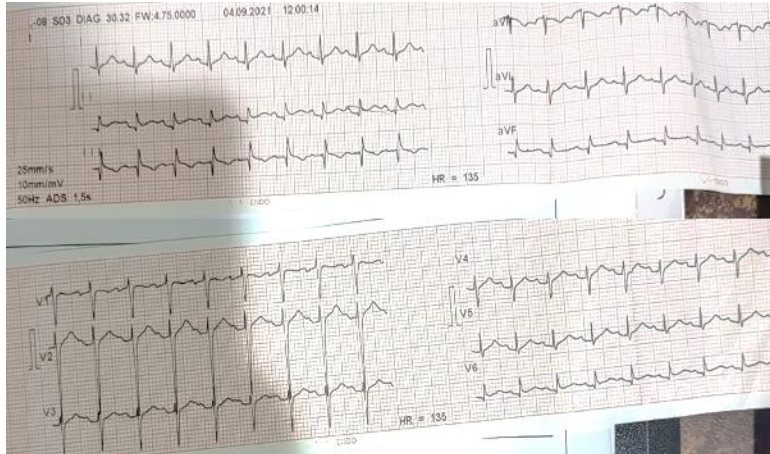
aVF (figure 3). The results of Hs Troponin increased by 15.



**Figure 1.** In the picture of an abscess on the patient's left neck, it looks like pus is coming out of the abscess hole



**Figure 2.** The chest plain X-ray showed mild bilateral pneumonia



**Figure 3.** ECG examination revealed sinus tachycardia 150x/min, T inverted in the lead II, and pathological Q in the lead III and

### TREATMENT

From the examination above, the patient was diagnosed with diabetic ketoacidosis in type 2 DM and NSTEMI (Non-ST elevation Myocardial Infarction), then treated with loading NaCl 0.9% 2000 cc, oxygen nasal cannula three lpm, insulin rapid-acting ten units IV bolus followed by a syringe pump, sodium bicarbonate 50 mEq, levofloxacin IV 750mg/day, ceftriaxone IV 2gram/day, omeprazole IV 40mg/day, ondansetron IV 8mg/8 hours, sucralfate 3x10cc, paracetamol 3x500mg, loading aspirin 180mg, ticagrelor 180mg, ivabradine 5mg, and heparinization using fondaparinux 2,5mg subcutaneously.

### OUTCOME AND FOLLOW-UP

The patient received a follow-up examination plan for FNAB and CT coronary angiography. From the FNAB of the left neck region, the results of acute suppurative inflammation (abscess). Coronary CT angiography revealed severe stenosis of up to 70% of the LAD artery and RPL osteal. The patient then underwent surgical intervention in the form of debridement. The pus product from the neck abscess was then examined for pus culture. After debridement, the patient received empiric antibiotic therapy: meropenem IV 1gr/8 hours, long-acting insulin ten units, and insulin rapid-acting eight units three

times a day. The patient received therapy for heart problems in aspirin 1x80mg, diltiazem 1x200mg, atorvastatin 1x40mg, bisoprolol 1x10mg, and ivabradine five and ramipril 10mg.

Pus culture results were obtained in *Klebsiella pneumoniae* with ceftriaxone-sensitive antibiotic when the patient planned to go home. The patient was hospitalized for eight days and received home medication is of metronidazole 3x500mg, cotrimoxazole 2x960mg, mefenamic acid 3x500mg, omeprazole 2x20mg, long-acting insulin ten units, rapid-acting insulin six units three times a day, ticagrelor 2x90mg, aspirin 1x80mg, diltiazem 1x200mg, atorvastatin 1x40mg, bisoprolol 1x10mg, ivabradine 5mg, and ramipril 10mg. Blood glucose level slowly showed improvement with a final result of 145 mg/dL before the patient was discharged.

### DISCUSSION

Due to decreased neutrophil migratory ability and phagocytic activity, poor humoral immunity, neuropathy, and microangiopathy, T2DM patients are vulnerable to infection<sup>3</sup>. Neck abscesses in T2DM patients are most commonly detected in the parapharyngeal space because the head and neck lymph nodes and main veins are located there. This makes it easy for the upper respiratory tract or odontogenic infections

to spread into this area. Microangiopathy in T2DM might promote the growth of anaerobic bacteria due to a lack of oxygen in peripheral tissues and a decrease in the body's immune system response at the injection site<sup>8</sup>.

Neck abscesses in T2DM frequently have a polymicrobial bacterial pattern. Aerobic *Klebsiella pneumoniae* and *Streptococcus viridans* are the most prevalent bacterial infectious agents. *Klebsiella sp.* has been linked to urinary tract infection (UTI) in diabetic patients<sup>9</sup>. Infection in untreated DM patients can cause complications in the form of DKA. The DKA condition will aggravate the infection process, which will further restrict leukocyte function<sup>4</sup>. In this case, the patient was also diagnosed with pneumonia and a urinary tract infection. These multiple infections may occur due to complications from neck abscesses that cause sepsis<sup>9</sup>. Because the patient is unaware that he has diabetes, the uncontrolled blood sugar levels exacerbated his condition.

Securing the airway, utilizing antibiotic medication, and draining the abscess are the three fundamentals for managing neck abscesses. Prompt surgical intervention will improve the prognosis of neck abscess in DM patients<sup>3</sup>. Drainage and debridement were performed as soon as the tissue biopsy results were acquired in this patient. The abscess was shrinking, and the patient's blood sugar levels were more controlled. The findings of the pus culture investigation revealed that the patient was responsive to ceftriaxone, indicating that this therapy was highly effective as an empiric antibiotic in the patient. In this case, there were no surgical complications.

This patient also had severe stenosis of the LAD and ostial RPL with no chest pain, ECG evolution, or significant troponin elevation. The more extraordinary occurrence of silent myocardial infarction in diabetes patients could be attributed to changes in pain threshold or psychological response. Autonomic neuropathy in cardiac

afferent neurons plays a significant role. In DKA, myocardial infarction is the most common cause of mortality<sup>10</sup>. DKA can worsen arrhythmias and pulmonary edema, in addition to myocardial infarction. H<sup>+</sup> ions exert a depressive impact on the heart in severe acidosis with a pH less than 7.2, causing negative inotropic, bradycardia, reduced cardiac output, peripheral dilatation, and shock<sup>11</sup>. Increased levels of counter-regulatory hormones such as adrenaline, cortisol, and glucagon in DKA/HHS patients without a history of CAD lead to increased myocardial oxygen demand, resulting in supply and demand imbalance and myocardial necrosis<sup>6</sup>. Furthermore, insulin shortage is linked to high levels of free fatty acids and ketone bodies, which impede glucose uptake by cells and result in a lack of energy in the heart, leading to ischemia and even infarction<sup>6</sup>. The treatment of NSTEMI in diabetic patients is based on risk classification; these patients are treated conservatively because they are considered low risk, with beta-blockers, statins, antiplatelets, and anticoagulants being used<sup>12</sup>.

#### LEARNING POINTS/TAKE HOME MESSAGES

- T2DM patients are susceptible to infection due to impaired immunity, neuropathy, and microangiopathy.
- Infection in untreated T2DM patients can cause complications in the form of DKA. Prompt surgical intervention will improve the prognosis of neck abscess in DM patients.
- Differences in pain threshold, the psychological response, and especially autonomic neuropathy in cardiac afferent neurons caused silent myocardial infarction in diabetic patients.

## REFERENCES

1. Prabowo NA, Ardyanto TD, Hanafi M, et al. Peningkatan Pengetahuan Diet Diabetes, Self Management diabetes dan Penurunan Tingkat Stres Menjalani Diet pada Pasien Diabetes Mellitus Tipe 2 di Rumah Sakit Universitas Sebelas Maret. *warta*. 2021;24(2):285-296. doi:10.23917/warta.v24i2.12515
2. Sholihah MM, Kusuma TRH, Hanif MI, Prabowo NA. Letter to the Editor on Type 1 diabetes onset triggered by COVID-19. *Acta Diabetol*. 2021;58(9):1283-1284. doi:10.1007/s00592-021-01761-3
3. Shizuma T, Fukui S, Todoroki K. A Case of Back Abscess and Diabetic Ketoacidosis in a Patient with Type 2 Diabetes Mellitus. *Diabetes Case Reports*. 2017;01(02):2-4. doi:10.4172/2572-5629.1000106
4. Bandyopadhyay D, Devanabanda AR, Tummala R, et al. Effect of diabetic ketoacidosis on the outcomes of ST-elevation myocardial infarction: An analysis of national inpatient sample. *IJC Heart and Vasculature*. 2019;24:100384. doi:10.1016/j.ijcha.2019.100384
5. Corrales-Medina VF, Madjid M, Musher DM. Role of acute infection in triggering acute coronary syndromes. *The Lancet Infectious Diseases*. 2010;10(2):83-92. doi:10.1016/S1473-3099(09)70331-7
6. Kaefer K, Botta I, Mugisha A, et al. Acute coronary syndrome and diabetic keto acidosis: the chicken or the egg? *Annals of Translational Medicine*. 2019;7(16):397-397. doi:10.21037/atm.2019.07.38
7. Kadel A, Thakur KK, Rauniyar BK, Adhikari RB, Limbu D, Malla R. Acute Myocardial Infarction and Diabetic Ketoacidosis: The Lethal Duo. *J Nepal Health Res Counc*. 2021;19(1):212-214. doi:10.33314/jnhrc.v19i1.3193
8. Bhatia M, Fei LW, Cao Y, et al. Pathophysiology of acute pancreatitis. *Pancreatology*. 2005;5(2-3):132-144. doi:10.1159/000085265
9. Guisado-Vasco P, Cano-Megías M, Carrasco-de la Fuente M, Corres-González J, Matei AM, González-Albarrán O. Clinical features, mortality, hospital admission, and length of stay of a cohort of adult patients with diabetic ketoacidosis attending the emergency room of a tertiary hospital in Spain. *Endocrinología y Nutrición*. 2015;62(6):277-284. doi:10.1016/j.endonu.2015.02.003
10. Draman MS, Thabit H, Kiernan TJ, O'Neill J, Sreenan S, McDermott JH. A silent myocardial infarction in the diabetes outpatient clinic: case report and review of the literature. *Endocrinology, Diabetes & Metabolism Case Reports*. 2013;2013(October). doi:10.1530/edm-13-0058
11. Issa M, Alqahtani F, Ziada KM, et al. Incidence and Outcomes of Non-ST Elevation Myocardial Infarction in Patients Hospitalized with Decompensated Diabetes. *American Journal of Cardiology*. 2018;122(8):1297-1302. doi:10.1016/j.amjcard.2018.07.004
12. Dokter P, Kardiovaskular S, Ketiga E. Pedoman Tatalaksana Sindrom Koroner Akut Edisi Ketiga. Published online 2015.