

Published: September, 30, 2022

**Citation:** Masao Tanaka, 2022. Nutcracker Syndrome: A Review of the Current Literature, Medical Research Archives, [online] 10(9). <https://doi.org/10.18103/mra.v10i9.3122>

Copyright: © 2022 European Society of Medicine. This is an open-access article distributed under the terms of the Creative Commons Attribution License, which permits unrestricted use, distribution, and reproduction in any medium, provided the original author and source are credited.

DOI

<https://doi.org/10.18103/mra.v10i9.3122>

ISSN: 2375-1924

## REVIEW ARTICLE

### Nutcracker Syndrome: A Review of the Current Literature

Jaclyn DeRieux, MD<sup>1</sup>; Dina Obed, MD<sup>1</sup>; and Kevin M Casey, MD, FACS\*<sup>1</sup>

<sup>1</sup>Santa Barbara Cottage Hospital, Department of General Surgery, 400 West Pueblo St Santa Barbara, CA 93015

\*[kcasey@sbvascularspecialists.com](mailto:kcasey@sbvascularspecialists.com)

Disclosures: The authors have no conflicts of interest to declare.

#### ABSTRACT

Nutcracker Syndrome is a rare condition secondary to either compression of the left renal vein in its normal anatomic position by the superior mesenteric artery and aorta, or rarely, when the left renal vein is in a retroaortic position, compressed between the aorta and the spine. Left renal vein compression varies widely in presentation and severity, ranging from asymptomatic imaging findings, to chronic pelvic or flank pain. While left renal vein transposition remains the most common management modality, there is growing acceptance for other surgical interventions as well as endovascular treatments—particularly stenting. However, there remains a scarcity of evidence for these less invasive techniques. We conduct a review of the recent literature and discuss the diagnosis and current management strategies for nutcracker syndrome. We also revisit a unique case of nutcracker syndrome in a female patient with a history of chronic pelvic pain and venous congestion wherein transposition of the left renal vein resulted in complete resolution of her symptoms.

## Introduction

Nutcracker syndrome (NCS) is a rare condition caused by the compression of the left renal vein (LRV). It can be divided into two subtypes: anterior nutcracker syndrome (aNCS), characterized by the compression of the LRV between the aorta and superior mesenteric artery, and posterior nutcracker syndrome (pNCS), in which an anomalous retroaortic LRV is compressed between the aorta and the spine. NCS varies widely in presentation and severity, ranging from asymptomatic imaging findings, to chronic pelvic or flank pain, and hematuria.

NCS is typically diagnosed with venography; however, there is no agreed upon gold standard, with ultrasound and intravascular ultrasound (IVUS) also frequently used. Given the rarity of NCS and range of clinical presentations, there lacks consensus regarding the best approach for management. While left renal vein transposition remains the most commonly described treatment, left gonadal vein (LGV) transposition has also seen some success. Although in some institutions it is considered first line treatment, LGV transposition provides an option for salvage treatment for ongoing symptoms following LRV transposition. There are also less invasive treatment modalities that have shown varying degrees of success.

Endovascular treatments are of particular interest, though long-term data is still lacking.

## Case

As previously presented by St. Hilaire *et al*, a 30-year-old female with a history of ulcerative colitis presented with chronic and worsening pelvic and left flank pain.<sup>1</sup> Physical examination revealed mild tenderness to palpation in the left lower quadrant without lower extremity edema or varices. She denied gross hematuria but reported a recent episode of tea-colored urine right before her admission. Laboratory values included normal creatinine (0.72 mg/dL), normocytic anemia (hemoglobin 10.7 g/dL, MCV 89.5 fL). Urinalysis was negative for red blood cells. A computed tomography (CT) scan demonstrated a peripherally dilated retroaortic LRV (Figure 1). A pelvic venogram with isolated LRV and ovarian vein cannulation demonstrated reflux into the dilated left ovarian vein. With and without Valsalva, there was reflux into the left ovarian vein with opacification of cross pelvic collaterals and uterine plexus with subsequent filling of the right ovarian vein and the inferior vena cava (IVC; Figure 2). Pullback pressure gradient from the peripheral left renal vein to the IVC measured greater than 10 mmHg.

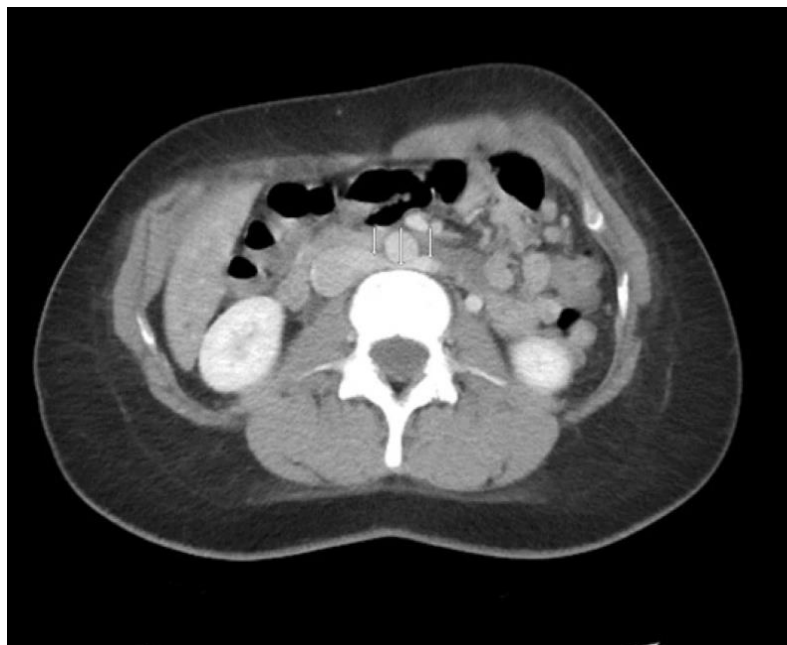

Fig 1: Computed tomography scan demonstrating retroaortic left renal vein (LRV) position.

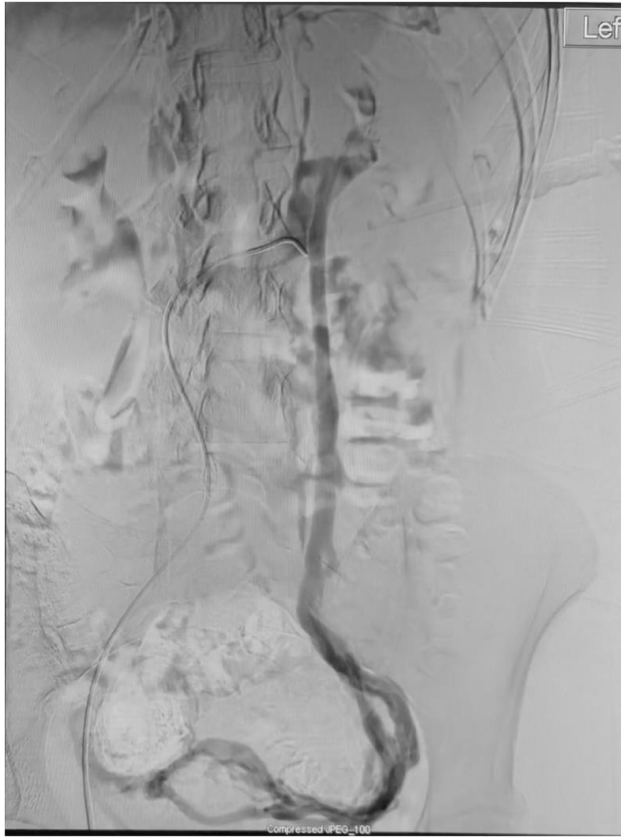


Fig 2: Left renal vein (LRV) venography with reflux into left gonadal vein and across uterine venous plexus.

A midline transperitoneal approach was used to expose the infrarenal aorta. Mobilization of the aorta to allow full exposure of the LRV required ligation of multiple lumbar arteries. The LRV was identified in a significantly caudal trajectory. The exposure and control of the IVC, LRV and aorta prior to transposition is shown in Figure 3. The LRV

was transected at its confluence with the IVC and the IVC venotomy was closed with two-layer running 4-0 monofilament suture. The LRV was then transposed to a more cranial position and an end-to-side anastomosis was performed with 6-0 monofilament (Figure 4). The left gonadal vein was subsequently ligated.

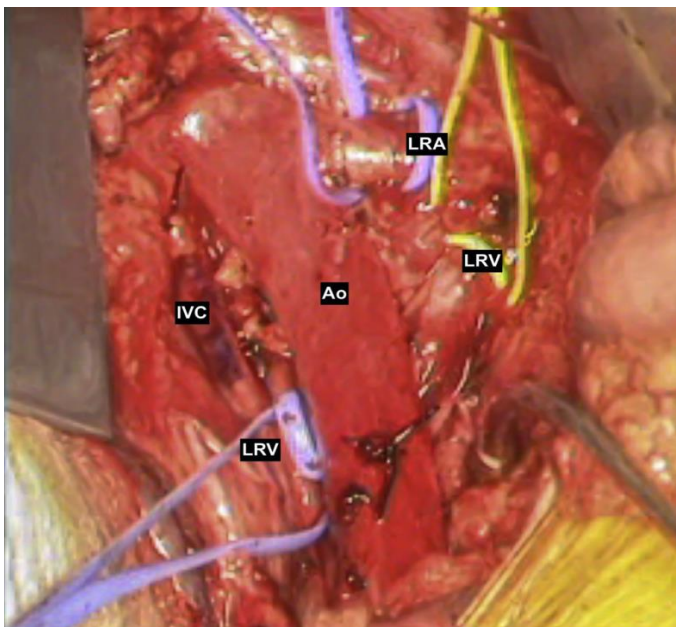


Fig 3: Predivision anatomy. Ao, Aorta; IVC, inferior vena cava; LRA, left renal artery; LRV, left renal vein.

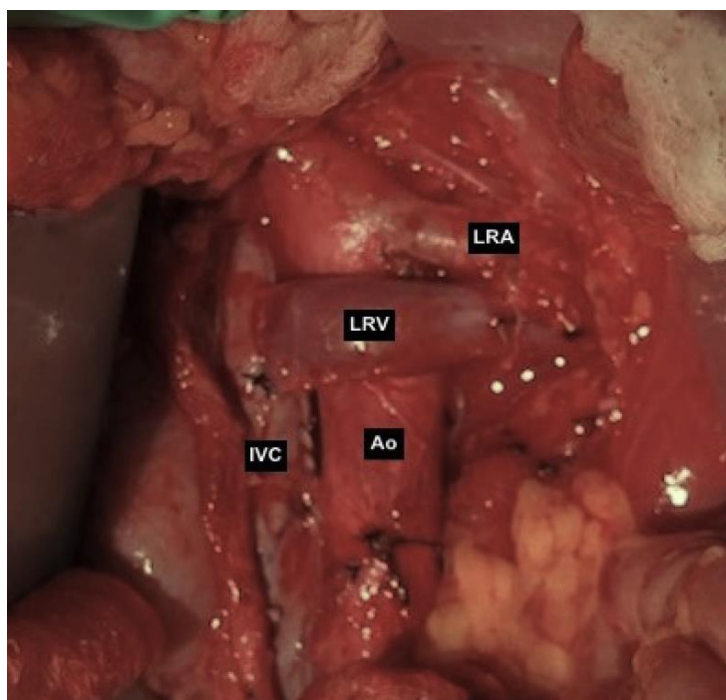


Fig 4: Anatomy after left renal vein (LRV) anterior transposition. Ao, Aorta; LRA, left renal artery; IVC, inferior vena cava.

The patient recovered without complication and was discharged home on postoperative day five with 81 mg acetylsalicylic acid (ASA). At two-month follow-up the patient had returned to work and full activity. She was pain-free and tolerating a normal diet.

#### **Discussion**

In the case presented, the decision was made to proceed with transposition of the LRV due to concern about the durability of endovascular repair in the setting of posterior nutcracker syndrome, in which case any stent placed would be chronically compressed against the spine. While LRV transposition is commonly regarded as the gold standard for treatment of NCS, several alternate approaches have been described, with varying success reported.<sup>2</sup> Additionally, no consensus guidelines exist which delineate clear diagnostic criteria for NCS, or indications for surgical intervention.

#### **Diagnosis**

The term NCS is reserved for symptomatic LRV compression, while asymptomatic LRV compression found incidentally on imaging is described as “Nutcracker Phenomenon”. The constellation of presenting signs and symptoms varies widely and is in part dependent on patient age and sex. Generally, men report varicoceles, while pain and pelvic congestion are more common in women.<sup>3</sup> Because the most common signs and symptoms (left flank/abdominal pain and

hematuria) are nonspecific, a thorough workup must be performed to exclude more common etiologies in all patients. There is no standardized diagnostic criterion for venography or imaging. Overall, invasive testing is rarely necessary, and NCS may be diagnosed in a patient with clinical suspicion corroborated by imaging findings. Venography with pressure measurements is the most sensitive diagnostic test, with a gradient of  $>2\text{mmHg}$  between the LRV and IVC being suggestive of NCS in symptomatic patients.<sup>4</sup> IVUS, commonly employed in the evaluation of other venous compression syndromes, may aid in diagnosis but has not been validated in NCS.<sup>4</sup> However, some studies report superior sensitivity with IVUS compared to venography alone (90% vs 62%).<sup>5</sup> Duplex ultrasound, while operator-dependent and limited by body habitus and anatomic position of the LRV, is typically used for initial screening. The diagnosis is suggested by LRV appearance and measurement of the aortomesenteric angle (AMA), with an AMA of less than  $16^\circ$  corresponding with compressive symptoms.<sup>6</sup> In cases where ultrasound is technically limited or inconclusive, CT or MR venography may better assess the degree of LRV compression and extent of collaterals.<sup>4</sup>

#### **Treatment**

Many treatment approaches for NCS have been described, with varying success rates reported. The optimal timing and technique is debated, but should be guided by patient anatomy

and the severity and nature of presentation. Initial trial of conservative management with observation, compression stockings, and increased physical activity is encouraged. This is particularly important for pediatric and minimally symptomatic patients, with invasive approaches reserved for those with severe or progressive symptoms.<sup>7</sup> To date, there are no society consensus guidelines to inform management of NCS, and the existing literature is largely limited to small retrospective studies and case reports.

Left renal vein transposition is the most widely described technique, and is considered the gold standard for surgical management of NCS. Recent case series report up to 80% symptom resolution for transabdominal, transperitoneal approaches.<sup>8</sup> Transposition of the LRV provides a durable improvement, while minimizing renal ischemic time and number of anastomoses. Small retrospective studies also suggest LRV transposition is the optimal repair for pNCS for ease of exposure and questionable durability of endovascular repair in the setting of external compressive force, however data is limited due to its exceeding low incidence.<sup>9</sup> Retroperitoneal, extraperitoneal approaches which minimize bowel manipulation have been shown to reduce hospital LOS and ileus compared to transperitoneal approaches in limited case studies.<sup>10</sup> For both approaches, the rate of overall complications, including restenosis or occlusion and DVT, is low (18%).<sup>11</sup>

Transposition of the left gonadal vein (LGV) for NCS with primarily pelvic symptoms has been described in several modest retrospective reviews and is even the first line intervention in some institutions. In this approach, the LGV is reimplanted into the common or external iliac vein, or the IVC below the IMV, leaving the LRV in situ. Debucquois *et al* report a sevenfold reduction in patient-reported pain score following LGV transposition, with 18% of patients requiring early revision and additional 18% with late complications including thrombosis or stenosis.<sup>11</sup> Other series report at least partial symptom relief in 80% of patients, with complete resolution in 61%, and no reported reinterventions.<sup>12</sup> Like LRV transposition, retroperitoneal approaches have demonstrated durable results with faster return of bowel function and improved cosmesis in small case series.<sup>13</sup> LGV has been proposed as either a first line option or salvage for persistent symptoms following LRV transposition for all NCS patients with LGV diameter sufficient for reimplantation, though male and pNCS patients are underrepresented in existing studies.

While LRV, and to a lesser extent, LGV transposition have been the favored surgical strategies for NCS for the past several decades, less common open surgical approaches are also employed. Other vessel transposition techniques for LRV decompression, such as superior mesenteric artery transposition, are largely historical and are not addressed in this review. Renocaval bypass, in which the great saphenous vein (GSV) is anastomosed proximally to the IVC below the LRV and distally to the LRV, has been proposed to alleviate LRV congestion. While this technique offers the advantages of partial clamping and avoids ligation of the LRV, LGV, or lumbar veins, current data is very limited at this time.<sup>14</sup> Alternatively, prosthetic graft may be used if satisfactory vein conduit is not available.<sup>15</sup> Nephrectomy, described with or without auto implantation, is the most radical surgical intervention for NCS and is almost exclusively limited to refractory cases.<sup>2</sup>

More recently, endovascular interventions have been applied to increasingly broad clinical indications and patient populations for NCS. As is seen in the setting of other vascular pathologies, these minimally invasive approaches confer significant advantages in the appropriate patient, offering an attractive alternative to conventional open surgical techniques. LRV stenting, with self-expanding nitinol or WALLSTENT (Boston Scientific; Natick, MA) most commonly described, has shown promise in recent small series and case reports as an effective first line treatment for NCS. The largest of these, a retrospective review of 61 patients, reports resolution or improvement in one third of patients at 6 months, while some smaller studies report at least partial improvement in all patients.<sup>16</sup> LRV stenting has particularly gained traction in the treatment of symptomatic pediatric and adolescent NCS patients who have failed conservative management, with >90% success rates reported in some studies, though several patients required multiple interventions.<sup>17</sup> Current data suggest endovascular approaches are associated with shorter LOS and operative time, decreased renal congestion, and decreased ileus.<sup>2,16</sup> However, stent migration into the IVC, renal hilum, or right atrium has been reported in up to 6.7%, with recurrence or stent restenosis requiring additional intervention occurring in 16%.<sup>17,18</sup>

For patients with NCS and resultant left gonadal vein (LGV) reflux (diagnosed either by transvaginal/extra-abdominal duplex ultrasound or venography), selective LGV embolization has been shown to improve pelvic congestion symptoms in up to 98%.<sup>2,19</sup> Typically LGV embolization is combined with LRV stenting to improve pelvic and

lower limb varicosities. However, in certain patients—specifically those without severe hematuria or lumbar pain—LGV embolization has been used as a first line, singular treatment without need for secondary intervention.<sup>20</sup> Data for singular LGV embolization is unfortunately limited to case series at this time.

Hybrid approaches, combining LRV transposition and stenting, have also been described, but again data is limited to case studies.<sup>21</sup> While endovascular treatment of NCS appears to be effective in select patients, long term data is lacking, and many groups, including men and pNCS patients, are underrepresented in the existing literature. To date there are no trials directly comparing endovascular techniques to conventional open approaches for NCS.

Additional minimally invasive approaches have been developed in recent years, including extravascular stenting. Robotic and laparoscopic deployment of a PTFE stent to encase the LRV and prevent external compression is described in limited single surgeon series and case studies. Pain relief was reported in all cases, though resolution of other symptoms was variable.<sup>22,23,24</sup> In the vast majority, data is limited to one month follow-up, however, one group described placement of a 3D printed titanium alloy stent, tailored to patient anatomy, with no residual symptoms at two years.<sup>25</sup> Notably,

for patients included in these studies, mean BMI was <20, which may reflect increased incidence of NCS in the setting of decreased visceral fat, though more data is needed to determine the durability, effectiveness, and generalizability of these methods for broader populations.

### **Conclusion**

NCS is a rare but important cause of chronic pelvic pain. Presenting signs and symptoms are nonspecific, and heightened clinical suspicion is needed to avoid misdiagnosis. To date, there are no consensus guidelines to advise the work up or treatment of NCS, which reflects the paucity of large prospective trials with long term follow up. As such, management strategies must be tailored to individual patient presentations and anatomy. While promising alternative approaches to conventional open LRV transposition have been described in recent years, the durability of and generalizability of these techniques to broader patient populations is uncertain given the existing gap in the literature. Notably, males and pNCS patients are underrepresented. This raises potential concern about the effectiveness of more novel treatments, particularly in the setting of pNCS, where the LRV is compressed against the spine. Further research is warranted to delineate the optimal surgical approach for treatment of NCS.

**References:**

1. St. Hilaire C, Paisley M, Greene J, Casey KM. Left renal vein transposition for posterior nutcracker syndrome. *Journal of Vascular Surgery Cases, Innovations and Techniques*. 2021;7(2):243-246. doi:10.1016/j.jvscit.2021.02.016
2. Macedo GL, Santos MA, Sarris AB, Gomes RZ. Diagnosis and treatment of the Nutcracker syndrome: a review of the last 10 years. *Jornal Vascular Brasileiro*. 2018;17(3):220-228. doi:10.1590/1677-5449.012417
3. Ananthan K, Onida S, Davies AH. Nutcracker Syndrome: An update on current diagnostic criteria and management guidelines. *European Journal of Vascular and Endovascular Surgery*. 2017;53(6):886-894. doi:10.1016/j.ejvs.2017.02.015
4. Chait J, Sen I, Kalra M. Nutcracker Syndrome: How to diagnose it and when/how should it be treated in the pelvic venous disease population. *Techniques in Vascular and Interventional Radiology*. 2021;24(1):100734. doi:10.1016/j.tvir.2021.100734
5. Kim KW, Cho JY, Kim SH, et al. Diagnostic value of computed tomographic findings of Nutcracker Syndrome: Correlation with renal venography and renocaval pressure gradients. *European Journal of Radiology*. 2011;80(3):648-654. doi:10.1016/j.ejrad.2010.08.044
6. de los Reyes T, Keefe DT, Rickard M, Lorenzo AJ. Diagnosis and therapeutic strategies for Nutcracker Syndrome. *Current Opinion in Urology*. 2020;31(2):135-137. doi:10.1097/mou.0000000000000831
7. Miró I, Serrano A, Pérez-Ardavín J, et al. Eighteen years of experience with pediatric nutcracker syndrome: The importance of the Conservative approach. *Journal of Pediatric Urology*. 2020;16(2). doi:10.1016/j.jpuro.2019.12.003
8. Velasquez CA, Saeyeldin A, Zafar MA, Brownstein AJ, Erben Y. A systematic review on management of Nutcracker Syndrome. *Journal of Vascular Surgery: Venous and Lymphatic Disorders*. 2018;6(2):271-278. doi:10.1016/j.jvsv.2017.11.005
9. Park JH, Lee GH, Lee SM, et al. Posterior nutcracker syndrome – a systematic review. *Vasa*. 2018;47(1):23-29. doi:10.1024/0301-1526/a000670
10. Greenspan J, Szczerepa D, Trocha K, Rao A, Fluss G, Finlay D. A novel approach for the treatment of Nutcracker Syndrome: A case report. *Annals of Vascular Surgery*. 2022;79. doi:10.1016/j.avsg.2021.07.046
11. Debucquois A, Salomon du Mont L, Bertho W, Kaladji A, Hartung O, Rinckenbach S. Current results of left gonadal vein transposition to treat nutcracker syndrome. *Journal of Vascular Surgery: Venous and Lymphatic Disorders*. 2021;9(6):1504-1509. doi:10.1016/j.jvsv.2021.03.003
12. Gilmore BF, Benrashid E, Geersen D, Shortell CK. Gonadal vein transposition is a safe and effective treatment of nutcracker syndrome. *Journal of Vascular Surgery: Venous and Lymphatic Disorders*. 2021;9(3):712-719. doi:10.1016/j.jvsv.2020.09.002
13. White JV, Ryjewski C. A simplified surgical approach for left ovarian vein transposition for the treatment of pelvic venous disease from nutcracker syndrome. *Journal of Vascular Surgery Cases, Innovations and Techniques*. 2021;7(3):411-414. doi:10.1016/j.jvscit.2021.05.008
14. Macedo GL, Santos MA, Sarris AB, Gomes RZ. Venous revascularization to treat posterior nutcracker syndrome by transposition of the left gonadal vein: case report. *Jornal Vascular Brasileiro*. 2019;18. doi:10.1590/1677-5449.190037
15. Zhang X, Wang S, Wei J. Prosthetic left renocaval bypass for posterior nutcracker syndrome. *Indian Journal of Surgery*. 2014;77(S1):103-105. doi:10.1007/s12262-014-1180-9
16. Chen S, Zhang H, Shi H, Tian L, Jin W, Li M. Endovascular stenting for treatment of nutcracker syndrome: Report of 61 cases with long-term followup. *Journal of Urology*. 2011;186(2):570-575. doi:10.1016/j.juro.2011.03.135
17. Avgerinos ED, Saadeddin Z, Humar R, et al. Outcomes of left renal vein stenting in patients with nutcracker syndrome. *Journal of Vascular Surgery: Venous and Lymphatic Disorders*. 2019;7(6):853-859. doi:10.1016/j.jvsv.2019.06.016
18. Wu Z, Zheng X, He Y, et al. Stent migration after endovascular stenting in patients with nutcracker syndrome. *Journal of Vascular Surgery: Venous and Lymphatic Disorders*. 2016;4(2):193-199. doi:10.1016/j.jvsv.2015.10.005
19. Bookwalter CA, VanBuren WM, Neisen MJ, Bjarnason H. Imaging appearance and nonsurgical management of pelvic venous congestion syndrome. *RadioGraphics*. 2019;39(2):596-608. doi:10.1148/rg.2019180159
20. Leal Monedero J, Zubicoa Ezpeleta S, Perrin M. Management of left renal vein compression in patients presenting left gonadal vein reflux. *Phlebology: The Journal of Venous Disease*. 2017;33(7):475-482. doi:10.1177/0268355517723992

21. Stawiarski K, Wosnitzer M, Erben Y. A novel hybrid left renal vein transposition and endovascular stenting technique for the treatment of posterior nutcracker syndrome. *Journal of Vascular Surgery Cases, Innovations and Techniques*. 2017;3(3):142-145. doi:10.1016/j.jvscit.2017.04.003
22. Steinberg RL, Johnson BA, Garbens A, Cadeddu JA. Robotic assisted extravascular stent placement for Nutcracker phenomenon of the left renal vein: A case series. *Journal of Robotic Surgery*. 2020;14(5):781-788. doi:10.1007/s11701-020-01054-x
23. Lin JC, Ranasinghe B, Patel A, Rogers CG. Robot-assisted laparoscopic placement of extravascular stent for nutcracker syndrome. *Journal of Vascular Surgery Cases, Innovations and Techniques*. 2020;6(3):346-347. doi:10.1016/j.jvscit.2020.03.013
24. Policha A, Lamparello P, Sadek M, Berland T, Maldonado T. Endovascular treatment of nutcracker syndrome. *Annals of Vascular Surgery*. 2016;36. doi:10.1016/j.avsg.2016.04.005
25. Guo YT, Wang H, Wang JP, Zhang B. Two-Year Follow-up on Laparoscopic Three-Dimensional Printed Extravascular Stent Placement for Posterior Nutcracker Syndrome. *Chin Med J (Engl)*. 2018;131(23):2895-2896. doi:10.4103/0366-6999.246075
26. Belczak SQ, Coelho Neto F, de Araújo WJ, Godoy JM. Endovascular treatment of anterior nutcracker syndrome and pelvic varices in a patient with an anterior and a posterior renal vein. *BMJ Case Reports*. 2020;13(9). doi:10.1136/bcr-2020-235284
27. Cronan JC, Hawkins CM, Kennedy SS, Marshall KW, Rostad BS, Gill AE. Endovascular management of Nutcracker Syndrome in an adolescent patient population. *Pediatric Radiology*. 2021;51(8):1487-1496. doi:10.1007/s00247-021-04986-0
28. Chen Y, Xing J, Liu F. Left renal vein transposition is effective for posterior nutcracker syndrome. *Int J Clin Exp Med*. 2014;7(12):5925-5927. 2014 Dec 15.