

Published: November 30, 2022

Citation: Narayansingh G, Cawich SO, et al., 2022. FreeHand Robot-Assisted Gynecologic Surgery in Trinidad & Tobago: Case Reports, Medical Research Archives, [online] 10(11). <https://doi.org/10.18103/mra.v10i11.3324>

Copyright: © 2022 European Society of Medicine. This is an open-access article distributed under the terms of the Creative Commons Attribution License, which permits unrestricted use, distribution, and reproduction in any medium, provided the original author and source are credited.

DOI
<https://doi.org/10.18103/mra.v10i11.3324>

ISSN: 2375-1924

CASE REPORT

FreeHand Robot-Assisted Gynecologic Surgery in Trinidad & Tobago: Case Reports

Gordon Narayansingh¹, Shamir O. Cawich^{*1}, Tan Arulampalam², Ahsanul Haq³, Ramdas Senasi⁴

1. Department of Surgery, Port of Spain General Hospital, Port of Spain, Trinidad & Tobago
2. Department of Surgery, Anglia Ruskin University, Colchester General Hospital NHS Trust, United Kingdom
3. Department of Surgery, Lancashire Teaching Hospital NHS Trust, United Kingdom
4. Department of Surgery, South Tyneside and Sunderland HNS Trust, United Kingdom

* socawich@hotmail.com

Data Availability: The raw data in this study can be accessed from the corresponding author upon request.

Acknowledgements: No further acknowledgements are necessary.

Authors' Disclosure Statements: The authors have no disclosures

Funding Statement: No funding was made available for this research.

ABSTRACT

Background: Minimally invasive surgery is still at a relatively early stage throughout the Anglophone Caribbean and robotic surgery has been largely non-existent. There have been many unique obstacles to the introduction of robotic surgery in the Caribbean.

Methods: We present a case report to document the initial experience with the use of the FreeHand surgical robot during gynecologic operations in Trinidad & Tobago.

Results: Two cases are presented to highlight the use of the FreeHand robot for gynecologic operations. We outline our experiences introducing the FreeHand® robotic arm to facilitate minimally invasive gynecologic surgery in the Caribbean.

Conclusions: The FreeHand® system is a good intermediary between conventional laparoscopy and a full surgical robot. We believe this technology can be incorporated into the armamentarium of gynecologic surgeons in resource-poor nations, once there is appropriate training and intra-operative mentoring from experts familiar with the technology.

INTRODUCTION:

The Anglophone Caribbean is still in the early stages of its laparoscopic surgery experience since advanced laparoscopy only gained firm footing around the year 2010.¹⁻⁵ The first documented robot-assisted operation in the English-speaking Caribbean using the FreeHand® (Freehand 2010 Ltd., Guildford, Surrey, UK) robotic arm was performed on September 15, 2021 at the Port of Spain General Hospital in Trinidad & Tobago.⁶ Since then, the repertoire of cases has broadened with several general surgical, urologic and hepatobiliary operations using the FreeHand® system.

To the best of our knowledge, the first FreeHand® robot-assisted gynecologic operation in the Caribbean was performed on December 2, 2021 in Trinidad & Tobago. We report our initial experience to demonstrate that robot-assisted gynecologic surgery is feasible in this environment and to share the lessons learned during this experience.

METHODS:

Trinidad & Tobago is a small island nation with a population of approximately 1.4 million persons, located in the Eastern Caribbean.¹ In this nation, laparoscopic gynaecologic operations are performed regularly,⁷⁻⁸ but robotic surgery has been non-existent before 2021. As a result of a

public-private partnership, a FreeHand® (Freehand 2010 Ltd., Guildford, Surrey, UK) robotic arm was made available in Trinidad & Tobago in 2021, but there was poor buy-in by the surgical community.

In this paper we provide a descriptive case report on the initial experience using the FreeHand® (Freehand 2010 Ltd., Guildford, Surrey, UK) robotic arm to perform laparoscopic gynecologic operations in Trinidad & Tobago. We also present a brief review and discuss the lessons learned during this experience.

CASE REPORTS:

We report two cases in which the FreeHand® (Freehand 2010 Ltd., Guildford, Surrey, UK) robotic arm was used to perform laparoscopic gynecologic operations. In both cases we used a 12 mm visual port at the umbilicus. The robotic arm was secured to the operating table and operated a 10mm thirty-degree laparoscope through this umbilical port (figure 1). The 5mm working ports were placed at varied locations to maximize triangulation for dissection. The FreeHand® Robotic Arm was fully controlled by the operating surgeon using an infrared communication device fixated on a headpiece (figure 1). The robotic arm provided six degrees of movement under control of the surgeon using head motions.

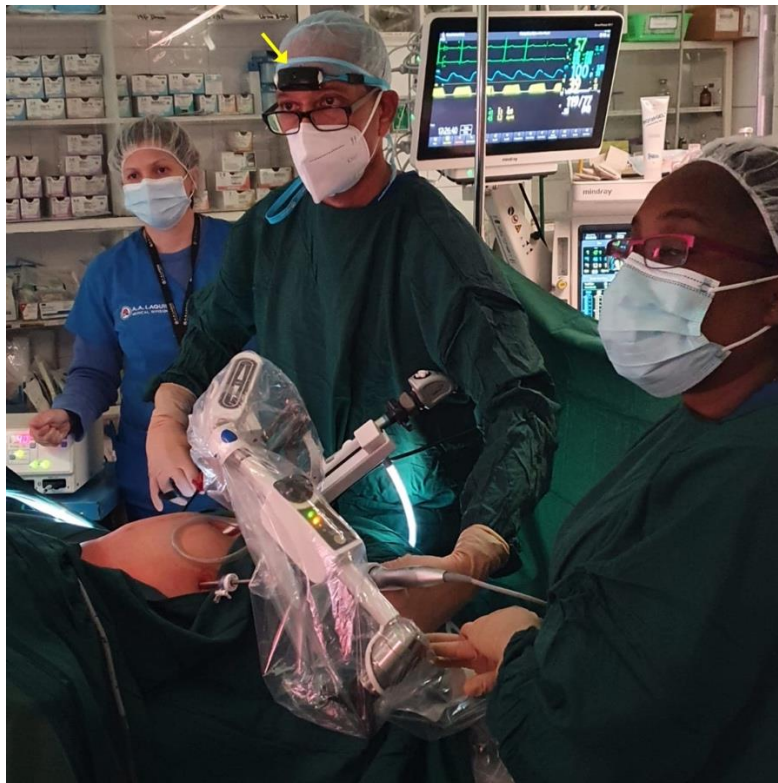


Figure 1: A view of the operative field during a FreeHand® robot-assisted hysterectomy. The surgeon wears a headband to control the robotic arm via an infrared communicator (arrow). The robotic arm is seen in situ controlling the laparoscope via the umbilical port while the surgeon uses both hands to control laparoscopic instruments.

Our first patient was a 45-year-old woman with a left hydrosalpinx, multiple uterine fibroids and a ventral hernia. She underwent Freehand® robot-assisted left salpingo-oophorectomy, myomectomy and ventral hernia repair on

December 2, 2021. The specimens were removed via a 5cm Phannesteil incision. This operation lasted 120 minutes, with 100mls blood loss. This patient was discharged from hospital on day-3 post operation and had an uneventful recovery.

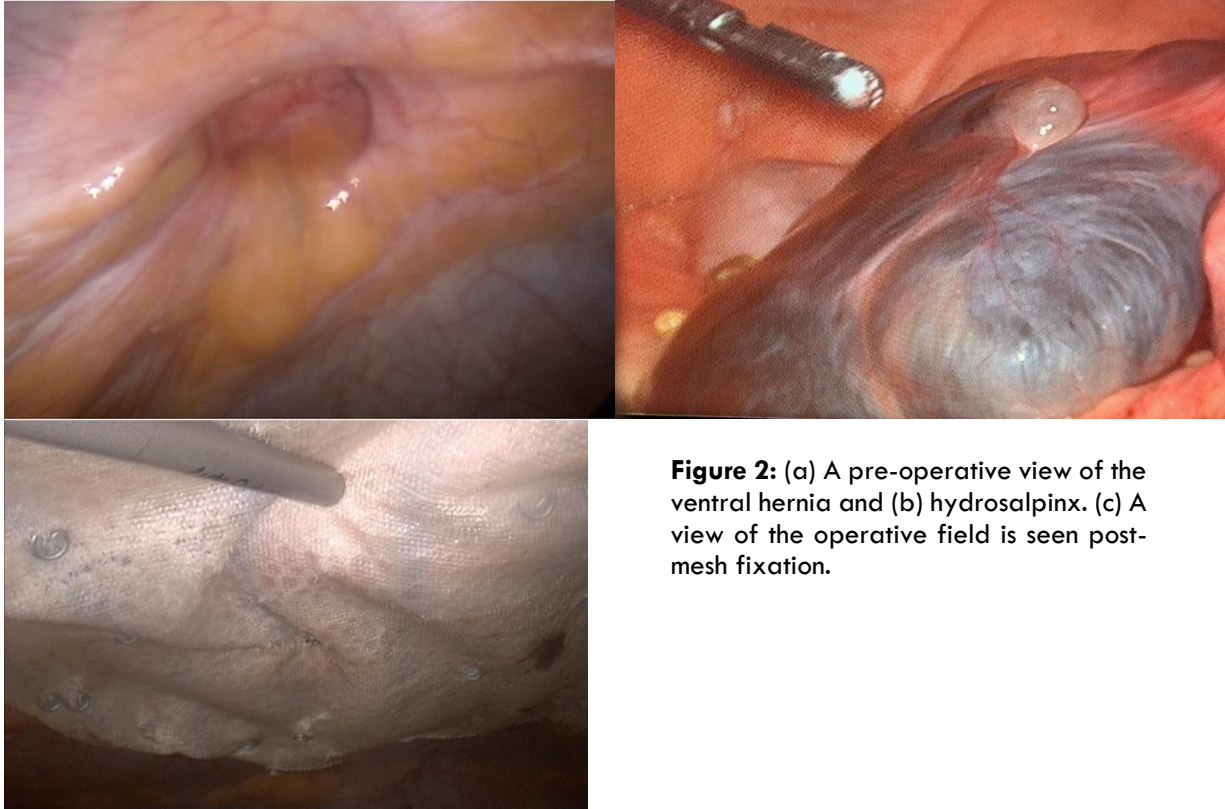


Figure 2: (a) A pre-operative view of the ventral hernia and (b) hydrosalpinx. (c) A view of the operative field is seen post-mesh fixation.

Our second patient was a 43-year-old woman with a one-year history of chronic pelvic pain due to uterine fibroids and first-degree uterine descent. She underwent FreeHand® robotic laparoscopic hysterectomy, left salpingo-oophorectomy and utero-sacral ligament plication

on December 9, 2021 (Figure 3). The procedure lasted 90 minutes and was associated with less than 100 mls blood loss Postoperative recovery was uneventful and she was discharged less than 24 hours later.

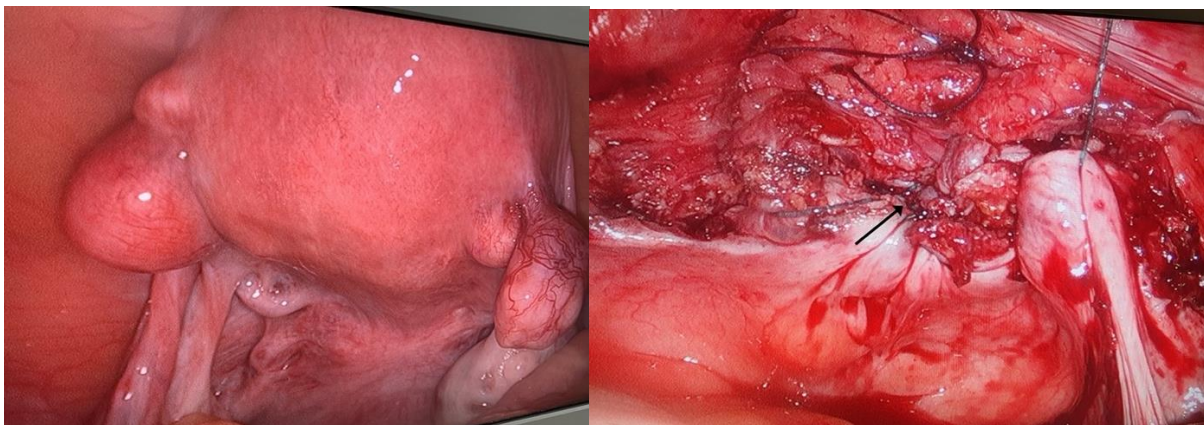


Figure 3: (a) A pre-operative view of the uterus with multiple fibroids and (b) view of the operative field post-hysterectomy. The vaginal vault was closed with sutures (arrow)

DISCUSSION:

Minimally invasive approaches to gynecologic surgery were revolutionized in the year 2000 with the United States Food and Drug Administration approval of the DaVinci platform.⁹ Over the past two decades, surgical robots have been used increasingly in a variety of gynecologic operations.¹⁰⁻¹³ The rapid adoption of robotic gynecologic surgery over conventional laparoscopy was largely due to increased degrees of freedom of instrument movement, tremor filtration and improved three-dimensional optics.¹⁰⁻¹³ These advantages translated into improved clinical outcomes, including reduced hospitalization, return to normal activity and overall morbidity.¹⁴⁻¹⁵

But robotic surgery was non-existent in the Anglophone Caribbean prior to the year 2021, although it was popular in developed countries.⁹⁻¹³ We previously noted that there were 4 reasons for the slow adoption of robotic surgery in the Anglophone Caribbean: (1) manufacturers of robotic systems were unwilling to invest in the resource-poor setting, (2) these low-to-middle income nations were not able to afford expensive surgical robots, (2) these island nations have populations that are too small to sustain the necessary case load and (4) established MIS surgeons have become fierce opponents of robotics.

Despite these, surgical leaders recognized the need for technical advancement and we have been able to overcome most of these obstacles.¹⁸⁻¹⁹ The main reason that distributors were reluctant to supply robotic equipment to the Caribbean was that most were low-income countries, including some of the poorest countries in the Western Hemisphere.¹⁶ From a business perspective, these companies may have thought that these poor nations would not be able afford the hardware and necessary consumables.

However, we were able to identify a suitable and relatively inexpensive robotic arm and then engage the distributor to supply the equipment in the Caribbean. The FreeHand® robotic arm (Freehand 2010 Ltd., Guildford, Surrey, UK) does not have the capacity to control surgical instruments that a full surgical robot such as the da Vinci system (Intuitive Surgical Ltd., Sunnyvale, California, USA) would have.¹⁷ It is a single robotic arm designed to control the laparoscope via infrared signals from the surgeon. However, we found it to be a good intermediary between traditional multiport laparoscopy and a full surgical robotic system.

Although the Caribbean region has a large cumulative population of 7.5 million persons, each of the 17 independent nations have small individual populations.⁶ This created the potential for

insufficient case volumes to make the robot economically feasible. However, the system has gained traction since the first case on September 15, 2021,⁶ and has been used for robot-assisted cholecystectomies, bile duct explorations, liver resections, pancreatic resections, prostatectomies, hemi-colectomies, funduplications and ventral hernia repairs. It is important to note that we have achieved cross-specialty stakeholder buy-in so it can be used for a wider range of cases with larger volumes. With continued use, we expect that there will be increased buy in from surgeons as well as patient demand.

The FreeHand® (Freehand 2010 Ltd., Guildford, Surrey, UK) system puts the surgeon in full control of the visual field, eliminating human error by the camera person.⁶ We found the steady and controlled view particularly beneficial in closure of the vaginal cuff and plicating the uterosacral ligaments. We found the head movement to control the robot easy to learn, simple to perform and not distracting to the surgeon while controlling the operating instruments. We believe that the robotic arm can support the ease of performing other laparoscopic gynecological surgical procedures since there is a concentrated field within the pelvis requiring little adjustment.

The FreeHand® (Freehand 2010 Ltd., Guildford, Surrey, UK) system was also of value to us in the “new-normal” pandemic era operating room because it allowed operations to proceed with reduced staff numbers, preventing viral spread. Prior to embarking on these operations, the surgeons underwent training and received intra-operative mentoring from experts familiar with the technology. With these precautions, the surgeon was able to complete a variety of robot-assisted laparoscopic gynaecologic operations with a similar safety profile to conventional laparoscopy. We hope that our experience will motivate gynecologic surgeons in the Caribbean to support further development of robotics.

CONCLUSION:

We have demonstrated that robot-assisted gynecologic surgery is feasible in the Caribbean. Although many commercial robots are available, we believe that the FreeHand® system is a good intermediary between conventional laparoscopy and a full surgical robot. Therefore, we believe this technology can be incorporated into the armamentarium of gynecologic surgeons in resource-poor nations, once there is appropriate training and intra-operative mentoring from experts familiar with the technology.

REFERENCES:

1. Naraynsingh V, Bahadursingh S, Maharaj R, Harnarayan P, Cawich SO. Surgery in the West Indies: A Perspective from Trinidad. *Current Med Res Prac.* 2014; 4: 126-129.
2. Cawich SO, Pooran S, Amow B, et al. Impact of a Medical University on Laparoscopic Surgery in a Service-Oriented Public Hospital in the Caribbean. *J Risk Manag Healthc Policy.* 2016;9:1-8
3. Parker M, Ramdass MJ, Cawich SO, FaSiOen P, Rosin D. A Historical Perspective on the Introduction of Laparoscopic Basic Training in the Caribbean and Factors that Contribute to Sustainability of Such Training. *International J Surg.* 2019; 72: 6-12.
4. Wilson C, Cawich SO, Simpson LK, Baker AK. Starting a Laparoscopic Surgery Service in a Rural Community Hospital in Jamaica: Successes and Challenges of the Percy Junor Hospital Experience. *Caribb Med J.* 2014; 76(1): 8-11.
5. Cawich SO, Kluger MD, Francis W, et al. Review of minimally invasive pancreas surgery and opinion on its incorporation into low volume and resource poor centres. *World J Gastrointest Surg.* 2021; 13(10): 1122-1135
6. Cawich SO, Arulampalam T, Senasi R, Naraynsingh V. Robot-Assisted Minimally Invasive Surgery: First Report from the Caribbean. *Cureus.* 2021; 13(10): e18739.
7. Bahall V, DeBarry L. Laparoscopic management of a true broad ligament leiomyoma in a patient with advanced endometriosis and a solitary kidney: A case report and literature review. *Case Rep Womens Health.* 2022; 36: e00436
8. Narayansingh G, Hoh J. The eventual successful management of ovarian torsion in a hyperstimulated ovary following in vitro fertilization: A case report. *Case Rep Womens Health.* 2020; 26: e00166
9. Ashrafian H, Clancy O, Grover V, Darzi A. The Evolution of Robotic Surgery: Surgical and Anaesthetic Aspects. *Brit J Anaesth.* 2017; 119(1): 72-84.
10. Specchia ML, Arcuri G, DiPilla A, LaGatta E, et al. The value of surgical admissions for malignant uterine cancer. A comparative analysis of robotic, laparoscopic, and laparotomy surgery in a university hospital. *Front Public Health.* 2022; 10: 920578
11. Lundin ES, Carlsson P, Wodlin NB, Nilsson L, Kjölhede P. Cost-Effectiveness of robotic hysterectomy versus abdominal hysterectomy in early endometrial cancer. *Int J Gynecologic Cancer.* 2020; 30:1719-25.
12. Marino P, Houvenaeghel G, Narducci F, et al. Cost-effectiveness of conventional vs robotic-assisted laparoscopy in gynecologic oncologic indications. *Int J Gynecologic Cancer.* 2015; 25:1102-8.
13. Maggioni A, Minig L, Zanagnolo V, et al. Robotic approach for cervical cancer: comparison with laparotomy. *Gynecol Oncol.* 2009; 115:60-4.
14. Ind T, Laios A, Hacking M, Nobbenhuis M. A comparison of operative outcomes between standard and robotic laparoscopic surgery for endometrial cancer: a systematic review and meta-analysis. *Int J Med Robot.* 2017; 13:e1851.
15. Lim PC, Kang E, Park DH. Learning curve and surgical outcome for robotic-assisted hysterectomy with lymphadenectomy: case-matched controlled comparison with laparoscopy and laparotomy for treatment of endometrial cancer. *J Minim Invasive Gynecol.* 2010; 17:739-48.
16. Mahabir AH, Ramkissoon SCK, Thomas DA, Cawich SO, Naraynsingh V, Dapri G. An Evaluation of Horizontal Equity in Surgical Care for Gallstone Disease in a Caribbean Country. *Curr Med Res Prac.* 2021; 11 (2): 83-87
17. Lane T. A Short History of Robotic Surgery. *Ann R Coll Surg Engl.* 2018; 100 (6): 5-7.
18. Cawich SO, Singh Y, Naraynsingh V, Senasi R, Arulampalam T. Freehand-robot-assisted laparoscopic colorectal surgery: Initial experience in the Trinidad and Tobago. *World J Surg Proced.* 2022; 12(1): 1-7
19. Cawich SO, Harnarayan P, Maharaj R, et al. A Survey of Surgical Trainees in Trinidad & Tobago Using a Robotic Laparoscopic Camera Holder. *Medical Research Archives.* 2022; 10(8): 1-4.