

**Running head: 3D Facial Reconstruction From A Skull Of A Female Who Buried and Bound Using Hog-Tie; Found In Excavations At Aktopraklik, Bursa-Turkey Is 8500 Years Old**

3D Facial Reconstruction from a Skull of a Female Who Buried and Bound Using Hog-Tie;  
Found In Excavations at Aktopraklik, Bursa-Turkey is 8500 Years Old

Bora Boz, Mehmet ZahitSarıtaş, Ali Boz

Pamukkale University

Author Note

Bora Boz and Mehmet ZahitSarıtaş, Department of Forensic Science, Faculty of  
Medicine, Pamukkale University, Denizli Turkey.

Ali Boz, Pamukkale University TecnoPark, Electrical and Electronic Engineer, Denizli  
Turkey.

Correspondence concerning this article should be addressed to Bora Boz, Pamukkale  
University Faculty of Medicine, Department of Forensic Science, 20100, Denizli, TURKEY. E-  
mail: [bboz@pau.edu.tr](mailto:bboz@pau.edu.tr)

3D Facial Reconstruction From A Skull Of A Female Who Buried and Bound Using Hog-  
Tie; Found In Excavations At Aktopraklik, Bursa-Turkey Is 8500 Years Old

**ABSTRACT**

There are many excavation centres in Anatolia, most combining international and national teams. Facial reconstruction has been done for many purposes, from forensic medicine to surgical requirement. Recently, it has become favourable in historical findings. Although there are a few techniques for face construction, ethnicity, geography, and age of the skeleton should be taken into account. The aim of this case report is to make a facial reconstruction using a different approach, using soft tissue thickness that specifically belongs to the Anatolian people. In the present study, a face is defined using four steps to reach a more accurate construction for Anatolians. First, a skeleton was examined, then soft tissue thickness determined by predefined-MRI pool data, followed by x-ray computed tomography of the skull, and finally, computer aided correction. At the end of this protocol, the face was reconstructed in the best way. Also, for the first time, it was printed using a 3D printer for further analysis and display. The skeleton was found in Aktopraklık-Bursa (West Anatolia) excavation. The skull was aged about 8500 years old, gender determined as female. All measurements of the whole skeleton and facial reconstruction showed high similarities to the people who lived in this region in history.

**Key Words:** forensic science, anthropology, facial reconstruction, 3D printer, Aktopraklık, Anatolia

3D Facial Reconstruction From A Skull Of A Female Who Buried and Bound Using Hog-Tie; Found In Excavations At Aktopraklık, Bursa-Turkey Is 8500 Years Old

**Introduction:**

Many different historic findings, mostly coins, jewellery, implements, and inscriptions, as well as sculptures, are displayed to people in museums. However, skeletal findings, especially human, are generally stocked in rear rows, without interest. Facial reconstruction is gaining popularity and recently historical skull work has become favourable. Facial reconstruction is important for many areas, especially forensic medicine (Wozniak, Moskala, Pohl, Latacz, Dybala, 2012).

Previously, many studies have made possible identifications of face (Miyasaka,1999). There are three methods for face construction: American (by tissue thickness), Russian (by muscles), and Manchester (combination of tissue and anatomical) (Sever, 2007). The mostly used Manchester and Gerosimov techniques use clay that is harmful to skull and bone structures (Çağdır, 1997 &

Clement, Marks, 2005 & Wilkinson, 2004 &Boz, Özdemir, Özer, Boz, 2012). A recent

advancement in face construction is the computerized 3D face construction technique (Claes, Vandermeulen, Greef, Willems, Suetens, 2006). Ethnicities, geography, biological and historical age of the sample are very important parameters for determining the protocol and accurate reconstruction of a face. Routine and general techniques could be done, but special attention should be given to historical skeletons.

Archaeological findings can help in understanding historical homicide, execution, and religious rituals. Hence, among the many skeletal findings, this hog-tied case was preferred as it had already been aged and anthropometrical measurements were done.

The aim of this case report is to make a facial reconstruction using the measurements of the Anatolian peoples and 3D scanning and printing technique coded by special software.

3D Facial Reconstruction From A Skull  
Of A Female Who Buried and Bound

Using Hog-Tie; Found In Excavations  
At Aktopraklik, Bursa-Turkey Is 8500  
Years Old

### **Material and Methods:**

#### **Excavation Area**

Aktopraklik mound is located west and at 25 km distance from Bursa and the east side of Ulubat Lake (Figure 1). The mound has been excavated by a team led by NecmiKarul since 2004 (Karul, Özeren,2007). The mound has three settlement areas (A, B, and C) and has very important traces of Neolithic and Chalcolithic periods. The settlement, which was unearthed in the oldest ruins, dates back to the year 6500 BC (Budd, 2013).

#### **Skeleton and facial construction**

Many skeletons have been found in the ruins of settlements. Some have been buried in interesting positions. One skeleton has forensic interest because it is buried and bound using hog-tie (Figure 2) at area C. The skeleton was aged by isotop analysis (Budd 2013). Gender of the skeleton detected as female by standard anthropometric measurement.

In the first step, the head of the skeleton was examined by a forensic

medicine specialist; naked eyes and pieces missing from the incomplete cranium were reconstructed by hand (Iscan, Helmer, 1993). In the second step, the skull was scanned transversally by computer tomography (Philips Brilliance CT 16 V2.00) and dicom files transferred to computer (Figure 3). In the third step, soft tissue thickness data obtained from the local population were applied virtually on pc, with ten different points defined on the cranium (Table 1) (Figure 4) (Teke, 2010). In the fourth step, fine corrections were carried by manually using Blender version V2.74 (Photo 3).

Finally, virtual data were embodied by 3D printer (Zortrax M200) using Acrylonitrile butadiene styrene (ABS)) plastic (Photo 5).

3D Facial Reconstruction From A Skull  
Of A Female Who Buried and Bound  
Using Hog-Tie; Found In Excavations  
At Aktopraklik, Bursa-Turkey Is 8500  
Years Old

### **Results:**

Face construction was completed (Fig 4) and 3D printing applied to both

Forensic medicine and archaeology. A 3D printed sample of the skull was given to the excavation team to display in Bursa Archaeopark.

### **Discussion**

For reconstructions of faces upon skulls, reconstructions are usually based on a meticulous anthropological and anatomical analysis of the particular skeletal remains (Setefan, Henneberg, 2001 & Prag, Neave, 1997 & Mays, 1998 ). From these observations the importance of fine tuning average anthropological values of soft-tissue thickness appropriate for that region of the face and for that particular set of remains can be assessed (Vincent, 2001). Facial tissue thickness is affected by age, gender, and factors related with environmental, ethnic, and genetic differences (Midori, Ricanek, 2008). Therefore, it is important to have a large series of data from each community,

measuring facial soft tissue thickness with scientific methods. Facial thickness data from the Ankara Sample was used (Teke, 2010). These data were more reasonable for the Bursa region. The study provided the opportunity to try many types of skin, eyes, hair and other aspects on the 3D reconstructed face. 3D printing is very useful without disturbing the original findings and can be used widely in forensic, orthopaedic, educational and historical examinations as well as art exhibitions.

### **Acknowledgements**

We thank to Assoc Prof Dr Necmi Karul (Istanbul University, Prehistory Department) for providing excavation area, skeleton finding permission and related data, also we thank to Prof Dr Ibrahim Acikbas (Pamukkale University, Faculty of Medicine) for help writing and editing our manuscript.

**References;**

- Boz, B., Özdemir M. B., Özer, A., Boz, A., (2012). Processing of facial reconstruction from skull: ABAB method (new model). *Int J Legal Med*, 126.
- Budd, C., Lillie, M., Alpaslan-Roodenberg, S., KARUL, N., Pinhasi, R., (2013). Stable isotope analysis of Neolithic and Chalcolithic populations from Aktopraklık, northern Anatolia. *Journal of Archaeological Science*: 40(2), 860-867.
- Claes, P., Vandermeulen, D., Greef, S.D., Willems, G., Suetens P., (2006). Craniofacial reconstruction using a combined statistical model of face shape and soft tissue depths: Methodology and validation. *Forensic SciInt*, 159, 147–158.
- Clement, J.G., Marks, M. K., *Computer Graphic Facial Reconstruction*, (2005). Elsevier.
- Çağdır, A. S. (1997). *Kimlik Tespitinde Fasiyal Rekonstruksiyonun Yeri, Tıpta Uzmanlık Tezi, Adli Tıp Kurumu Başkanlığı, İstanbul.*
- Iscan, M. Y., & Helmer R. P. (eds.), (1993). *Forensic Analysis of the Skull*. Wiley-Liss, New York, 199-213.
- Karul, N., Özeren. Ö., (2007). *Aktopraklık Höyüğü Kazı Çalışmaları, Türk Eskiçağ Bilimleri Enstitüsü. Haberler 23, İstanbul, 19-20.*
- Mays, S., (1998). *The Archaeology of Human Bones*. Routledge, London and New York.
- Midori, A. A., Ricanek, K. J., (2008). The Morph Database: Investigating the effects of adults craniofacial aging on automated Face-Recognition Technology, *Forensic Science Communications*, 10, 2.
- Miyasaka, S., (1999). *Progress in Facial Reconstruction Technology*. *Forensic Science Review* 11(1), 51–90. Central Police University Press, Kashiwanoha, Japan, NRIPS.
- Prag, J., & Neave, R., (1997). *Making Faces: Using Forensic and Archaeological Evidence*. Butler and Tanner Ltd, London.
- Sever, M., (2007). *Adli antropoloji: Yeniden yüzlendirme çalışmalarında mevcut yüz muşak dokükalınlık cetvellerinin Türkiye’de*

## Medical Research Archive

3D Facial Reconstruction From A Skull Of A Female Who Buried and Bound Using Hog-Tie; Found In Excavations At Aktopraklik, Bursa-Turkey Is 8500 Years Old

gulanabilirliđi, Yayınlanmamış Yüksek Lisans Tezi, Ankara Üniversitesi, Ankara .

Stefan, C. N., & Henneberg, M., (2001). Building faces from dried skulls: are they recognised above chance rates. *J. Forensic Sci*, 46, 432–440.

Teke, H. Y. et al., (2010). Assesment of the thickness of face soft tissue using magnetic resonance: Ankara sample. *Adli Tıp Dergisi*, 24-3, 24–36.

Wilkinson, C., (2004). Forensic facial

reconstruction. Cambridge University Press, Cambridge. Vincent, M. P., (2001). Skeletal remains identification by facial reconstruction. *Forensic Science Commuications*, 3, 1.

Woźniak, K., Woźniak, E. R., Moskała, A., Pohl, J., Latacz, K., Dybała, B., (2012) Weapon identification using antemortem computed tomography with virtual 3D and rapid prototype modeling—A report in a case of blunt force head injury, *Forensic SciInt*, 222, 29-32

**Table 1:** Soft tissue thickness data obtained from central

AGE	* POINT	FEMALE Mean (mm)	MALE
30-40	1 Right porion	7,65	8,70
	2 Right medial canthus	3,03	5,30
	3 Superior labial margin	13,09	10,80
	4 Inferior labial margin	13,22	14,10
	5 Midphiltrum	15,32	15,80
	6 Left medial canthus	2,92	4,70
	7 Left porion	7,98	8,90
	8 Beneath chin	9,47	9,60
	9 Chin-lip fold	1026	12,00
	10 Inion	12,48	14,40

Anatolian people were used on cranium at ten different points (9).

\*The numbers represented on figure 3.



Figure 2 The skeletons in burial.

Figure 2 legend:

The photograph represents a section of the burial excavation. Four skeletons have been found by Karumet al.in the burial: an adult woman, man and two child skeletons. Two adults have been positioned back to back hands tied at back suggesting a possible sacrifice cult. Each child's skeleton has been positioned between the adults' legs, buried separately. Because the four skeletons were unearthed at different depth levels and for other reasons, a photograph of all four skeletons together could not be obtained.

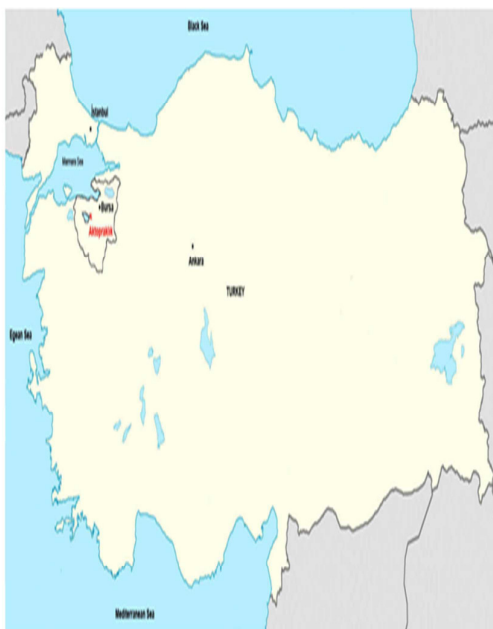

Figure 1 Excavation area on map.



3D Facial Reconstruction From A Skull Of A Female Who Buried and Bound Using Hog-Tie; Found In Excavations At Aktopraklik, Bursa-Turkey Is 8500 Years Old

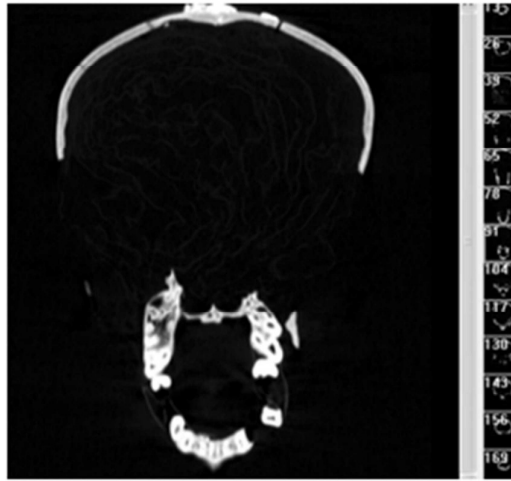


Figure 3 Scanned image of the skull.

Figure 4 Used points showed in skull and digitally completed face construction

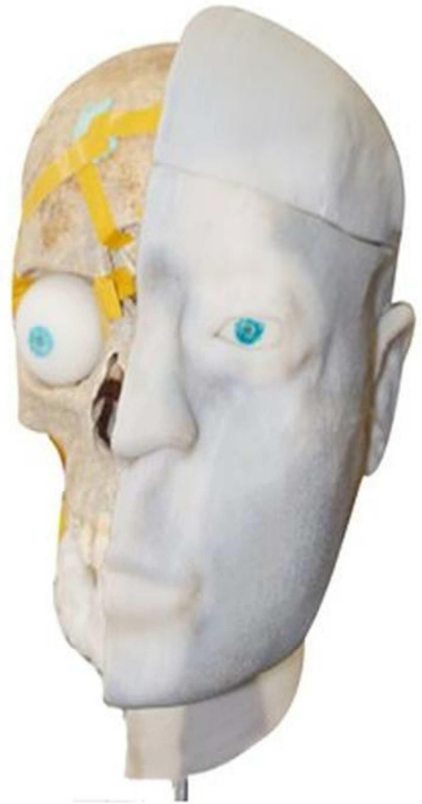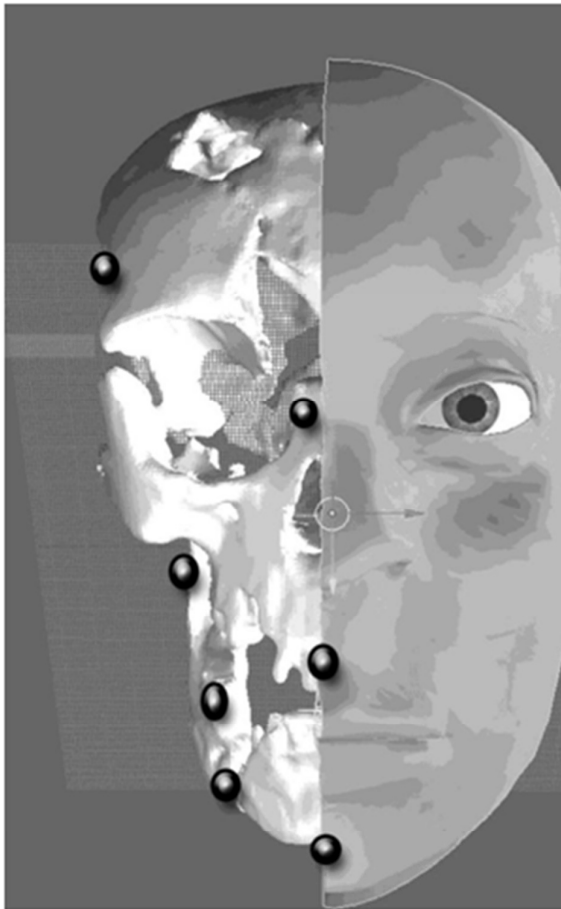


Figure 5. Half of the re contracted face printed as 3D.