

Published: July 31, 2023

**Citation:** Valle ACV and de Carvalho AC, 2023. Long-Term Survival of a Dog With Hepatocellular Carcinoma Under Treatment with *Viscum Album* – Case Report, Medical Research Archives, [online] 11(7). <https://doi.org/10.18103/mra.v11i7.2.4090>

Copyright: © 2023 European Society of Medicine. This is an open-access article distributed under the terms of the Creative Commons Attribution License, which permits unrestricted use, distribution, and reproduction in any medium, provided the original author and source are credited.

DOI  
<https://doi.org/10.18103/mra.v11i7.2.4090>

ISSN: 2375-1924

## CASE REPORT

### Long-Term Survival of a Dog With Hepatocellular Carcinoma Under Treatment with *Viscum Album* – Case Report

Ana Catarina Viana Valle<sup>1\*</sup> and Aloísio Cunha de Carvalho<sup>1</sup>

<sup>1</sup>Doctor Izao Soares Institute, Integrative Medicine, Ribeirao Preto, SP, Brazil.

\*Corresponding author: [dranacatarina@gmail.com](mailto:dranacatarina@gmail.com)

#### ABSTRACT

Hepatocellular carcinoma is the most common liver neoplasm in dogs and can be treated by the *Viscum album* therapy in a curative or palliative way. The objective is to report a hepatocellular carcinoma case in a dog treated by homeopathic therapy, extending to Palliative Care, with a 24-month survival. A 12-year-old Schnauzer male with a history of a liver nodule was treated by intravenous and subcutaneous applications of *V. album* in different dynamization and combinations, chemotherapy, and oral homeopathic medicines. The tumor growth was controlled, and the health condition of the patient was stable while the medication was given as prescribed. However, as application frequency was reduced, tumor growth increased, and health deterioration was verified. Nevertheless and contrary to expectations, the patient had a 24-month survival. Therefore, these findings point to the potential of *V. album* on enhancing the quality of life, controlling tumor growth, and prolonging survival in patients with hepatocellular carcinoma. Patients under continuous treatment would benefit better from these properties.

**Keywords:** Complementary Therapy, Hepatocellular carcinoma, *Viscum album*

## Introduction

Hepatocellular carcinoma (HCC) is the most common liver neoplasm in dogs (Liptak et al., 2004). Prognosis and treatment options for HCC are related to tumor morphology and histology (Withrow et al., 2013), factors directly linked to tumor behavior. In general, the treatment of choice is surgery with resection of the affected lobe. Tumors on the left side tend to be less aggressive than tumors on the right side (Liptak et al., 2004; Withrow et al., 2013; Chevallier et al., 2015). The average survival of animals after lobectomy is greater than 300 days (Chevallier et al., 2015).

Cancer is a disease dependent on the stage at which it is diagnosed. It has a complex treatment, and often no supportive therapy helps improve the quality of life of cancer patients until death (Valle et al., 2020). Within this context, Palliative Care begins to be taken seriously, and homeopathic therapy has effectively helped in the treatment of different oncological diseases (Valle & Carvalho, 2021a, 2021b).

In particular, the *V. album* therapy has been used to treat cancer patients for over 100 years within the principles of anthroposophical medicine (Valle et al., 2021). However, this medicine must not be administered daily due to its inflammatory potential when applied on consecutive days. In contrast, the *V. album* manufactured using homeopathic pharmaceuticals reduces the direct inflammatory potential and can be given daily to patients. Extensive literature supports that this medicine is safe to be administered to any patient and/or age, always seeking to improve the patient's quality of life (Valle et al., 2021; Carvalho, 2015).

This article aims to report the case of a dog diagnosed with hepatocellular carcinoma, treated by homeopathic therapy, extending to palliative care, and with a 24-month survival.

## Case Report

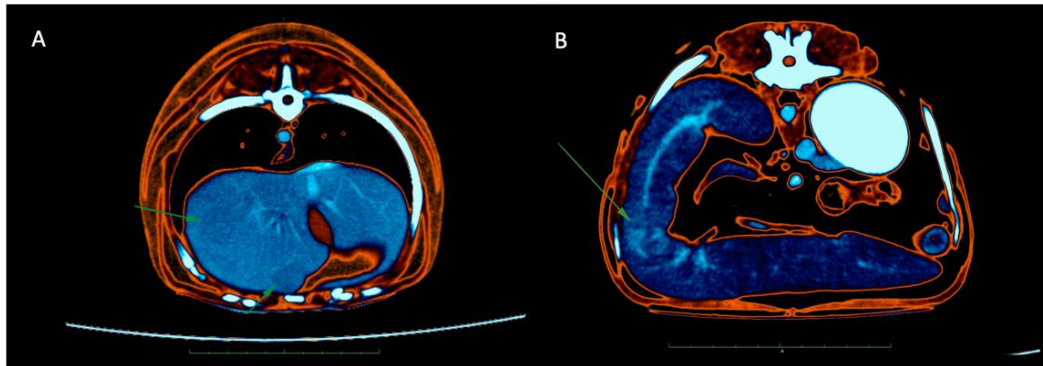
A 12-year-old Schnauzer, male, unneutered, weighing 8.9kg, and with a history of a liver nodule, was seen at NaturalPet Clinic (May/2018) in Brasília, Brazil. The patient underwent computed tomography in March/2018 (Figure 1A) with subsequent left hepatic lobectomy followed by splenectomy. In April/2018, tumor recurrence was visualized and diagnosed at the abdominal ultrasound (US) in the right lobe. The tutor reported that the oncologist in charge of the case, who performed the surgery and was going to initiate the chemotherapy treatment, decided not to start chemotherapy under these conditions since tumor recurrence was observed 30 days after

surgery. The result of the histopathological analysis was clear cell hepatocellular carcinoma (Figure 2). On physical examination, the animal was active and alert, with normal colored mucosa, TPC 2", cardiac auscultation within the expected normal for age and species, a respiratory rate slightly increased, T = 37.5 °C, submandibular lymph nodes slightly enlarged in size, mild discomfort in the right abdominal region. Normal appetite, water intake, urination, and defecation were reported. Blood was collected for complete blood count and biochemical dosages of alanine aminotransferase (ALT), aspartate aminotransferase (AST), alkaline phosphatase (PA), urea, creatinine, total proteins and fractions, cholesterol, and triglycerides. Treatment was instituted using complementary therapies. The homeopathic medicine *V. album* (V) was daily prescribed in the dynamizations D3, D6, D9, D12, and D30, as follows: Day 1 – VD3 + VD6; Day 2 – VD9 + V12; Day 3 – VD30 + VD3; Day 4 – VD6 + VD9; Day 5 – VD12 + V30. The following medicines were prescribed for oral administration: curcumin 60 mg + piperine 40 mcg, SID; Vitamin D3 1000 IU, SID; *Phosphorus* 30CH + *Taraxacum* 30CH, three drops, SID; Curcumin 80 mg + Piperine 80 mcg, one capsule; Omega 3 1000 mg, one capsule, SID; Probiatiop® (probiotic), one sachet, two times a day. The treatment was prescribed continuously, and the animal would have to return to the clinic once a week for intravenous application of *V. album* and one session of chromotherapy (Purple light) located in the anatomical region of the liver.

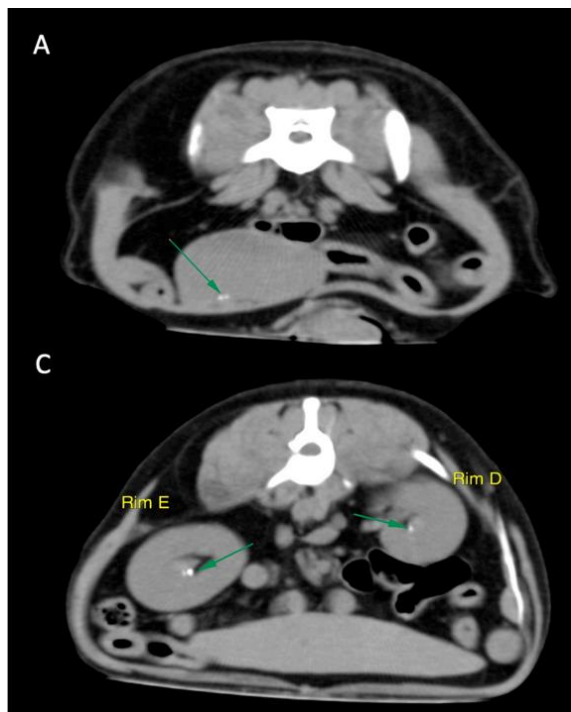
## Follow up

Contrasted Computed Tomography (March/2018) – Thorax: suggestive of a focal area of consolidation in the right cranial lobe that can correlate with an anesthetic process, focal inflammatory/infectious process, or neoplastic process. Abdomen: hepatic neoformations (Figure 1A), followed by lymph node enlargement of hepatic lymph nodes, splenomegaly (Figure 1B), possible pancreatic enlargement (pancreopathy), urinary bladder lithiasis and tenuously heterogeneous prostate (Figure 2A), bilateral renal lithiasis (Figure 2B), as described above. Two isodense neoformations with poorly defined limits and slightly low-uptake contrast were observed. They were located in the topography of the left medial (2.34 cm height, 2.41 cm width, and 0.92 cm length) and lateral (3.56 cm height, 1.72 cm width, and 1.80 cm length) lobes of the liver. Four hepatic lymph nodes with mild/moderate increase in volume and heterogeneous contrast uptake were present. The largest of them measures about 1.4 cm

in diameter. They make intimate contact and possible compression with the left pancreatic lobe.



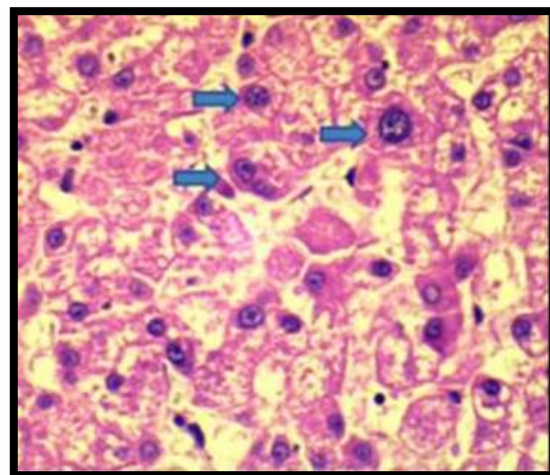
**Figure 1.** A) Two isodense neofomations with poorly defined limits and slightly low-uptake contrast located in the topography of the left medial and lateral lobes of the liver. B) Enlarged spleen with heterogeneous contrast uptake, showing hyper-uptake, amorphous, and poorly delimited areas.



**Figure 2.** A) Presence of small structure mineralized in the interior of the urinary bladder. B) Orthotopic kidneys, with normal volume, presenting attenuation and homogeneous enhancement. Presence of mineralized structures in the interior of both renal pelvises.

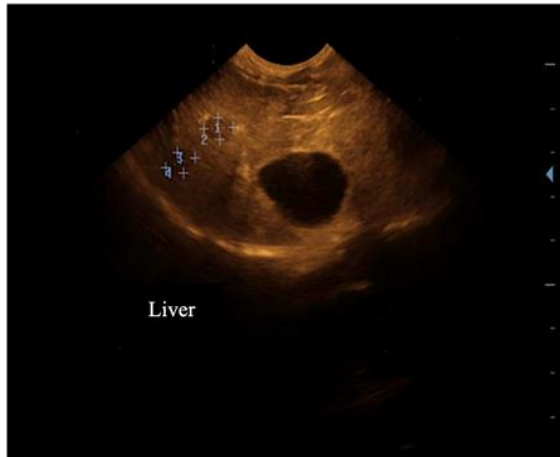Histopathology - performed prior to the first veterinary appointment at Naturalpet Clinic. The result was clear cell hepatocellular carcinoma (Figure 3). Approximately 90% of the analyzed tissue was affected by neoplastic, hypercellular, homogeneous, non-demarcated, non-encapsulated, and infiltrative lesion. The lesion was arranged in cohesive blocks resulting in the loss of the periportal and centrilobular regions in addition to the

definition of the sinusoids. Pleomorphism was moderate, with mitosis 10 fields/400x. The vessels were free of neoplastic cells, but the margins were compromised.



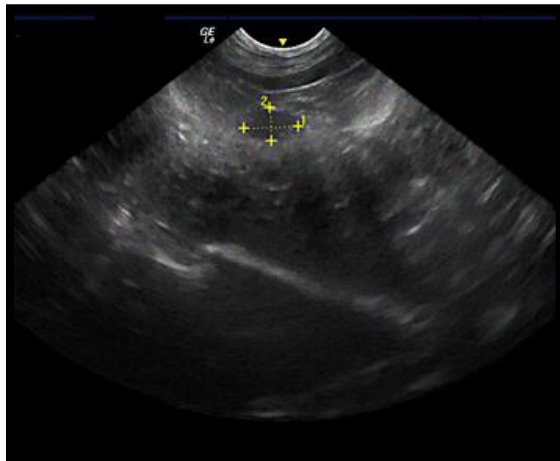
**Figure 3.** Hepatocellular Carcinoma. Blue arrows indicate moderate pleomorphism.

Abdominal ultrasound (US) (June/2018) - Liver: preserved dimensions within the costal arch, regular contour, homogeneous parenchyma, normoechoic except for two well-defined hypoechoic, concentric nodules located in the medial lobe and measuring: 0.81 x 0.50 and 0.84 x 0.50 cm (Figure 4). Preserved liver vessels. Preserved bile ducts. Gallbladder: full, wall of normal and regular thickness, anechoic content. There is no evidence of echogenic biliary sediment (biliary mud). No image suggestive of gallstone was visualized.



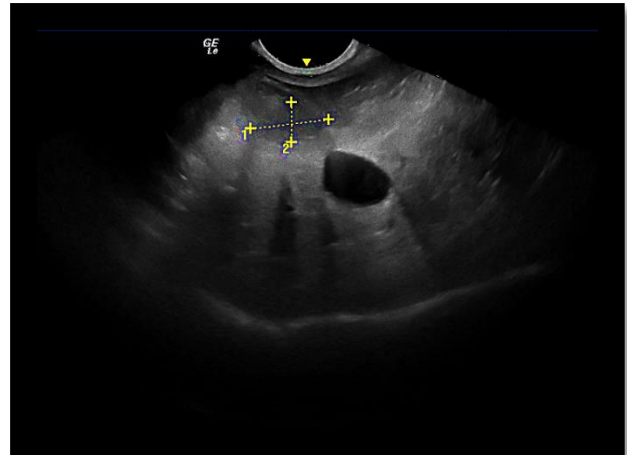
**Figure 4.** Presence of two nodules in the liver parenchyma indicated in 1.2 and 3.4.

Abdominal US (October/2019) – Liver: dimensions within the rib cage limits, tapered margins, smooth surface, echogenicity within normal standards, heterogeneous, presence of oval area, iso/hypoechoic, located on the left side and measuring 1.18 cm x 0.72 cm (Figure 5). Preserved portal and intrahepatic vascular architecture in terms of caliber and path of vessels. Gallbladder: full, thin and echogenic walls, with anechoic and homogeneous content.



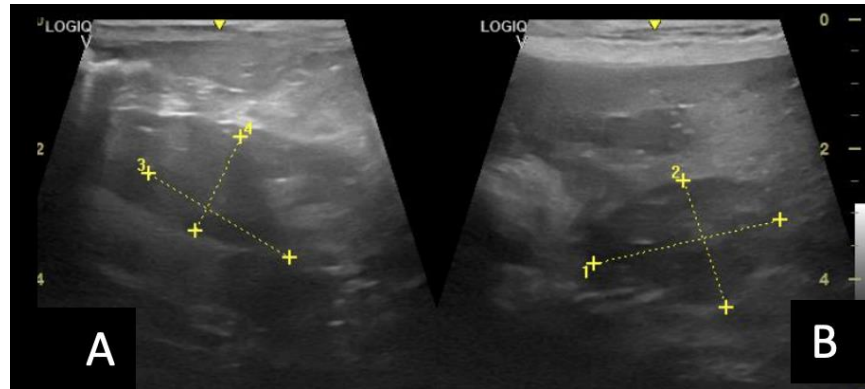
**Figure 5.** Nodule (indicated in yellow) measuring 1.18 cm x 0.72 cm, located on the left side of the liver.

Abdominal US (December/2019) - Liver: dimensions exceeding the rib cage limit, rounded margins, smooth surface; heterogeneous, hyperechoic, irregular parenchyma, and coarse echotexture. Presence of nodular, round, and multifocal lesions, isoechoic to the parenchyma. The largest lesion, measuring 1.72 x 0.87 cm, was located in the left lateral topography (Figure 6). Preserved portal and intrahepatic vascular architecture in terms of caliber and path of vessels. Gallbladder: full, thin and echogenic walls, with anechoic and homogeneous content.



**Figure 6.** Nodule (indicated in yellow) measuring 1.72 x 0.87 cm, on the left side of the liver.

Abdominal US (May/2020) - Liver: in usual topography, defined contour, smooth surface, and sharp edges. Preserved dimension, heterogeneous echotexture, and mixed echogenicity. Presence of nodular lesions, amorphous, hyper and hypoechoic, with poorly defined contour. The largest nodular lesion, measuring approximately 2.93 cm x 2.06 cm (Figure 7B), diffuse in the liver parenchyma. Uniform Doppler perfusion. Gallbladder: in usual topography, defined contour, smooth surface, and regular mucosa. Wall of preserved echogenicity and thickness, with moderate repletion by anechoic fluid.



**Figure 7.** A) Presence of nodule in the left liver parenchyma measuring 2.67 cm x 1.8cm. B) Presence of nodule in the right liver parenchyma measuring 2.93 cm x 2.06 cm.

**Table 1.** Results of blood count tests and biochemical measurements performed on the patient between May/2018 and May/2020.

	May 04/18	Sept. 27/18	Dec. 10/18	Apr. 11/19	Oct. 14/19	Dec. 18/19	May 20/20
Erythrocytes (uL)	5,000,000	5,160,000	5,160,000	5,180,000	5,510,000	6,220,000	5,120,000
Hemoglobin (g/dL)	11.8	13.1	13.0	13.2	13.2	14.3	12.6
Hematocrit (%)	30.6	36.7	36.9	37.5	37.5	41.1	32.9
MCV (g/dL)	62.43	65.42	66.41	65.06	68.09	66.08	61.43
MCHC (g/dL)	32.37	35.69	35.42	35.20	35.20	34.74	32.24
Leukocytes (uL)	5,600	10,100	11,200	8,900	13,800	14,600	9,000
Eosinophils (uL)	113	202	***	***	828	438	210
Lymphocytes (uL)	690	1,414	1,210	801	1,104	2,044	890
Platelets (uL)	534,000	667,000	607,000	751,000	780,000	759,000	789,000
TPP (g/dL)	6	6.8	6.6	7.4	8	8.8	9
ALT (U/L)	180	188	182	108	115	111	180
Creatinine (mg/dL)	1.5	1.21	1.09	0.92	0.61	1.26	1.35
AP (U/L)	145	136	120	205	228	434	534
Urea (mg/dL)	62	58	45	60	34	23	54

The patient was monitored weekly at the veterinary clinic for five months. During this period, his parameters remained continuous, within the normal range, and his temperature remained between 38.4 and 38.8 °C. After this period, the tutor requested that the medication be administered only at home, subcutaneously, due to her difficulty attending the clinic. From that date, the medications continued to be given by the tutor, subcutaneously and daily, for another two months. After this period, the application frequency was reduced to alternate days for another two months. Subsequently, the application frequency was changed to three times a week. Then, at the end

of nine months, the tutor reported that she no longer remembered to give the medication as described, and the treatment of the animal was partially discontinued. According to the tutor's report, she remained giving the oral medications as initially prescribed, but only one application of *V. album* per week was performed. At that moment, the animal maintained its general condition of stable health. However, the tumor evolution was observed in the US images, and resumption of daily subcutaneous injectable medications was recommended, as well as the intravenous administration of *V. album*. Also, a modification in the blood count and biochemical

dosages was verified from April/2019. After 13 months (April/2020), the animal was already quite debilitated. He was affected by *Bordetella bronchiseptica*, a bacteria responsible for the disease called kennel cough, which required starting an antibiotic therapy (Agemoxi 250®, 1/2 pill, BID, for 15 days), green propolis ten drops, BID, for ten days, orally, with an improvement of clinical signs in ten days after treatment initiation. Chest x-ray was performed in the lateral (left and right) and ventrodorsal projections. No metastases were visualized. After this episode, the patient remained apathetic and showed reduced appetite, temperature 37.6 °C, and no improvement in his condition. The tutor started the *V. album* D2 daily applications, and the animal showed a slight improvement in early May/2020. However, he was admitted to an intensive care unit with respiratory difficulty and significantly altered liver enzymes. The animal died 18 hours after admission at the end of May/2020.

## Discussion

Cancer is a disease of complex treatment, which depends on the stage of disease development and the overall health conditions of the patient at diagnosis. Additionally, several types of cancer are not responsive to the treatments of choice. Therefore, in many cases, there are no conditions for treatment continuity (Valle et al., 2020; Valle and Carvalho, 2021a, 2021b).

Under these circumstances, Palliative Care may be required to provide the best quality of life for patients with a life-limiting or terminal condition. The support of complementary therapies, such as homeopathy, chromotherapy, physical therapy, and the *V. album* therapy, became very important tools within Palliative Care. Thus, these therapies act by enhancing the treatment quality to relieve the suffering of patients, prolong survival, and provide welfare and dignity to patients until their death (Valle and Carvalho, 2021a, 2021b).

Hepatocellular carcinoma, specifically, is a disease affecting elder dogs with an average age of 11. Eighty percent of the affected animals are over ten years old, and there is a male sex predomination (Patnaik et al., 1980, 1981), which agrees with the case here reported (12-year-old male patient). Furthermore, this neoplasm can be defined as a large tumor affecting a single hepatic lobe. It represents 61% of all canine HCC, of which almost 70% occurred on the left side (Patnaik et al., 1981; Liptak et al., 2004).

Contrasting previous data (Liptak et al., 2004; Withrow et al., 2013; Chevallier et al.,

2015), the neoplasm on the left side of the patient's liver presented aggressive behavior and relapsed soon after its removal. Its margins were compromised, as confirmed by histopathological analysis. However, no metastasis was recorded, which is consistent with Chen et al. (2021), who stated that the majority of HCC has a lower metastasis rate than modular or diffuse forms.

Despite the apparent aggressiveness of the tumor, the non-adherence to conventional treatment by chemotherapy, and the impossibility of performing radiotherapy, the animal was treated by complementary therapies and, mainly, by homeopathic *V. album*. This medicine is widely used as an adjunct to the treatment of cancer, including HCC, owing to its cytostatic and immunomodulating effects and its ability to improve the quality of life and prolong the survival of patients (Valle et al., 2021).

*V. album* was given in several potencies, providing quality of life and control of tumor growth and liver enzymes (Table 1) during the period the treatment was carried out as per veterinary recommendation. A complete and durable response of advanced HCC to treatment is rare, although it has already been previously reported to *V. album*, including tumor remission and prolonged survival (Orange et al., 2021).

However, the discontinuation of the treatment initially proposed resulted, over the months, in tumor evolution, alterations in the blood count and biochemical measurements, and, ultimately, deterioration of the patient's overall health condition. Advanced-stage HCC (like multifocal lesions) has a poor prognosis, with few effective treatment options available and short life expectancy (Orange et al., 2021). Factors indicating poor prognosis include high ALT and AST serum levels, as they may be caused by aggressive biological behavior of the tumor, such as rapid growth rate or large size (Liptak et al., 2004). Given these results, it was suggested that the daily subcutaneous injectable medications be restarted, which provided a slight improvement in the quality of life (improved appetite and sleep, reduced anxiety) of the patient until the moment of his death. In conclusion, these findings highlight the importance of continuing the treatment as initially recommended since cancer is a chronic disease that needs continuous control to prevent/minimize tumor growth (Valle et al., 2020).

## Conclusion

~~Palliative care, especially when using complementary therapies such as homeopathy, improves the quality of life associated with~~

prolonged survival. In this context, *V. album* is widely used as an adjunct to cancer treatment, including HCC. In this study, Tumor growth and the patient's overall health condition were controlled during the period the medication was given as prescribed. The tumor started to grow again when the medication was discontinued, and the animal's overall condition began to deteriorate, demonstrated by an increase in liver enzymes. These findings illustrate the chronic character of the oncological disease and the need for its constant

control by using medications that have cytotoxic activity for the tumor and immunomodulatory for the patient. However, further studies are needed to better understand the benefits provided by these therapies.

#### Declaration of conflict of interest

The authors declare that they have no conflict of interest. Furthermore, the authors declare that the animal's tutors authorized the publication of their data in this article.

#### References

1. Chen, C.F., Chiu, S.W., Pan, L.K., & Chuang, C.H. (2021). Canine Hepatic Carcinoma: Diagnoses and Treatments Via Global State-of-the-Art Approach and Traditional Chinese Veterinary Medicine. In C. Rutland. (Ed.) *Canine Genetics, Health and Medicine*. IntechOpen. <https://doi.org/10.5772/intechopen.96077>.
2. Chevallier, P., Baudin, G., Anty, R., Guibal, A., Chassang, M., Avril, L., & Tran, A. (2015). Treatment of hepatocellular carcinomas by thermal ablation and hepatic transarterial chemoembolization. *Diagnostic and interventional imaging*, 96(6), 637–646. <https://doi.org/10.1016/j.diii.2015.04.006>
3. Liptak, J. M., Dernell, W. S., Monnet, E., Powers, B. E., Bachand, A. M., Kenney, J. G., & Withrow, S. J. (2004). Massive hepatocellular carcinoma in dogs: 48 cases (1992-2002). *Journal of the American Veterinary Medical Association*, 225(8), 1225–1230. <https://doi.org/10.2460/javma.2004.225.1225>
4. Orange, M., Poidimani, N., Crosignani, A., Werthmann, P. G., & Bertotto, C. (2021). Complete, Durable Remission of Advanced Hepatocellular Carcinoma Under Treatment with *Viscum Album* Extracts – A Case Report. *SSRN Electronic Journal*. Available at SSRN: <https://ssrn.com/abstract=3775671> or <http://dx.doi.org/10.2139/ssrn.3775671>
5. Patnaik, A. K., Hurvitz, A. I., & Lieberman, P. H. (1980). Canine hepatic neoplasms: clinicopathologic study. *Veterinary pathology*, 17(5), 553–564. <https://doi.org/10.1177/030098588001700504>
6. Patnaik, A. K., Hurvitz, A. I., Lieberman, P. H., & Johnson, G. F. (1981). Canine hepatocellular carcinoma. *Veterinary pathology*, 18(4), 427–438. <https://doi.org/10.1177/030098588101800402>
7. Valle, A., Lima, L.R., Bonamin, L.V., Brunel, H.D., Barros, A., Carvalho, A.C., & Andrade, R.V. (2020). Use of *Viscum album* in the Integrative Treatment of Cholangiocarcinoma in a Dog (*Canis familiaris*)- Case Report. *Advances in Complementary & Alternative Medicine*, 5(4), 476-481.
8. Valle, A.C.V., & Carvalho, A.C. (2021a). Ultra-diluted *Viscum album* in the treatment of cutaneous melanoma in a dog (*Canis familiaris*) - Case report. *Paripex Indian Journal Research*, 10:1-4. <https://doi.org/10.36106/paripex/2308743>
9. Valle, A.C.V., & Carvalho, A.C. (2021b). Homeopathic *Viscum Album* on the Treatment of Scamous Cell Carcinoma Lesion in a Dog (*Canis familiaris*) - Case Report. *Integrative Journal of Veterinary Biosciences*, 5:1-3.
10. Valle, A.C.V., Carvalho, A.C., & Andrade, R.V. (2021). *Viscum Album* - Literature Review. *International Journal of Science and Research*, 10:63-71.
11. Withrow, S.J., Page, R., & Vail, D. (2013). *Withrow and MacEwen's Small Animal Clinical Oncology*. Elsevier. <https://doi.org/10.1016/C2009-0-53135-2>