



OPEN ACCESS

Published: August 31, 2023

Citation: Fujisaki R, Yamaoka T, et al., 2023. Case of Penicillin-Resistant Pneumococcal Bronchitis: Gram Staining as the Earliest and Useful Indicator for Evaluating the Effectiveness of Antimicrobial Therapy in Outpatient, Medical Research Archives, [online] 11(8). <https://doi.org/10.18103/mra.v11i8.4207>

Copyright: © 2023 European Society of Medicine. This is an open-access article distributed under the terms of the Creative Commons Attribution License, which permits unrestricted use, distribution, and reproduction in any medium, provided the original author and source are credited.

DOI

<https://doi.org/10.18103/mra.v11i8.4207>

ISSN: 2375-1924

CASE REPORT

Case of Penicillin-Resistant Pneumococcal Bronchitis: Gram Staining as the Earliest and Useful Indicator for Evaluating the Effectiveness of Antimicrobial Therapy in Outpatient

Ryuichi Fujisaki¹, Toshimori Yamaoka¹, Michiko Yamamura¹, Hajime Nishiya^{*2}

¹ Department of Internal Medicine, Teikyo University Hospital, Tokyo, Japan

² Department of Internal Medicine, Shinyamanote Hospital, Japan Anti-Tuberculosis Association

*Corresponding author: hnishiya@shinyamanote.jp

ABSTRACT

A 75-year-old man was seen in the general practice in our hospital because of fever of 38-39°C, cough and purulent sputa on January 8th. Six days before visit, he had the chief complaint. The day before, he visited a clinic. The chest X-ray showed no pneumonia shadow, suggesting of bronchitis with old tuberculous changes. Azithromycin was administered, but no improvement was seen. The doctor sent him to our hospital. Gram-stained sputum samples showed gram-positive diplococcus, later identified as penicillin-resistant *Streptococcus pneumoniae*. He was administered two grams of ampicillin for 30 minutes. Gram-stained sputum samples showed smaller or gram-negative pneumococci at the completion of administration of the agent, and a decreased number of extracellular cocci and increased number of phagocytized small and weakly stained cocci at two hours after completion of administration. We estimated the effectiveness of ampicillin and prescribe 2g of amoxicillin hydrate (500mgX4) for 2days followed by 1.5g of amoxicillin hydrate (500mgX3) for the next 5days (till 2/15). He was seen on the 7th day (2/14) again with no fever, a decreased amount of cough and sputa. The culture of the sputum on the first day (2/8) revealed penicillin-resistant *Streptococcus pneumoniae* 3+ resistant to penicillin and ampicillin. But Gram-stained sputum samples showed little number of cocci and we confirmed the effectiveness of ampicillin prescribing no additional antimicrobial agent. He was seen on the 12th (2/19) to follow up the course, and getting better with little cough having watery sputa. The culture of the sputum on the 7th (2/14) day revealed no *Streptococcus*. However, Gram-stained sputum samples showed some extracellular cocci suggesting of pneumococci, and we predicted the coming relapse of bronchitis. We prescribed new ketolide antimicrobial drug telithromycin (300mgX 2) for 3days. On the 15th (2/22) he visited our hospital again with no respiratory symptom and Gram-stained sputum samples showed no cocci suggestive of pneumococcus. He recovered from bronchitis. We present here a case in which morphological changes and/or a decreased number of extracellular *S. pneumoniae* observed in Gram-stained sputum samples obtained after the first administration of antimicrobial agents presented useful information as a reliable therapeutic indicator of the effectiveness of the first administered agent, and follow up check of Gram-stained sputum could prevent the relapse of bronchitis before worsening in outpatient.

Keywords: pneumococcal bronchitis, gram staining, therapeutic indicator, outpatient

Introduction

Pneumococcal disease is a major cause of clinical and economic burden worldwide.¹ In terms of sensitivity, the high prevalence of resistance to penicillin by *Streptococcus pneumoniae* is considered as a great concern, particularly in Asian countries.² Recently, shortening the duration of antibiotic therapy for patients admitted to hospital with community-acquired pneumonia (CAP) is tried, which leads reduce antibiotic consumption and thus bacterial resistance, adverse events, and related costs. Discontinuing β -lactam treatment after 3 days was non-inferior to 8 days of treatment.³ To evaluate the effectiveness of the antimicrobial agents, apyrexia and resolution or improvement of respiratory symptoms are useful sign of recovery, and some markers including white blood cell count (WBC), serum C-reactive protein (CRP) level, and the extent of consolidation shadows on an x-ray film of the chest are useful and are frequently checked. But these markers need some time to evaluate the effectiveness of β -lactam treatment. Implementation of sputum Gram stain in the initial assessment of CAP patients is still controversial. Sputum Gram stain test is sensitive and highly specific for identifying the main causative pathogens in adult patients with CAP.⁴ Gram staining has been classified as a tool for diagnosis, however we have shown in patients admitted to hospital with *S. pneumoniae* and *M. catarrhalis* pneumonia that gram-stained sputum obtained just after or one hour after two grams of ampicillin (ABPC) administration or one gram of cefotaxin administration present useful information as a reliable and the earliest therapeutic indicator of the effectiveness of the agent.⁵ The aim of this case-report study is to clarify the effectiveness of gram-stained sputum after 2g of ABPC administration in pneumococcal respiratory infection in outpatient. Our data shows, Gram staining should also be put in the tools capable of evaluation of the therapy.

Case reports

A 75-year-old man with hypertension, hyperuricemia and dyslipidemia was seen in the general practice in our hospital January 8th in 2006. He was well until one week previously, when he developed a fever of 38-39°C, cough and purulent sputa. The two days before he had appetite loss. The day before, he visited a clinic. The chest X-ray showed no pneumonia shadow with old tuberculous change, suggesting of bronchitis. Laboratory tests were performed. The WBC was normal (WBC, 6400/mm³). The CRP level was elevated at 13.2

mg/dl and antigen test for influenza virus was negative. Azithromycin was administered, but no improvement including fever was seen. The doctor sent him to our hospital. At the time of examination, his body temperature was 36.6 °C. His consciousness was clear and his pulse was 89 beats/min. His blood pressure was 132/66 mm Hg. On physical examination, no fine crackle was heard. His heart and abdomen were normal and no lymphadenopathy was found. He had a history of lung tuberculosis at age of 20, bronchial asthma till age of 40 and operation of liver carcinoma at age of 74. Laboratory tests were performed. The WBC was normal (WBC, 6800/mm³; myelocyte 1%, stab 8%, segment 43%, lymphocyte 35%, monocyte 12%). The CRP level was elevated at 12.7 mg/dl. Erythrocyte sedimentation rate 34mm/h. Platelet count was 88000 / μ l.

Gram staining of the sputum sample obtained at the time of examination showed many neutrophils and a large number of gram-positive diplococci, suggesting *S. pneumoniae* (Figure 1). Two grams of ABPC was intravenously administered for 30 minutes. At the completion of administration of ABPC, the pneumococci had become smaller in size compared with those seen before the therapy, and some had lost their gram-positive staining and were detected as gram-negative cocci (Figure 2). The changes progressed two hours after completion of ABPC and the number of extracellular cocci decreased and phagocytosed cocci increased with small and decreased gram-positive staining (Figure 3). When the microscope changed into dark-field, intracellular cocci revealed more conspicuous. These changes on Gram staining showed the effectiveness of ABPC. We estimated the effectiveness of ABPC and diagnosed temporary that he had pneumococcal bronchitis probably induced by penicillin-sensitive *Streptococcus pneumoniae*. We prescribed 2g of amoxicillin hydrate (AMPC) (500mgX4) for 2days followed by 1.5g of AMPC (500mgX3) for the next 5days (till 2/15).

He was seen on the 7th day (2/14) again with no fever from the next day of the first visit, a decreased amount of cough and sputa. His body temperature was 36.6 °C. On physical examination, no fine crackle was heard. Laboratory tests were performed. The WBC was normal (WBC, 5000/mm³; myelocyte 1%, stab 4%, segment 64%, lymphocyte 26%, monocyte 7%). The CRP level was decreased at 1.33 mg/dl. Erythrocyte sedimentation rate 34mm/h. Platelet count was 175000 / μ l.

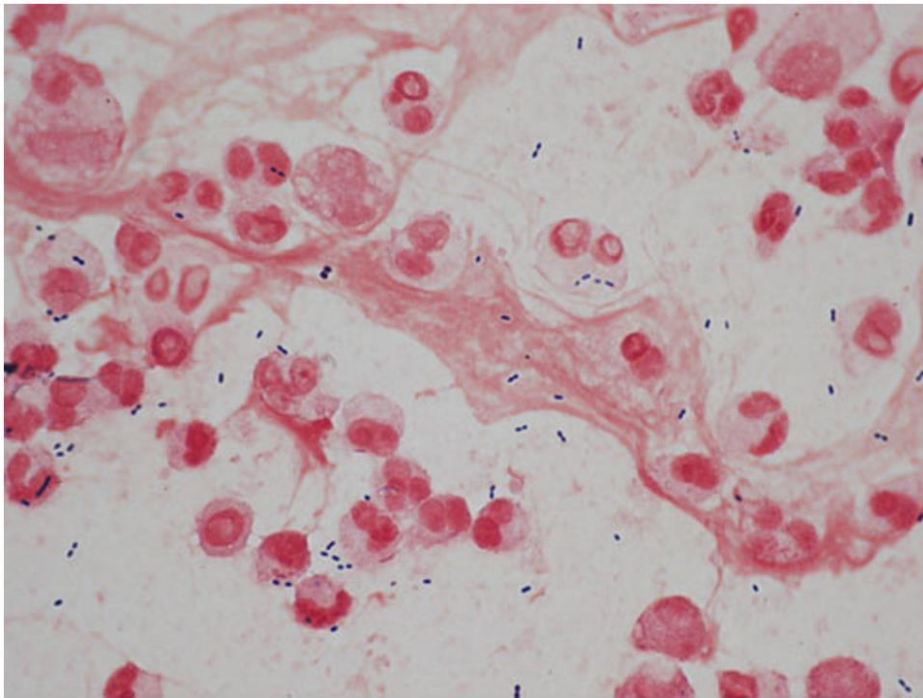


Figure 1. Gram staining of sputum samples (X 1000) on the first day of January 8th. The sputum sample showed a large number of gram-positive diplococci, identified as *S.pneumoniae* .

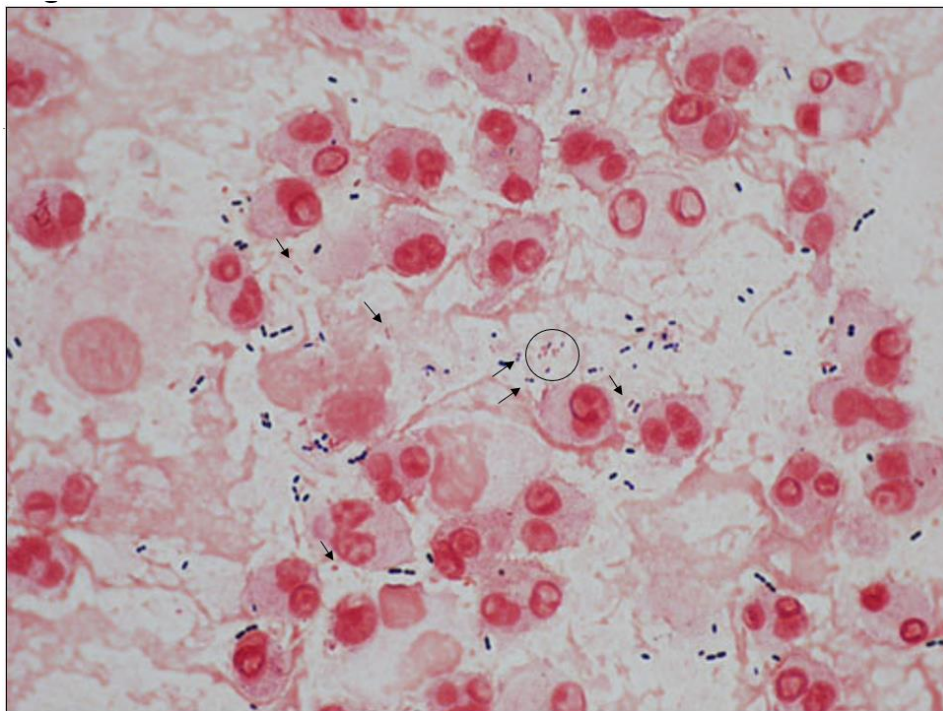


Figure 2. Gram staining of sputum samples (X 1000) on the first day (2/8) obtained at the completion of administration of 2 grams of ampicillin for 30 minutes. Some pneumococci have become smaller in size than those seen before the therapy and the unevenness in size was conspicuous. They lost their gram-positive staining and detected as gram-negative diplococci or cocci.

○; the round part contains small and decolored cocci.

↗; arrow shows smaller diplococcus.

↘; arrow shows smaller and decolored diplococcus or coccus

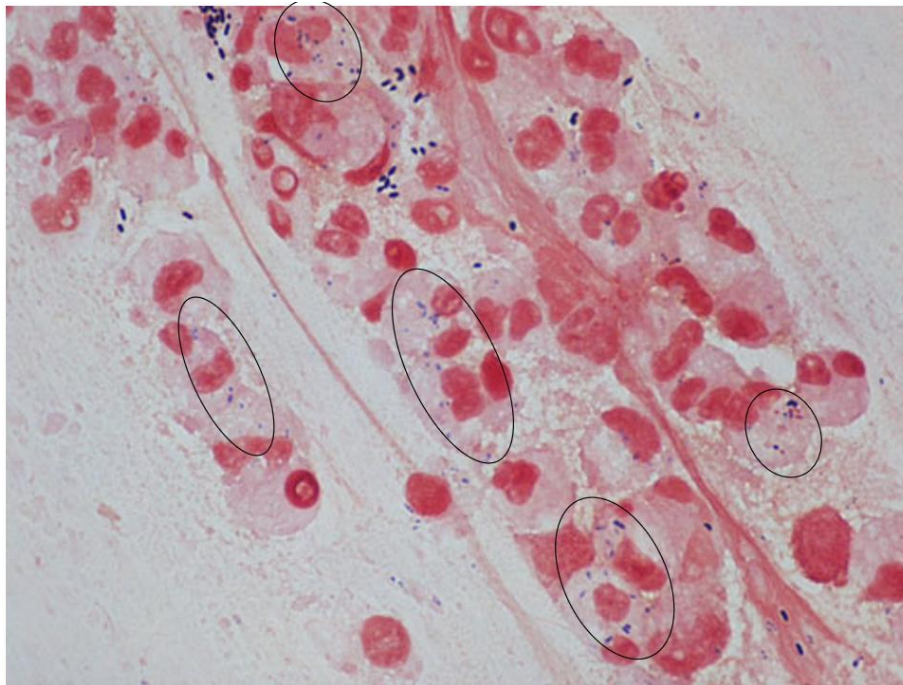


Figure 3. Gram staining of sputum samples (X 1000) on the first day (2/8) obtained two hours after the completion of 2 grams of ampicillin for 30 minutes. The changes have progressed and the number of extracellular cocci decreased and many phagocytosed small and weakly stained gram-positive cocci are seen. ○; in the circle many phagocytosed small and weakly stained gram-positive cocci are seen.

The culture of the sputum on the first day (2/8 ; Figure 1) revealed *S.pneumoniae* (penicillin-resistance *S.pneumoniae*; PRSP) 3+ resistant to penicillin, AMPC, erythromycin and clindamycin and sensitive to cefepime, imipenem, levofloxacin and vancomycin. Gram staining of the sputa (2/14) revealed at a glance no microorganisms (Figure 4a). A careful searching found little number of cocci suggesting pneumococcus (Figure 4b). We evaluated that AMPC was clinically effective against his bronchitis. We ordered him to take AMPC till 8th day (2/15).

He was seen on the 12th day (2/19) after a week of AMPC therapy to follow up the course. He was getting better with little cough having watery sputa.

On physical examination, no fine crackle was heard. Laboratory tests were performed. The WBC was normal (WBC, 6300/mm³; neutrophil 61%, lymphocyte 33%, monocyte 5%). The culture of the sputum obtained on the 7th day (2/14), on the second visit, revealed no pneumococcus. We confirmed the effectiveness of AMPC bacteriologically. We anticipated his cure clinically based on the laboratory data and the sputum culture result on the 7th day. However, for confirmation, we checked his sputum and found that Gram staining of the sputum sample (2/19) showed many neutrophils and gram-positive diplococci, suggesting of *S. pneumoniae* (Figure 4c), presenting a possibility of relapse of pneumococcal bronchitis in the future. We prescribed telithromycin (TEL,300mgX 2) for 3days.

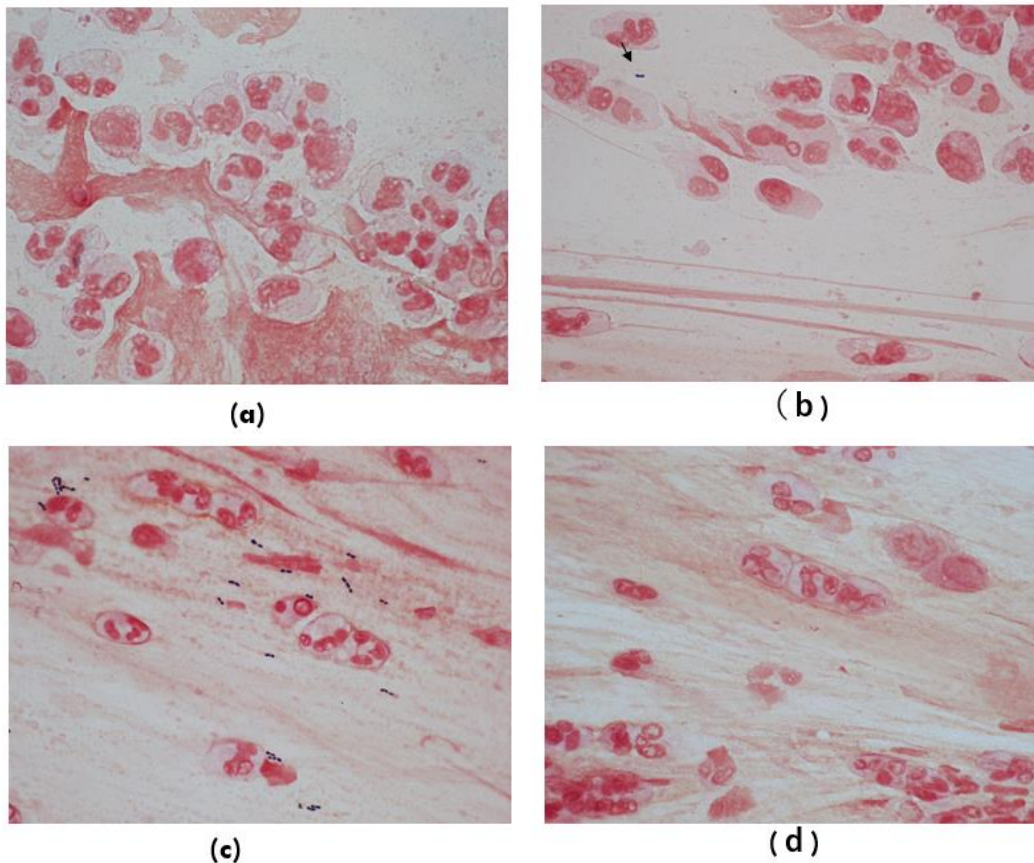


Figure 4. Gram staining of sputum samples obtained on the 7th day (2/14) (X 1000) revealed at a glance no microorganisms (a). The culture of the sputum obtained on the 7th day also revealed no pneumococcus. A careful searching found little number of cocci suggesting pneumococcus (b). Gram staining of sputum samples obtained on the 12th day (2/19) (X 1000). The sputum sample shows gram-positive diplococci again, suggesting a probability of relapse of pneumococcal bronchitis (c). We prescribed telithromycin (TEL,300mgX 2) for 3 days. The sputum sample on the 15th day (2/22) reveals no microorganisms either inside or outside the neutrophils (d).
↘; arrow shows diplococcus

On the 15th (2/22) he visited our hospital again with no respiratory symptom and Gram-stained sputum samples showed no cocci suggestive of pneumococcus (Figure 4d). The bronchitis was cured.

Discussion

Gram staining provides useful information on pathogens in sputa by morphologically distinguishing pneumococcus, staphylococcus, *M. catarrhalis* and *Haemophilus influenzae*, which allows selection of the appropriate empirical antimicrobial agents. Sputum Gram staining is sensitive and highly specific for identifying the main causative pathogens in adult patients with Community-acquired pneumonia (CAP) and healthcare-associated pneumonia (HCAP), and useful in guiding pathogen-targeted antimicrobial treatment.^{4,6,7} In Japan, Matsumoto et al. emphasized the importance of Gram staining in the management of CAP.⁸ But, as for ventilator-associated pneumonia (VAP), using Gram staining to determine necessity

of and to select class of antimicrobial therapy will result in delayed or inappropriate VAP therapy or both.^{9,10} We have presented cases in which gram-stained sputum obtained just after and/or 1 h after administration of the first antimicrobial agent were suitable as the quickest therapeutic indicator of the effectiveness of empiric therapy in CAP, which being shown much earlier than with markers such as WBC and CRP level.⁵ We have shown that at least two to four days are needed to evaluate the effectiveness of the antimicrobial agent when the WBC or CRP level is used as a therapeutic maker, while when a significant decrease in the number of pathogens in Gram-stained sputa is used as an indicator of the effectiveness of the agents, among the *S. pneumoniae* cases (n=6), the median duration needed to decide the effectiveness of the agent is 7 hours (range, 1 to 12 hours) after the first dosing.⁵ In our outpatient case the date of WBC and CRP was not useful marker because the infrequent check and the level of the data.

The changes of pneumococcus in Gram staining induced by ABPC administration include the emergence of smaller size and/or weekly gram positive or decolorized pink diplococci or cocci at the completion of administration of 2 grams of ABPC for 30 minutes, the increase in number of intracellular phagocytosed cocci and the decrease in number of extracellular cocci at two hours after completion of administration (Fig.2,3). The emergence of the changed cocci would be brought by blocking the synthesis of bacterial cell wall by ABPC leading to a thinner or damaged cell wall or capsule, enhancing for white blood cells to phagocyte bacteria (Fig. 3). In outpatient, in selected cases, we recommend the Gram staining of sputa at the first time in selecting the antimicrobial agent both before and after the administration and /or when the first therapeutic agent being not effective during the course. These data show that the decrease in number of extracellular cocci with normal size and stainability in the sputa may be used as a marker of quickly determining the useful antimicrobial agents in bacterial pneumonia and

bronchitis. A new way of detecting the number of viable bacteria in the sputa by using luminometer can be used for the purpose.

The culture of the sputum obtained on the 7th day (2/14) revealed no pneumococcus. Gram staining of the sample also revealed at a glance no microorganisms (Figure 4a), however, a careful searching found cocci in it (Figure 4b) though the number is little, showing that Gram staining is more sensitive than the culture in some case. The remained cocci might be PRSP, which might increase in number lead to diplococcus in the sputa on the 12th day (2/19). We prescribed new ketolide antimicrobial drug telithromycin on January 8th in 2006, which had strong antimicrobial activity against PRSP and low potential to induce resistance.¹¹ But telithromycin was later limited for its use because of loss of consciousness and liver dysfunction. Further studies are needed to confirm whether gram staining is available as a monitoring tool in following other bacterial pneumonias and when other antimicrobial agents are used.

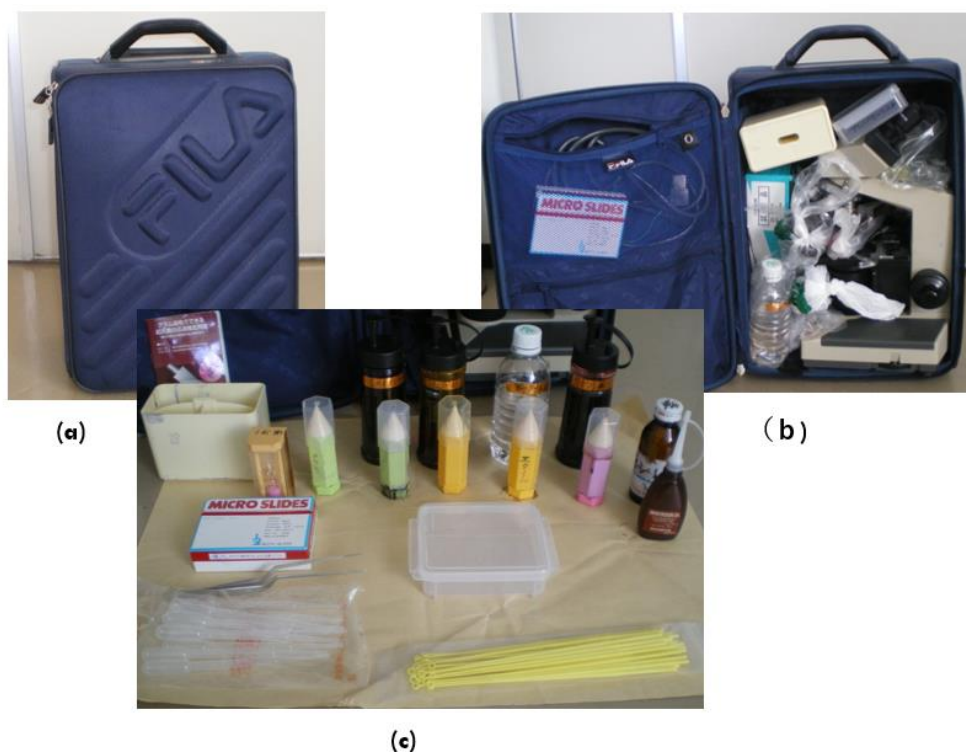

Figure 5. A movable Gram-staining Bag (a). The bag contains a various apparatus of Gram staining kit (b)(c).

One of attractivity contained with Gram staining¹² is its ability for visualizing inflammatory change in tissues directory and promptly with ease and inexpensively. Gram staining has been classified as a tool for diagnosis, however as our data shows, should also be put in the tools capable of evaluation

of the therapy. Gram staining is not good at identifying the main causative pathogens in aspiration pneumonia and VAP. But our experience in the hospital suggested that by making a comparison of the Gram-stained sputa or aspirated fluid for several times for a few days obtained after

the antimicrobial agent with the ones obtained before the therapy, we could often evaluate the effectiveness of the administered agent in aspiration pneumonia and VAP (data not shown). Gram negative strain, especially *Pseudomonas*, is sometime hidden among the pink mucus background. A newly developed modified Gram staining that enhances the contrast between bacteria and host tissue by adding one more step in decolorization with alcoholic saffron will probably be useful.¹³

In respiratory infections we need to utilize sputa more frequently and completely as the direct letter from the respiratory tract and lung. The finding of Gram-stained sputa will bring us more useful information if we use various new methods. We had been made a limitation for the ability of Gram staining only to pathogen stainable with Gram staining in bacterial infections. We have shown by using the focus chaining technique that Gram staining is useful as an initial diagnostic clue for pulmonary tuberculosis^{14,15} and tuberculous meningitis¹⁶ before using special staining, such as Ziehl-Neelsen staining. In the case of tuberculous meningitis, we were surprised to find tuberculous bacilli in Gram-stained neutrophils in the cerebral spinal fluid (CSF). In tuberculous meningitis, lymphocytic predominance in the CSF is usually observed, although it should be noted that neutrophils may predominate particularly during early in the course. We should pay more attentions not only to pathogen but also to pink -stained neutrophils especially early in the course when they increase in number in some the other infections including virus as influenzae, the roll of which in the infection may present a new finding. We hope, if

you are not, that doctors visit the bacterial division of laboratory in your hospital and discuss with laboratory technicians of the Gram-stained various samples obtained after antimicrobial agent administration you ordered. Gram staining is available out of the laboratory where no medical service is available. One of our members was sent to Miyako in the Tohoku district as a member of disaster medical assistance team (DMAT) in the East Japan Earthquake in 2011. He brought a "movable Gram-staining Bag" with him (Fig. 5). The bag contained a set of various apparatus of Gram staining. With the bag he managed the urinary tract and respiratory tract infections and found its usefulness. We think that the Gram staining Bag will contribute for technologists especially in developing countries. Further study is needed to utilize the old but new Gram staining more fully.

Conclusions

In managing outpatients with respiratory tract bacterial infections, we usually need to wait till the next visit in checking the effectiveness of the administered antimicrobial agents. Gram-stained sputum samples obtained just after administration of ABPC showed smaller size and/or weekly gram positive or decolorized pink diplococci or cocci, an increase in number of intracellular phagocytosed cocci and a decrease in number of extracellular cocci.

The changing patterns of Gram staining can be used as the quickest therapeutic indicator of the effectiveness of antimicrobial agent in pneumococcal respiratory infections.

References

1. Zarabi N, Aldev`en, Sj`olander S, Wahl HF, et.al. Clinical and economic burden of pneumococcal disease among adults in Sweden: A population-based register study. *PLoS One*. 2023 Jul 7;18(7):e0287581. doi:10.1371/journal.pone.0287581.
2. Mamishi S, Moradkhani S, Mahmoudi S, Sadeghi RH. Penicillin-Resistant trend of *Streptococcus pneumoniae* in Asia: A systematic review Iran J Microbiol. 2014 Aug;6(4):198-210.
3. Dinh A, Ropers J, Duran C, et.al Discontinuing β -lactam treatment after 3 days for patients with community-acquired pneumonia in non-critical care wards (PTC): a double-blind, randomised, placebo-controlled, non-inferiority trial Lancet. 2021 Mar 27;397(10280):1195-1203.
4. Rio-Pertuz D G, Gutiérrez FJ, Triana J A, et.al. Usefulness of sputum gram stain for etiologic diagnosis in community-acquired pneumonia: a systematic review and meta-analysis. *BMC Infect Dis*. 2019;19(1):403. doi: 10.1186/s12879-019-4048-6
5. Fujisaki R, Yamaoka T, Yamamura M, et.al. Usefulness of gram-stained sputum obtained just after administration of antimicrobial agents as the earliest therapeutic indicator for evaluating the effectiveness of empiric therapy in community-acquired pneumonia caused by pneumococcus or *Moraxella catarrhalis* J Infect Chemother. 2013; 19(3):517-523.
6. Rosón B, Carratalà J, Verdaguer R, et.al. Prospective study of the usefulness of sputum Gram stain in the initial approach to community-acquired pneumonia requiring hospitalization *Clin Infect Dis*. 2000;31(4):869-874.
7. Fukuyama H, Shin Yamashiro S, Kiyoshi Kinjo K, et.al. Validation of sputum Gram stain for treatment of community-acquired pneumonia and healthcare-associated pneumonia: a prospective observational study. *BMC Infect Dis*. 2014;14:534.
8. Matsumoto K, Uzuka Y, Taguchi M. Sputum bacteria quantification culture. *Media Circle* 1985; 19: 181–199 (in Japanese).
9. Goldberg EA, Malhotra KA, Riaz JO, et.al. Predictive value of broncho-alveolar lavage fluid Gram's stain in the diagnosis of ventilator-associated pneumonia: a prospective study. *J Trauma*. 2008;65(4):871-876; discussion 876-878.
10. John C O'Horo CJ, Thompson D, Nasia Safdar N, Is the gram stain useful in the microbiologic diagnosis of VAP? A meta-analysis. *Clin Infect Dis*. 2012;55(4):551-561.
11. Shigeru Kono, Overview of telithromycin. Nippon kagakuryouhou gattukaishi; abstract;. 2003;51.S-4;1-6
12. Richard Coico R. Gram staining Curr Protoc Microbiol. 2005 Oct;Appendix 3:Appendix 3C. doi: 10.1002/9780471729259.mca03cs00.
13. Becerra C S, Roy C D, Sanchez J C, et.al. An optimized staining technique for the detection of Gram positive and Gram negative bacteria within tissue. *BMC Res Notes*. 2016 Apr 12;9:216. doi: 10.1186/s13104-016-1902-0.
14. Atsukawa Y, Kawakami S, Asahara M, et.al. The usefulness of changing focus during examination using Gram staining as initial diagnostic clue for infective tuberculosis. *J Infect Chemother*. 2011;17(4):571-574.
15. Atsukawa Y, Kawakami S, Ono Y, et.al. Three cases of mycobacterium tuberculosis infection initially recognized by focus changing examination in gram staining Insight and control of infectious disease in global scenario 2012.261-270 www.intechopen.com
16. Kawakami S, Kawamura Y, Nishiyama K, et.al. Case of *Mycobacterium tuberculosis meningitis*: Gram staining as a useful initial diagnostic clue for tuberculous meningitis. *J Infect Chemother*. 2012;18(6):931-936.