



OPEN ACCESS

Published: August 31, 2023

Citation: Alharbi MA., 2023. The Outcome of Contemporary Intentional Replantation: A Retrospective Study, Medical Research Archives, [online] 11(8). <https://doi.org/10.18103/mra.v11i8.4228>

Copyright: © 2023 European Society of Medicine. This is an open-access article distributed under the terms of the Creative Commons Attribution License, which permits unrestricted use, distribution, and reproduction in any medium, provided the original author and source are credited.

DOI <https://doi.org/10.18103/mra.v11i8.4228>

ISSN: 2375-1924

RESEARCH ARTICLE

The Outcome of Contemporary Intentional Replantation: A Retrospective Study

Mohammed A Alharbi

Department of Endodontics, Faculty of Dentistry. King Abdulaziz University. Jeddah, KSA

E-mail: maealharbi@kau.edu.sa

ABSTRACT

Introduction: Intentional replantation is a clinical procedure in which a tooth is extracted and then replanted back into its original socket after root end endodontic treatment. This procedure is typically performed as a last resort when other treatment options, such as root canal therapy or apical surgery are not feasible or have failed. The success of intentional replantation depends on several factors including the length of time the tooth was out of the socket, the condition of the root surfaces and the skills of the clinician.

This retrospective case series aimed to assess the success rate of the intentional replantation procedures done in the Endodontic Department at the University of Pennsylvania and a faculty endodontic practice.

Methods: Thirty teeth met the inclusion criteria. Teeth were a-traumatically extracted. All the procedures were done under high-power magnification with the use of the surgical operating microscope. Teeth were kept hydrated with Hank's Balanced Salt Solution. Contemporary root end surgery was performed on the teeth outside the socket. Retrograde preparation and filling were performed with the use of Mineral Trioxide Aggregate or Endosequence Bioceramic Putty. The outcome of IR was determined by clinical and radiographic evaluation. The cases were categorized as completely healed, healing, or failed.

Results: Teeth with a minimum of 6 months follow up were included in the study. The mean follow-up period was 18 months. Twenty-two out of the thirty teeth showed complete healing, four were healing and four were considered failures. The overall success rate of the cases was 86.7%

Conclusion: Despite the small sample size, our results showed that intentional replantation is a reliable and predictable procedure; when indicated, with a very high success rate if it was done correctly in a timely manner and the periodontal ligament integrity was preserved as much as possible.

Introduction:

Prevention and/or elimination of pulpal pathology and apical periodontitis with re-establishment of normal periodontal apparatus is the goal of endodontic treatment. It is well documented in the literature that the success rate of contemporary primary non-surgical root canal treatment (NSRCT) is >90%.¹⁻³

However, apical periodontitis may not heal after the NSRCT and retreatment.⁴⁻⁷ Endodontic microsurgery is the procedure of choice in cases which the patient is willing to save his/her tooth and the tooth is restorable. The success rate of the microsurgical treatment was reported to be 94% in the systematic review and meta-analysis by Setzer et al. in comparison to the traditional surgical procedures 59%.^{8,9} The authors attributed this huge difference in the success rate to the use of a microscope, which helps identifying missed canals as well as rarefactions that might hold microorganisms. Additionally, the advanced armamentarium helps in reducing the size of the osteotomy, thus preserving tooth structure and minimizes iatrogenic errors. Finally, modern micro-endodontic technique uses biocompatible materials with a very high sealing ability such as Mineral Trioxide Aggregate (MTA; Dentsply, York PA) or Endosequence bioceramic putty (Endosequence BC RRM Fast Set Putty, Brasseler, Savannah, GA) as a retrograde filling material instead of using the amalgam.¹⁰⁻¹³

Despite its very high success, endodontic microsurgery may be contraindicated or very difficult to be performed in cases where there is proximity to vital anatomical structures such as the inferior alveolar canal, mental foramen, or maxillary sinus. Additionally, the thickness of the bone covering the roots as well as the tooth position in the jaw make accessibility very challenging. For those cases, the treatment of choice would be intentional replantation (IR).¹⁴

Intentional replantation was described by Grossman as "*the purposeful removal of a tooth and its almost immediate replacement with the object of obturating the canals apically while the tooth is out of the socket.*"^{15,16} A broad range of indications for IR was mentioned by Grossman, including; Root canal blockage and iatrogenic errors such as perforations.

The success rate of non-surgical root canal retreatment of the cases when the root canal morphology was not respected dropped significantly to below 50% as shown by Gorni and Gagliani.¹⁷ Another indication for IR is teeth with complex anatomy or a C-shaped canal configuration which are considered highly difficult cases to treat with non-surgical root canal treatment or apical microsurgery because of their complex anatomy and difficult access. A systematic review

and meta-analysis of 25,445 teeth from 13,142 patients was conducted to investigate the prevalence of C-shaped canals in mandibular second molars. The pooled prevalence of C-shaped canals in mandibular second molars was 12%. There was a significant difference in the prevalence of C-shaped canals between mandibular first molars 0.3% and second molars 12%.¹⁸ It has been shown that East Asian countries' prevalence of C-shaped canals in mandibular second molars was considerably higher compared with other regions.¹⁹ Intentional replantation may be a treatment option for such teeth based on a study investigating the factors that predicted the success of intentionally replanted teeth with a C-shaped canal.²⁰

Several studies linked overfilling of root canal material and treatment failure.^{21,22} The extruded material can contain microbes and can induce inflammatory and foreign body reactions.²³ If the extruded material is in proximity to the maxillary sinus, inferior alveolar canal, or the mental foramen, then intentional replantation could be the treatment of choice when the root-end surgery is not applicable.

This retrospective study aimed to assess the outcome of IR procedures treated at the Endodontic Department at the University of Pennsylvania (UPENN) and an endodontic faculty practice.

Materials & Methods

This study included all teeth that were replanted between the years 2009 -2017 at the UPENN graduate endodontic clinic and a faculty endodontic office. All cases were evaluated by an experienced endodontist. Cases that were not replanted due to root fracture, determined non-restorable after extraction, etc., were not included in this study.

Patient preparation:

Consent was obtained from the patients. They were properly anesthetized after all the clinical examinations were performed and the required radiographs were obtained.

Extraction process:

Teeth were a-traumatically extracted using forceps with a controlled force to expand the bone plates and to passively luxate the tooth. After extraction, teeth were inspected with high magnification under the surgical, dental microscope (OPMI PROergo, Carl Zeiss, Oberkochen, Germany) for any signs of cracks and to verify the anatomy of the apical end.

Root-End preparation:

If there were no signs of cracks or fractures, the operator proceeded under the microscope with root-end resection using Lindemann bur in a high-

speed motor, root-end cavity preparation using #330 bur, and root-end filling with either Mineral Trioxide Aggregate (MTA; Dentsply, York PA) or Endosequence bioceramic putty (Endosequence BC RRM Fast Set Putty, Brasseler, Savannah, GA). The teeth were kept constantly hydrated with Hanks Balanced Salt Solution (HBSS) (Gibco™, Life Technologies Corporation, New York, USA) throughout the procedure. Teeth were then placed back into the socket after gentle removal of any granulation tissues without scrapping the walls of the socket to maintain the integrity of the viable PDL cells. Then, pressure was applied to approximate the expanded plates. Patients were asked to bite firmly on gauze for 5-10 minutes, afterward the mobility was evaluated. Teeth were splinted with a non-rigid splint if they demonstrated greater than plus 2 mobility. The extra oral time was monitored for every case and was kept within 15 minutes.

Follow-up process.

Cases with a minimum of 6 months follow-up were included. Clinical examination as well as periapical radiographs were obtained at the follow-up visits. The clinical examination was done by an experienced endodontist. The medical history of the candidates was updated. Intra and extra oral examinations were completed. The periodontal examination included measuring the periodontal pocket depth, mobility, palpation, and percussion. Teeth were also examined for any discoloration, caries, and the integrity of the coronal restoration was evaluated. Parallel periapical radiographs were obtained to all teeth that were involved using (Kodak RVG5200: Carestream Health, Rochester, NY), and Limited Field of View (FOV) cone-beam computed tomographic (CBCT) scans were obtained using Veraviewepocs 3D R100 (Morita, Irvine, CA). Follow-up radiographic examination was done blindly by two calibrated experienced endodontists. If there was any disagreement a maxillofacial radiologist was asked to give his professional opinion. Scans and radiographs were used to evaluate the healing and to detect any signs of external root resorption or ankylosis.

Statistics.

Statistical analysis was performed using SPSS version 28 (IBM SPSS Statistics, Chicago, IL, USA). Chi-Squared test was used to check if the distribution of the variables was statistically significant at a significance level of $P < 0.05$. Tukey HSD Post-hoc test was used to identify which specific pairs of means were significantly different.

Results

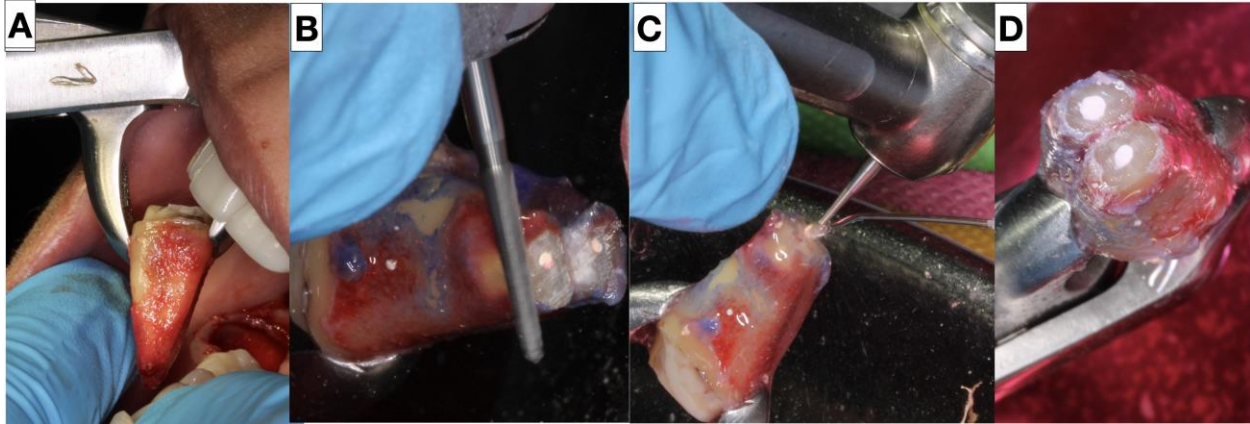
Since there are no clear criteria to evaluate the success of IR cases, we are proposing a new evaluation criterion for IR as follows: (A) Completely healed; no clinical signs or symptoms of pathology, mobility, and probing depth within normal limits; complete radiographic resolution of apical radiolucency with re-establishment of normal PDL space and lamina dura without signs of ankylosis, external inflammatory or replacement resorption (Figure 2.) (B) Healing; no clinical signs or symptoms of pathology, mobility, and probing depth within normal limits, radiographic reduction of apical radiolucency without signs of ankylosis, external inflammatory, or replacement resorption (Figure 3). (C) Failed; persistent clinical signs or symptoms such as pain, sinus tracts, deep probing, increased mobility, and/or no radiographic reduction or an increase of the size of the apical lesion (Figure 4). Cases in the healed and healing groups were considered a success.

A total of 30 teeth were included in the study, with a mean follow-up period of 18 months. The overall success rate was 86.7%, with 26 teeth (73.3%) completely healed, 4 teeth (13.3%) healing, and 4 teeth (13.3%) failed. (Figure 5)

The success rate was highest for anterior teeth (100%), followed by premolars (83%) and molars (68%). There was no statistically significant difference in the success rate between tooth types ($p > 0.5$). The success rate was also higher for male patients (81.8%) than female patients (72.2%) but this difference was not statistically significant ($p > 0.5$). (Table 1)

The most common reason for failure was vertical root fracture (50%), followed by periodontal breakdown (25%) and loss of coronal coverage (25%). (Table 1)

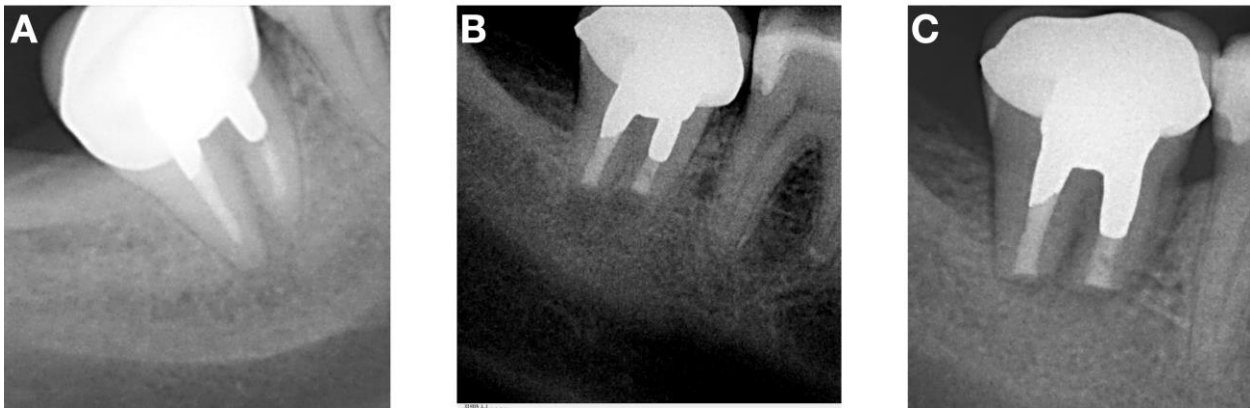
Figure 1.



- Figure 1: A representative case of IR procedure.

(A) A-trumatic extraction of the tooth. (B) Root end resection using surgical bur. (C) retro-grade preparation using 330 bur. (D) Retrograde filling with Bioceramic root repair material.

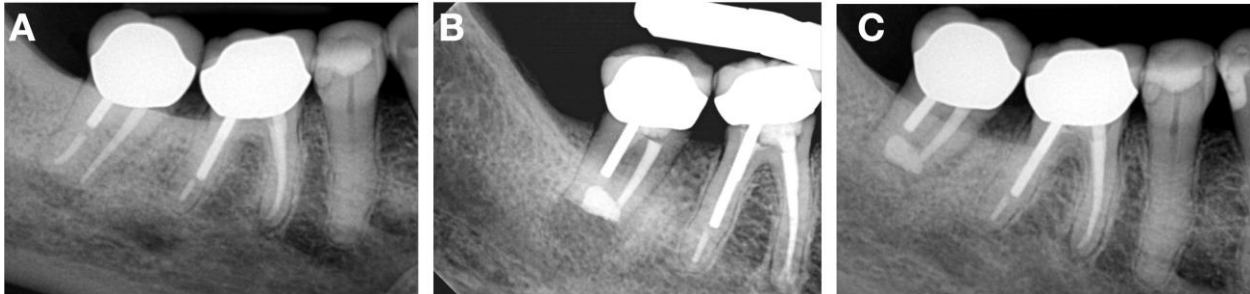
Figure 2.



- Figure 2: A representative sample of a completely healed case.

(A) A pre operative radiograph, (B) immediate post operative radiographs, (C) 1 year follow up radiograph that shows a complete resolution of the periradicular radiolucency with reestablishment of normal PDL space and lamina dura.

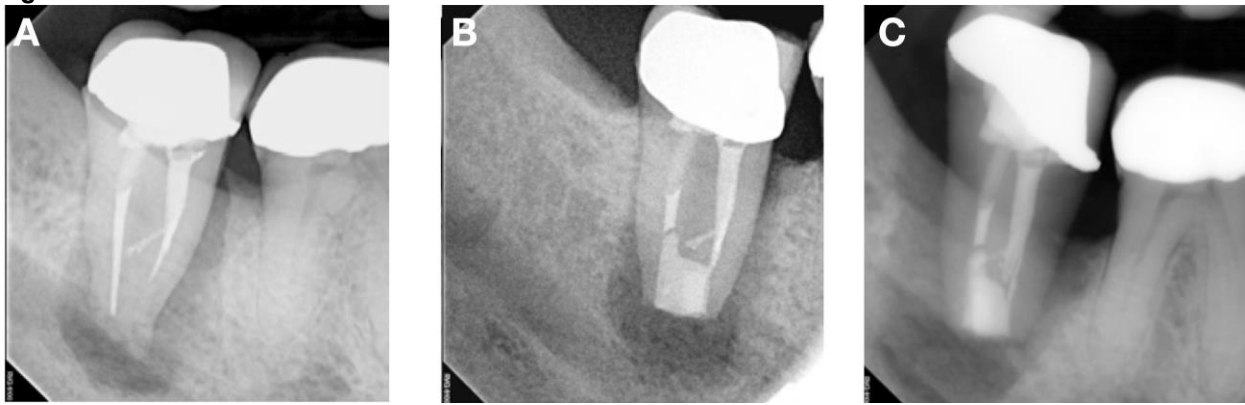
Figure 3.



- Figure 3: A representative sample of a healing case.

(A) A pre operative radiograph, (B) immediate post operative radiographs, (C) 1 year follow up radiograph that shows a significant reduction in the periapical radiolucency.

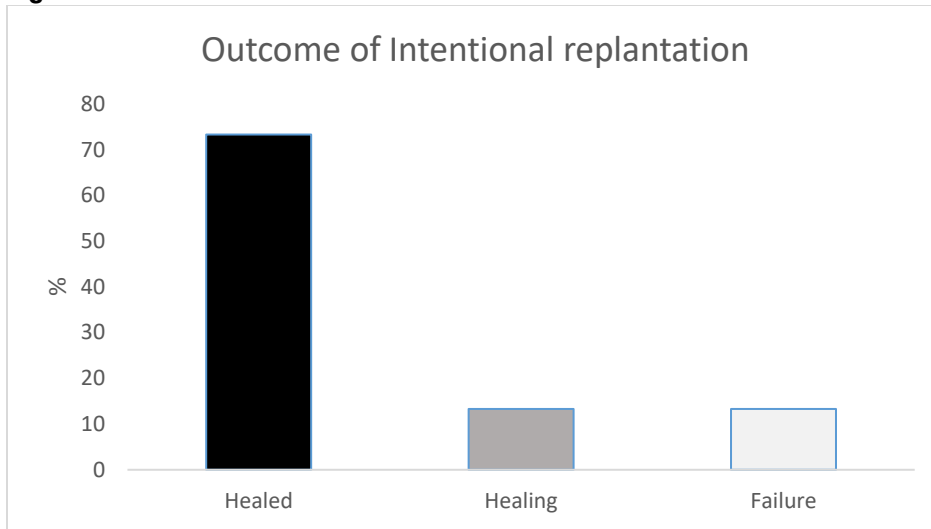
Figure 4.



- Figure 4: A representative sample of a failed case.

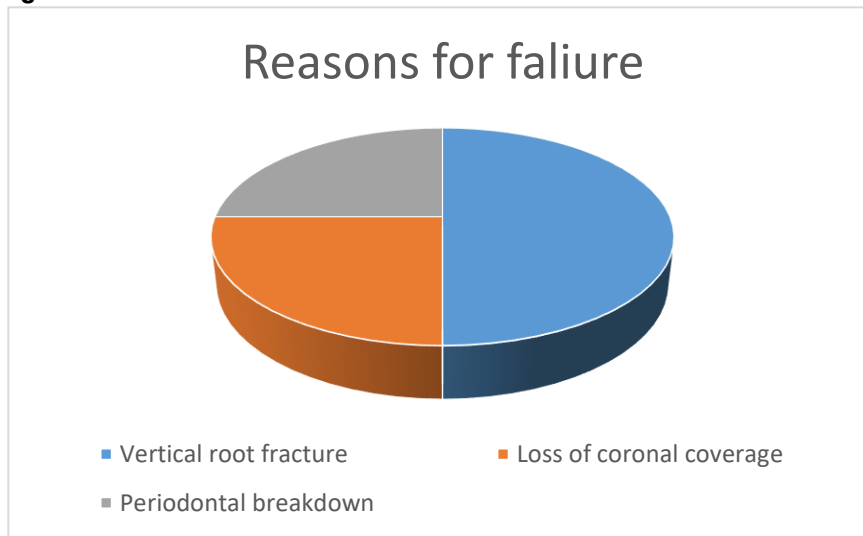
(A) A preoperative radiograph, (B) immediate post operative radiographs, (C) 1 year follow up radiograph that shows the increase of the periapical radiolucency.

Figure 5.



- Figure 5: A quantitative representation of the outcome of the cases.

Figure 6.



- Figure 6: The reasons for failure.

Vertical root fracture accounted for 50% of the failures. Periodontal breakdown and loss of coronal coverage accounted for the other 50%.

Table 1. The distribution of the cases based on the tooth type and gender.

Tooth Type	Healed	Healing	Failed	Total (%)	Success rate
Anterior	2	0	0	2 (6.7%)	100%
Premolar	5	0	1	6 (20%)	83%
Molar	15	4	3	22 (73.3%)	68%
Male	9	2	1	11 (40%)	81.80%
Female	13	2	3	18 (60%)	72.20%
Total (%)	22 (73.3%)	4 (13.3%)	4 (13.3%)	30 (100%)	

Discussion

The reported literature showed a lack of consistency in defining the criteria for successful replantation. We are proposing new evaluation criteria to assess the IR outcome.

The overall success rate of our retrospective study was 86.7% which was within the reported range of success (80 -95 %) as previously reported.²⁴⁻²⁶

The higher success rate for anterior teeth is likely due to the fact that anterior teeth have a simpler root anatomy than molars.

A pivotal rule for successful replantation is to preserve, as much as possible, a healthy, viable PDL to minimize the chances of postoperative root resorption. In our study we reported no incidence of root resorption. The absence of reported resorption can be attributed to multiple factors, including atraumatic extraction, as the mechanical damage during extraction can be a leading factor for resorption. Furthermore, the very short extraoral working time of 10- 15 minutes has been shown to be adequate for PDL healing.^{27,28} In addition to the minimal extra-oral time, we believe that the constant irrigation of HBBS provided the PDL cells with the necessary nutrients to maintain their integrity. All these factors, atraumatic extraction and maintaining viable PDL, are considered key factors for a successful IR.²⁹

Hayashi et al. (2006) introduced the concept of 'ortho-transplantation.' He proposed the use of orthodontic forces to extrude the donor teeth to increase the volume of the PDL cells to minimize the chances of external inflammatory or replacement resorption after auto transplantation.

The same philosophy was adopted by Choi et al. They have reported 98% success rate in cases with orthodontic extrusion before IR and no cases with external resorption.²⁴ Most of the IR failures occurred within the 1st year of treatment. Most of the cases that were successful in the 1st year survived for a long period as shown by several authors.^{24,30}

In a study aimed to assess the outcome of IR in periodontally compromised teeth, 103 teeth had been replanted after being extracted for

periodontal disease. The study found that 68% of the teeth were still in place and functional at four years after replantation.³¹

Another investigation looked at the periodontal parameters before and after IR was done for periodontally involved teeth. Clinically, they measured the bleeding on probing, pocket depth and clinical attachment loss. Radiographically they used a software to measure the bone height and thickness before and after the IR procedure using CBCT images. Their results showed significant improvement in all the periodontal parameters evaluated.³² These studies suggest that IR can be a successful treatment option for periodontally compromised teeth. However, it is important to note that the success rate of the procedure depends on many variables.

Case selection is a critical step in the decision-making process for intentional replantation. There are several factors that need to be considered when selecting a case for this procedure. The overall health and strength of the tooth should be able to withstand the extraction procedure without significant damage. This means that the tooth should not have any significant decay or damage. The root structure should also be sound, with no fractures or cracks. The root form should be carefully studied before attempting the procedure. Severely curved or dilacerated roots are not suitable candidates for intentional replantation. These roots are more difficult to replant and are more likely to fail.

There are several reasons why CBCT is so important for reading tooth anatomy prior to extraction. First, it provides a much clearer view of the tooth and surrounding structures than traditional 2D radiographs. This is especially important for teeth that are difficult to visualize with 2D radiographs, such as impacted teeth or teeth with complex root anatomy. Second, CBCT can provide information about the relationship between the tooth and surrounding structures, such as the sinuses and nerves. This information is essential for determining the best course of action for extraction. For example, if a tooth is close to the sinuses, CBCT can help to determine the risk of sinus perforation

during extraction. Third, CBCT can help to identify any potential complications that may arise during extraction. For example, if a tooth is fractured, CBCT can help to determine the extent of the fracture and whether the tooth is still viable. Overall, CBCT is a valuable tool as it provides a much clearer view of the tooth and surrounding structures than traditional 2D radiographs, and it can help to identify potential complications that may arise during extraction.

The time that the tooth has been out of the socket is also a factor to consider. The success rate of intentional replantation decreases the longer the tooth is out of the socket. Ideally, the tooth should be replanted within 30 minutes of being extracted. In the current report, the time was kept within the recommended range.

In addition to these factors, the patient's overall health and medical history should also be considered. Patients with certain systemic conditions, such as diabetes or compromised immune systems,

may be at an increased risk of complications after intentional replantation.

Conclusion

The decision to pursue intentional replantation should be made on a case-by-case basis, taking into account all of the relevant factors. The results of this study suggest that intentional replantation is a viable option for preserving teeth.

While the results of this study are promising, it is important to note that there is still a risk of failure associated with intentional replantation. The most common reason for failure is vertical root fracture, which can occur if the root is damaged during replantation. The results of these studies will help us to better understand the risks and benefits of intentional replantation and to make more informed decisions about this procedure. Future studies should focus on identifying factors that may influence the success of intentional replantation.

References

1. Paredes-Vieyra J, Enriquez FJ. Success rate of single- versus two-visit root canal treatment of teeth with apical periodontitis: a randomized controlled trial. *J Endod.* 2012;38(9):1164-9.
2. YL, Mann V, Rahbaran S, Lewsey J, Gulabivala K. Outcome of primary root canal treatment: systematic review of the literature - part 1. Effects of study characteristics on probability of success. *Int Endod J.* 2007;40(12):921-39.
3. Gomes B, Herrera DR. Etiologic role of root canal infection in apical periodontitis and its relationship with clinical symptomatology. *Braz Oral Res.* 2018;32(suppl 1):e69.
4. Ng YL, Mann V, Rahbaran S, Lewsey J, Gulabivala K. Outcome of primary root canal treatment: systematic review of the literature -- Part 2. Influence of clinical factors. *Int Endod J.* 2008;41(1):6-31.
5. Ricucci D, Russo J, Rutberg M, Burleson JA, Spangberg LS. A prospective cohort study of endodontic treatments of 1,369 root canals: results after 5 years. *Oral Surg Oral Med Oral Pathol Oral Radiol Endod.* 2011;112(6):825-42.
6. Karaoglan F, Micoogullari Kurt S, Caliskan MK. Outcome of single- versus two-visit root canal retreatment in teeth with periapical lesions: A randomized clinical trial. *Int Endod J.* 2022;55(8):833-43.
7. Brochado Martins JF, Guerreiro Viegas O, Cristescu R, Diogo P, Shemesh H. Outcome of selective root canal retreatment-A retrospective study. *Int Endod J.* 2023;56(3):345-55.
8. Setzer FC, Shah SB, Kohli MR, Karabucak B, Kim S. Outcome of endodontic surgery: a meta-analysis of the literature--part 1: Comparison of traditional root-end surgery and endodontic microsurgery. *J Endod.* 2010;36(11):1757-65.
9. Kohli MR, Berenji H, Setzer FC, Lee SM, Karabucak B. Outcome of Endodontic Surgery: A Meta-analysis of the Literature-Part 3: Comparison of Endodontic Microsurgical Techniques with 2 Different Root-end Filling Materials. *J Endod.* 2018;44(6):923-31.
10. Chen I, Karabucak B, Wang C, Wang HG, Koyama E, Kohli MR, et al. Healing after root-end microsurgery by using mineral trioxide aggregate and a new calcium silicate-based bioceramic material as root-end filling materials in dogs. *J Endod.* 2015;41(3):389-99.
11. Chen I, Salhab I, Setzer FC, Kim S, Nah HD. A New Calcium Silicate-based Bioceramic Material Promotes Human Osteo- and Odontogenic Stem Cell Proliferation and Survival via the Extracellular Signal-regulated Kinase Signaling Pathway. *J Endod.* 2016;42(3):480-6.
12. Edrees HY, Abu Zeid STH, Atta HM, AlQriqri MA. Induction of Osteogenic Differentiation of Mesenchymal Stem Cells by Bioceramic Root Repair Material. *Materials (Basel).* 2019;12(14).
13. Torres FFE, Pinto JC, Figueira GO, Guerreiro-Tanomaru JM, Tanomaru-Filho M. A micro-computed tomographic study using a novel test model to assess the filling ability and volumetric changes of bioceramic root repair materials. *Restor Dent Endod.* 2021;46(1):e2.
14. Torabinejad M, Dinsbach NA, Turman M, Handysides R, Bahjri K, White SN. Survival of Intentionally Replanted Teeth and Implant-supported Single Crowns: A Systematic Review. *J Endod.* 2015;41(7):992-8.
15. Grossman LI. Intentional replantation of teeth. *J Am Dent Assoc.* 1966;72(5):1111-8.
16. Mainkar A. A Systematic Review of the Survival of Teeth Intentionally Replanted with a Modern Technique and Cost-effectiveness Compared with Single-tooth Implants. *J Endod.* 2017;43(12):1963-8.
17. Gorni FG, Gagliani MM. The outcome of endodontic retreatment: a 2-yr follow-up. *J Endod.* 2004;30(1):1-4.
18. Martins JNR, Marques D, Silva E, Carames J, Mata A, Versiani MA. Prevalence of C-shaped canal morphology using cone beam computed tomography - a systematic review with meta-analysis. *Int Endod J.* 2019;52(11):1556-72.
19. Fan B, Ye W, Xie E, Wu H, Gutmann JL. Three-dimensional morphological analysis of C-shaped canals in mandibular first premolars in a Chinese population. *Int Endod J.* 2012;45(11):1035-41.
20. Jang Y, Lee SJ, Yoon TC, Roh BD, Kim E. Survival Rate of Teeth with a C-shaped Canal after Intentional Replantation: A Study of 41 Cases for up to 11 Years. *J Endod.* 2016;42(9):1320-5.
21. Bergenholtz G, Lekholm U, Milthon R, Engstrom B. Influence of apical overinstrumentation and overfilling on re-treated root canals. *J Endod.* 1979;5(10):310-4.
22. Ricucci D, Langeland K. Apical limit of root canal instrumentation and obturation, part 2. A histological study. *Int Endod J.* 1998;31(6):394-409.
23. Ricucci D, Rocas IN, Alves FR, Loghin S, Siqueira JF, Jr. Apically Extruded Sealers: Fate and Influence on Treatment Outcome. *J Endod.* 2016;42(2):243-9.
24. Choi YH, Bae JH, Kim YK, Kim HY, Kim SK, Cho BH. Clinical outcome of intentional replantation

- with preoperative orthodontic extrusion: a retrospective study. *Int Endod J.* 2014;47(12):1168-76.
25. Kingsbury BC, Jr., Wiesenbaugh JM, Jr. Intentional replantation of mandibular premolars and molars. *J Am Dent Assoc.* 1971;83(5):1053-7.
26. Bender IB, Rossman LE. Intentional replantation of endodontically treated teeth. *Oral Surg Oral Med Oral Pathol.* 1993;76(5):623-30.
27. Hayashi M, Kinomoto Y, Miura M, Sato I, Takeshige F, Ebisu S. Short-term evaluation of intentional replantation of vertically fractured roots reconstructed with dentin-bonded resin. *J Endod.* 2002;28(2):120-4.
28. Tsukiboshi M. Autotransplantation of teeth: requirements for predictable success. *Dent Traumatol.* 2002;18(4):157-80.
29. Niemczyk SP. Re-inventing intentional replantation: a modification of the technique. *Pract Proced Aesthet Dent.* 2001;13(6):433-9; quiz 40.
30. Zuolo ML, Ferreira MO, Gutmann JL. Prognosis in periradicular surgery: a clinical prospective study. *Int Endod J.* 2000;33(2):91-8.
31. Cho SY, Lee SJ, Kim E. Clinical Outcomes after Intentional Replantation of Periodontally Involved Teeth. *J Endod.* 2017;43(4):550-5.
32. Park SH, Paek SH, Kim B, Lee JT. Assessment of Bone Height Changes Based on the Cone-Beam Computed Tomography Following Intentional Replantation for Periodontally Compromised Teeth. *Medicina (Kaunas).* 2022;59(1).