



Published: August 31, 2023

Citation: Jimborean OV, Sala DT, et al., 2023. Decrease of Graft Failure Rate by Improving Tactics and Surgical Techniques in Extraanatomic Bypass Operations, Medical Research Archives, [online] 11(8).

<https://doi.org/10.18103/mra.v11i8.4250>

Copyright: © 2023 European Society of Medicine. This is an open-access article distributed under the terms of the Creative Commons Attribution License, which permits unrestricted use, distribution, and reproduction in any medium, provided the original author and source are credited.

DOI

<https://doi.org/10.18103/mra.v11i8.4250>

ISSN: 2375-1924

RESEARCH ARTICLE

## Decrease of Graft Failure Rate by Improving Tactics and Surgical Techniques in Extraanatomic Bypass Operations

**Ovidiu Vasile Jimborean<sup>1</sup>, Daniela Tatiana Sala\*<sup>1</sup>, Cristian Borz<sup>1</sup>, Marton Denes<sup>1</sup>, Mara Andreea Vultur<sup>1</sup>, Gabriela Jimborean<sup>1</sup>, Radu Mircea Neagoe<sup>1</sup>**

<sup>1</sup> Emergency Clinic Hospital Targu Mures

\*Corresponding Author: [salatatiana78@gmail.com](mailto:salatatiana78@gmail.com)

### ABSTRACT

We analyzed the early and late postoperative complications that occurred after 693 bypass operations (574 anatomic and 119 extra-anatomic) performed in 10 consecutive years (1997-2006). The bypass graft failures (infection + thrombosis) treatment and the subsequent evolution of the patients were detected by analyzing patients' readmissions made to solve these major post-bypass complications. The follow-up period extended up to 12 years after the primary arterial bypass reconstruction. In this period we registered: 89 secondary arterial reconstructions for early and late graft thrombosis; 8 healings after removal of the infected prostheses, followed by extraanatomic bypass operations (7 obturator bypass + 1 axillo-bifemoral bypass). The most frequent vascular prosthesis infection sites were the Scarpa triangle and the thoraco-abdominal subcutaneous segment of the axillo(bi)-femoral graft. Major amputations after extraanatomic bypass operations: at 4 years postoperatively for axillo(bi)-femoral operations the amputation rate was 17.6%, while for crossover operations it was 7.5%. Perioperative mortality after anatomic bypass operations = 2 intraoperative and 8 postoperative (1.38%/574 operations); perioperative mortality after extraanatomic bypass operations: 2 postoperative deaths (1.68%/119 operations), 1 after axillo-femoral prosthesis infection and 1 after acute myocardial infarction. In order to reduce the graft major complication rate after extraanatomic bypass operations we took the following measures: 1. When there are arterial occlusive lesions distal to the femoral tripod we ensured an adequate outflow which favors the long-term patency of the extraanatomic graft; this goal was obtained by 2 methods: by enlargement profundoplasty and/or by performing an additional distal bypass towards the popliteal artery or towards the subgenicular arteries. The distal subgenicular anastomosis was made between a venous graft and the distal outflow artery for reducing the intimal hyperplasia. 2. For crossover bypass operations we often used autologous vein grafts; 3. In crossover ilio-femoral bypass operation with venous graft we avoid the graft compression in its path through abdominal wall by passing the graft through a stable caliber hole made in a polypropylene closure mesh of the abdominal wall. 4. We promote the tunneling of the axillo-femoral prosthesis through the subaponeurotic muscular tissue because this tissue better protects the prosthetic graft against infection. 5. In order to reduce the groin prosthesis infections, we prefer performing ilio-femoral crossover bypass instead of femoro-femoral one. 6. The obturator bypass remains a valuable treatment for groin infected prosthesis.

**Keywords:** extraanatomic bypass, crossover bypass, limb-threatening ischemia, graft thrombosis, vascular prosthesis infection, obturator bypass

## Introduction

Peripheral bypass surgery is one of the most used methods for limb salvage in patients with limb-threatening ischemia. Arterial bypass operations can be anatomic, when the vascular grafts bypass adjacent to occluded arterial segments or extraanatomic, when the vascular graft takes over the blood flow from another arterial source, crosses anatomical spaces totally different from those of the occluded artery on its way towards the recipient artery, ensuring the arterial blood supply of the ischemic territory.

Extraanatomic bypass operations are generally indicated in 2 situations: placing a new vascular graft far from an infected site or if the transabdominal surgical approach is prohibitive both in patients with high surgical and anesthetic risks and in patients with difficult local conditions, as previous abdominal operations or non-graftable calcified aorto-iliac arteries.

Both in anatomic and in extraanatomic bypass operations can occur serious postoperative complications (occlusion or vascular graft infections) which can be the cause of major amputation or even postoperative mortality.

The aim of this study is the analysis of these severe complications that occurred after arterial bypass operations: we detected the early and late vascular graft complications that determined the rehospitalization of patients operated with arterial bypass in 10 consecutive years (1997-2006). Late graft complications (infection or occlusion) were detected by analyzing the late readmissions for these major complications; these readmissions appeared after intervals between 4 months and 12 years postbypass operations.

We highlighted the treatment performed for these complications, the result of this treatment, the rate of major amputations and perioperative deaths.

The scope of the study is the improvement of the early and late results of extraanatomic bypass operations.

Being concerned about the unwanted effects of these complications, we took measures (some innovative) to prevent or to decrease these graft failures that can occur after extraanatomic bypass operations: 1. Extensive revascularization by profundoplasty or distal bypass extension of the extraanatomic bypass (both axillo-femoral- and crossover-type) towards popliteal or subgenicular arteries; 2. We increased the use of reversed autologous saphenous vein in crossover bypass of suprainguinal lesions, in parallel with reducing the

use of vascular prostheses ; 3. We tunnelled the axillo-femoral prosthesis through the muscular tissue of the thoraco-abdominal wall; 4. We reduced the rate of groin prosthesis infections by decreasing the groin surgical approach: we favored the crossover prosthetic ilio-femoral bypass and not the classic prosthetic femoro-femoral one; 5. In crossover ilio-femoral bypass the passage of the autologous vein graft through a stable-caliber hole made in a closure mesh of the abdominal wall will prevent the vein graft compression inside the muscular layer of the abdominal wall.

Even if the current study addresses events completed 17 years ago and since 2006 until now many things have changed regarding surgical techniques and graft material's technologies, we decided to present them now for several reasons:

- Many suprainguinal arterial occlusions cannot be solved by the new endovascular revascularization techniques and materials
- The new prosthetic materials used in vascular surgery (cryopreserved homografts, collagen coating sealed on textile vascular grafts, antibiotics coated vascular grafts, silver coated grafts, etc.) are not always available in any vascular surgery department and the reversed autologous saphenous vein remains a costless vascular graft, with reduced thrombogenicity and resistance to infections
- For autologous venous grafts, a postoperative antiplatelet treatment is sufficient; in Europe there is still no consensus concerning post-operative antiplatelet and/or anticoagulant treatment after implantation of a prosthetic vascular graft and we cannot underestimate the hemorrhagic side-effects of a long-term treatment with anticoagulants.
- After 17 years, we have not readmitted patients with complications due to the tactics and techniques used by us to improve the results after extraanatomic bypass operations and to reduce the devastating postoperative complications as graft occlusion or infection.

## Methods

From the electronic registry of operative protocols, we extracted the patients on whom we performed arterial bypass operations in the period 1997-2006; this period of 10 consecutive years began with the introduction of the vascular surgery activity in the 2<sup>nd</sup> Surgery Clinic in Targu Mures, Romania.

### INCLUSION/EXCLUSION CRITERIA:

We included in the analysis:

- Basic data of the patients (degree of limb ischemia, age) who underwent bypass operations

- Types of vascular grafts used in the whole group of bypass operations and we have detailed the types of vascular grafts used in crossover extraanatomic bypass operations
  - We presented the total number of arterial bypass operations performed for primary arterial reconstructions
    - For extraanatomic bypass operations:
      - We have detailed the types of extraanatomic bypass operations depending on the inflow artery
      - We took into account distal revascularization operations (profundoplasty and/or distal bypass), both for axillo- (bi)femoral and crossover types
  - Secondary arterial reconstruction performed for major graft failures (early and late graft occlusions and infections)
    - Definitions:
      - Early graft infection: less than 4 months after bypass
      - Early graft thrombosis: less than 30 days after bypass
    - Late graft failures (graft infections or occlusions) were detected by analyzing the late readmissions for these major complications; these readmissions appeared after intervals between 4 months and 12 years postbypass operations
      - For vascular graft re-occlusions, we have presented the successive operations that were required by the graft re-thromboses
      - For vascular graft infections, we presented the clinical and topographical risk factors for prosthesis infection
  - Perioperative (= operation day 0-30) major amputations and mortality
  - Prophylactic and therapeutic measures against major graft complications
- We excluded from the analysis:
- types of anatomic bypass operations
  - types of vascular grafts used in anatomic bypass operations
- We presented prophylactic and therapeutic measures against major graft failures appeared after extraanatomic bypass operations:
- Favoring a longer patency of the extraanatomic vascular graft by prolonging this graft with an associated distal bypass towards the distal outflow arteries (popliteal artery or subgenicular arteries) and/or by performing an enlargement profundoplasty
  - Enhanced use of use of the autogenous vein grafts even for suprainguinal arterial occlusions treated by extraanatomic bypass operations
  - Intramuscular tunneling of the axillo-femoral prosthesis in its thoraco-abdominal segment
  - Ilio-femoral crossover bypass graft through tension-free abdominal wall-repair mesh (original technique)
  - Decrease of the groin surgical approach by favoring the use of ilio-femoral crossover bypass, along with the decrease use of femoral-femoral crossover bypass when a vascular prosthesis is used
  - Treatment of groin infected prosthesis using obturator bypass operation

## Results

### 1. PATIENTS

- a. Degree of ischemia in patients operated with arterial bypass:
  - There here were 693 patients with anatomic or extraanatomic bypass, of which 90 patients (13%) with intermittent claudication and 603 (87%) with critical limb ischemia
  - 118 extra-anatomic bypass operations were all performed for limb-threatening ischemia
- b. Patients' age:
  - Patients with anatomic bypass > 60 years = 57%
  - Patients with extraanatomic bypass > 60 years = 72%

### 2. GRAFTS USED FOR BYPASS OPERATIONS

- In 693 bypass operations performed for primary arterial reconstruction we used 735 grafts; there were 3 graft types:
- a. **Veins** (reversed autologous saphenous veins) = 280;
  - b. **Vascular prostheses** = 382
  - c. **Composite grafts** = 73: prosthesis proximally + vein distally for profunda femoris, popliteal and infragenicular anastomosis (figure 2)
  - d. Among the 455 vascular prostheses there were 12 Polytetrafluoroethylene (PTFE) and 443 Polyethylene terephthalate (Dacron) prostheses

**TOTAL VASCULAR GRAFTS = 735**  
**- veins = 280**  
**- prostheses = 382**  
**- mixed (composite) grafts = 73 (prosthesis proximally + vein distally)**

Figure 1

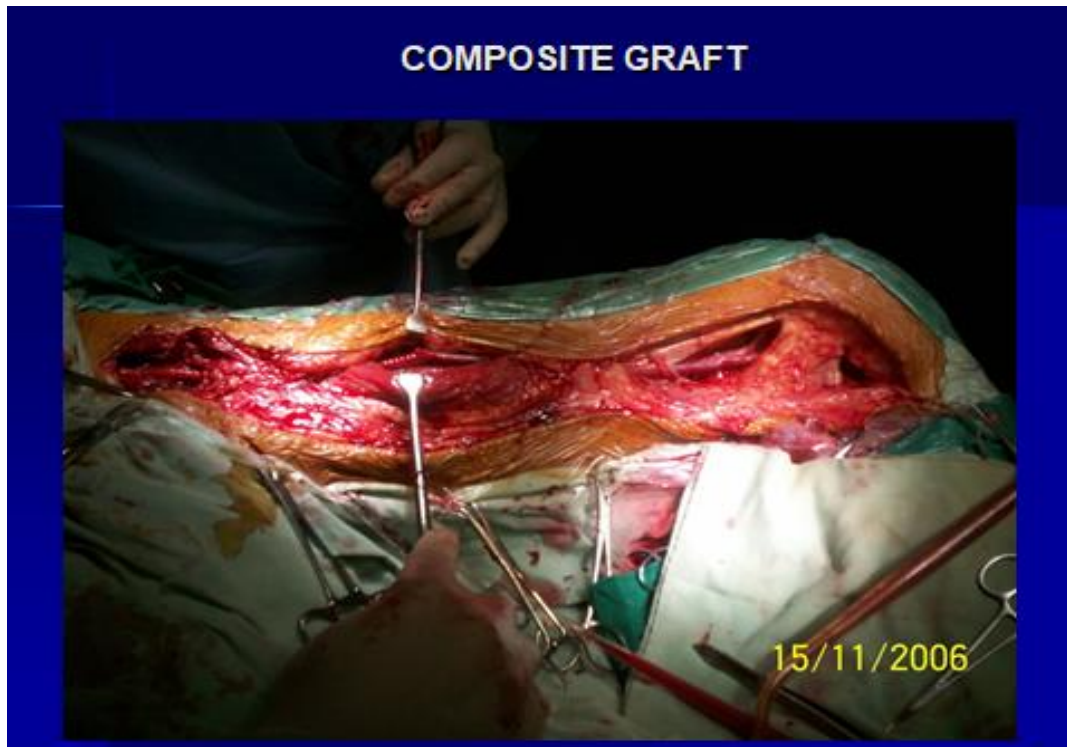


Figure 2

**1. Primary arterial reconstructions using anatomic and extraanatomic bypass:**

We performed 693 bypass operations which are divided into 2 categories:

- a. 574 anatomic bypass operations which corrected both aorto-iliac and infrainguinal arterial occlusive lesions
- b. 119 extraanatomic bypass operations (figure 3):

After completing the extraanatomic bypass operation, we extended distally the extraanatomic graft by performing additional distal anatomic bypass towards the popliteal artery or towards the infragenicular outflow arteries; thus, we extended the extraanatomic bypass (both axillo-femoral type and crossover type) with 56 additional distal bypass operations for these bypass operations on the subgenicular arteries we have always used reversed autologous veins or

composite grafts. In order to provide an extended outflow, we also performed 12 profundoplasties.

**2. Major vascular graft failures after primary arterial reconstructions**

**a. Vascular prosthesis infection**

**4.a.1. Vascular prosthesis infection risk-factors (figure 4):**

- vascular prosthesis infections appeared with a predilection in the Scarpa triangle and in the thoraco-abdominal subcutaneous segment of axillo(bi)-femoral prostheses
- all patients with prosthesis infections were smokers
- prosthesis infections frequently occurred in patients with diabetes mellitus and distal septic lesions

EXTRAANATOMIC BYPASS OPERATIONS: TYPES AND INDICATION		
"Donor" artery	Indication	Operation type
Carotid artery = 1 operation	Subclavicular steal syndrome	Carotid-subclavian bypass
Axillar artery = 51 operations	-Coronary heart disease: 95 -Severe chronic obstructive pulmonary disease: 16	Axillo(bi)-femoral bypass +/- distal extension
Femoral or iliac artery = 67 operations	-"Hostile" abdomen = previous abdominal operations: 3 -Calcified aorta: 4	Crossover bypass +/- distal extension
Femoro-femoral = 49 operations		
Ilio-femoral = 18 operations		

Figure 3

PROSTHESIS INFECTIONS: RISK-FACTORS		
	EARLY INFECTIONS	LATE INFECTIONS
GROIN LYMPHORAGIA		12
SUBCUTANEOUS AXILLO-FEMORAL PROSTHESIS	1	7
DIABETES MELLITUS	2	6
DISTAL LIMB INFECTIONS	4	6
TOBACCO SMOKERS	7 – 100%	18 – 100%

Figure 4

#### 4.a.2. Vascular prosthesis infections: treatment and results (figure 5)

Vascular prosthesis infections in anatomic and extraanatomic bypass operations: treatment and results
<ul style="list-style-type: none"> <li>■ <b>EARLY INFECTIONS: 7</b> <ul style="list-style-type: none"> <li>– 3 deaths (septic shock)</li> <li>– 4 major amputations after infected prosthesis removal</li> </ul> </li> <li>■ <b>LATE INFECTIONS: 18</b> <ul style="list-style-type: none"> <li>– 8 major amputations</li> <li>– 10 healings:                             <ul style="list-style-type: none"> <li>■ 7: obturator bypass</li> <li>■ 2: infected prosthesis removal + local treatment + rebypass with autologous vein</li> <li>■ 1: aortic infected prosthesis removal + axillo-bifemoral bypass</li> </ul> </li> </ul> </li> </ul>

Figure 5

**b. Graft occlusions: secondary arterial reconstructions (SAR) for patients with early and then late graft occlusions (figure 6)**

EARLY AND LATE SECONDARY ARTERIAL RECONSTRUCTIONS (SAR) FOR GRAFT THROMBOSIS				
Primary reconstructions + bypass graft	Early SAR: 15	Results	Late SAR: 64 From 4 months to 9 years	Results (+10 rereop)
3 BP with "in situ" devalved vein	3 reBP with prosthesis			
68 BP with prostheses	10 (Fogarty)	- 2 AMP -1BP with prosthesis	36 T (Fogarty)  23 reBP  3T+ extended distally the BP	4 Fogarty + 1 reBP - 10 AMP  - 5 reBP - 8 AMP
BP = bypass, TEA = thrombendarterectomy, AMP =major amputation, rereOp = successive reoperations, T Fogarty = thrombectomy				

Figure 6

**2. Graft failures after extraanatomic bypass operations**

**5.1. Graft infections after extraanatomic bypass operations**

After 119 extra-anatomic bypass operations we recorded 8 late vascular prosthesis infections (6.1%) that appeared from 16 months to 4 years after operation. These vascular prosthesis infections occurred in patients with axillo(bi)-femoral bypass at the level of the thoraco-abdominal subcutaneous segment

**5.2. Graft occlusions after extraanatomic bypass operations**

- 12 patients were reoperated for 1 early thrombosis and 11 late thrombosis;
- the early thrombosis installed on a femoro-femoral crossover Dacron prosthesis and was treated with Fogarty thrombectomy
- 11 late graft thromboses appeared from 5 to 44 months postoperatory on 1 vein graft and on 10 Dacron vascular prostheses
- the occluded venous graft in an ilio-femoral crossover bypass: it seemed to be compressed inside its passage through abdominal wall and was replaced by PTFE vascular graft
- the other 10 prosthetic graft late occlusions affected axillo(bi)-femoral grafts; the blood flow was restored by Fogarty thrombectomy
- all these patients were readmitted several times for subsequent thrombectomies; for all these patients we performed late major amputations

**6. Major amputations after extraanatomic bypass operations**

At 4 years postoperatively: for axillo(bi)-femoral operations the amputation rate was 17.6%, while for "crossover" operations it was 7.5%.

**6.1. Major amputations for severe limb ischemia due to grafts' occlusion**

- All occluded grafts were of Dacron
- 6 axillo-femoral occluded prosthetic grafts and 4 femoro-femoral crossover occluded prosthetic grafts led to major amputations

**6.2. Major amputations for prosthesis infections after removal of the infected prosthesis**

- All infected grafts were of Dacron
- There were
  - o 1 early + 5 late vascular prosthesis infections occurred in patients with axillo(bi)-femoral grafts; the infection sites were located on the thoraco-abdominal subcutaneous segment of the prosthesis
  - o 2 late femoro-femoral crossover prosthetic graft infections

**7. Perioperative mortality**

**7.1. Perioperative mortality after anatomic bypass operations**

- 2 intraoperative mortality (ruptured abdominal aortic aneurysms)
- 8 postoperative deaths (1.38%/574 operations)

- 6 acute myocardial infarctions
- 2 early prosthesis infections

### 7.2. Perioperative mortality after extraanatomic bypass operations

- No intraoperative mortality
- 2 postoperative deaths (1.68%/119 operations):
- 1 patient had an early axillo-femoral prosthesis (Dacron) infection. After the removal of the infected prosthesis we had to make a major amputation: after the amputation, the ischemic thigh stump did not heal and the patient died in septic shock
- 1 patient died in the 10<sup>th</sup> postoperative day with acute myocardial infarction after axillo-bifemoral bypass

### 8. Prophylactic and therapeutic measures against major graft failures

#### 8.1. Enhanced use of use of venous grafts in bypass operations even for suprainguinal arterial occlusions

Beginning with 2002, we started to use autologous vein grafts more, even to bypass the suprainguinal lesions, in order to decrease prosthesis thrombosis and infection rate. We used 32 vein grafts to bypass suprainguinal lesions, of which 26 in extraanatomic crossover bypass operations.

We found that a slight increase (10%) of venous grafts use, in parallel with a slight decrease (10%)

of vascular prostheses use in the period 2002-2006 compared to the previous period 1997-2001 led to an important decrease (50%) of the secondary arterial reconstruction rate imposed by graft thrombosis or infection (figure 7).

#### 8.2. Intramuscular tunneling of the axillo-femoral prosthesis in its thoraco-abdominal segment

In 28 patients with axillo(bi)-femoral bypass operated in the first 5 years of the studied period we found 1 early and 5 late prosthesis infections. These infections were located in the thoraco-abdominal segment, where the vascular prostheses were classically tunneled through the subcutaneous tissue.

The early axillo-femoral prosthesis infection determined the death of the patient due to septic shock, and the late infections led to major amputations after the removal of the infected prosthesis.

Beginning with 2003 we have tunneled the axillo-femoral prostheses through the subaponeurotic muscular tissue for its better antiinfectious graft protection (figure 8); after this surgical technique change, the other 23 axillo(bi)-femoral bypass operations were not complicated, neither by early, nor by late prosthetic infection.

VEIN GRAFTS USE/ LATE GRAFT THROMBOSIS RATE	
TOTAL VASCULAR GRAFTS = 735 - veins = 280 - prostheses = 382 - mixed (composite) grafts = 73 (prosthesis proximally + vein distally)	
1997-2001	2002-2006
107 veins/295 grafts = 36.3%	173 veins/367 grafts ↑ = 47.1%
188 prostheses/grafts = 63.7%	194 prostheses/367 grafts ↓ = 52.9%
49 secondary reconstructions for late graft thrombosis/295 grafts = 16.6%	30 secondary reconstructions for late graft thrombosis/367 grafts ↓ = 8.1%

Figure 7

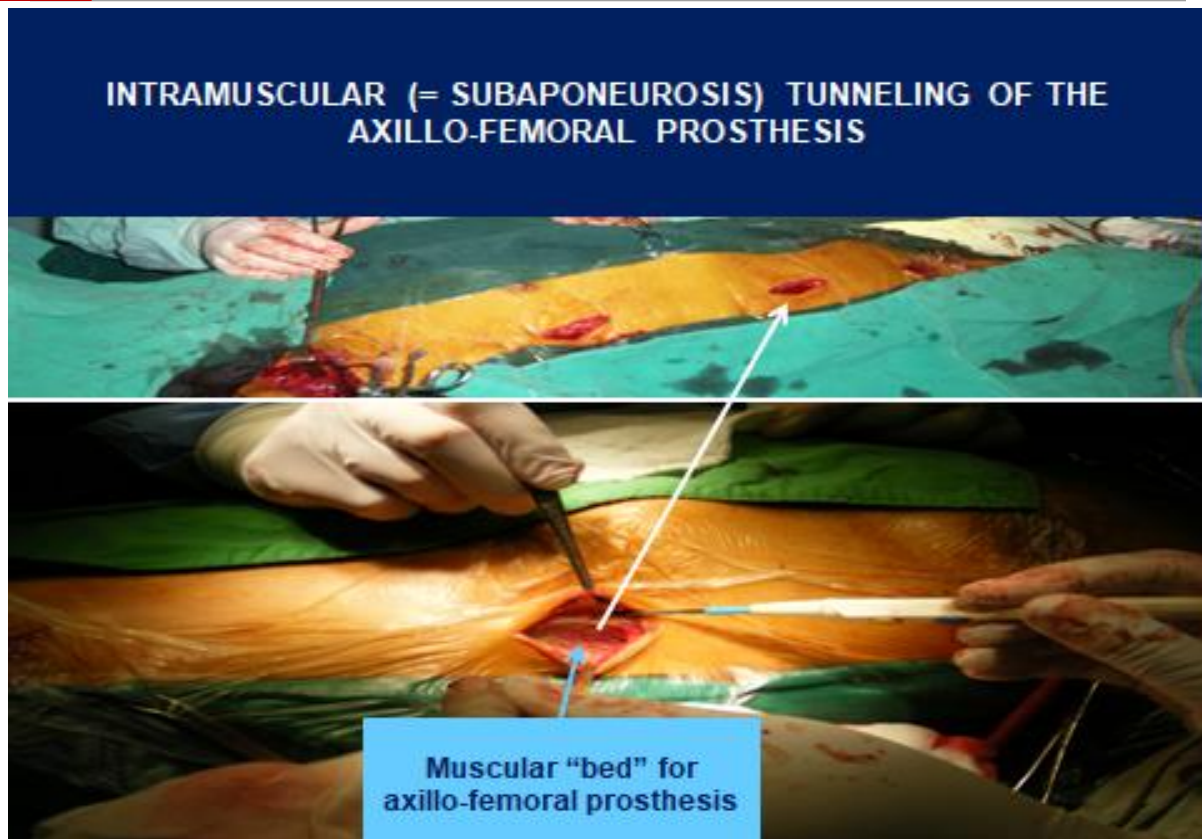


Figure 8

**8.3. Decrease of the groin surgical approach by favoring the use of ilio-femoral crossover bypass, along with the decrease use of femoro-femoral crossover bypass (figure 9)**

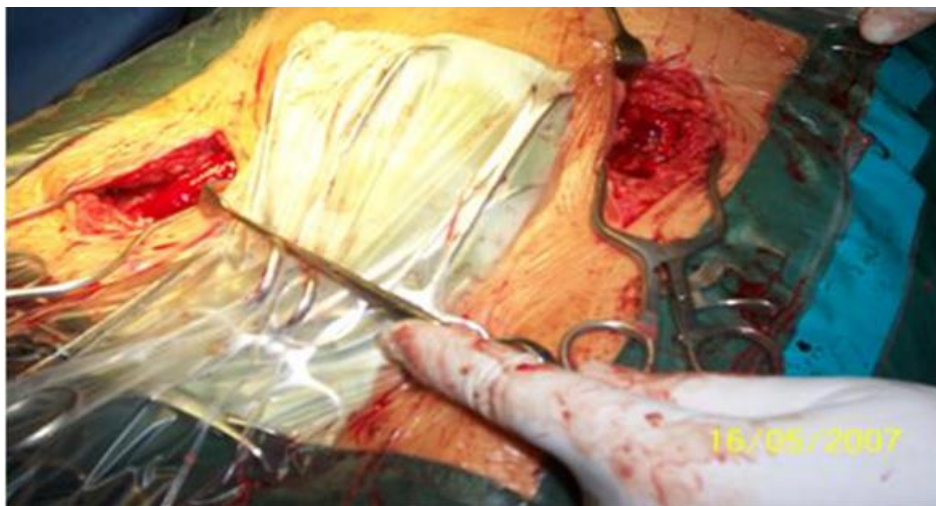


Figure 9

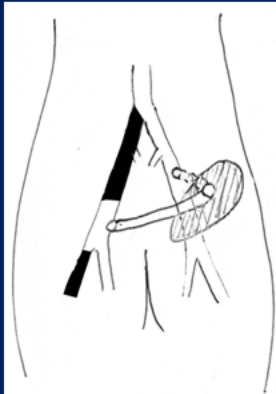The surgical approach of Scarpa triangle (groin) for performing bypass operations led to 12 late prosthesis infections. The ilio-femoral crossover bypass has the advantage to affect only 1 Scarpa triangle, comparing with the classic femoro-femoral bypass; in our study we have 18 ilio-

femoral crossover bypass operations and 49 femoro-femoral crossover bypass operations.

**8.4. Ilio-femoral crossover bypass graft through tension-free abdominal wall-repair mesh (original technique)**



Schematic presentation of the original operation:  
Ilio-femoral crossover bypass graft through tension-free abdominal wall-repair mesh



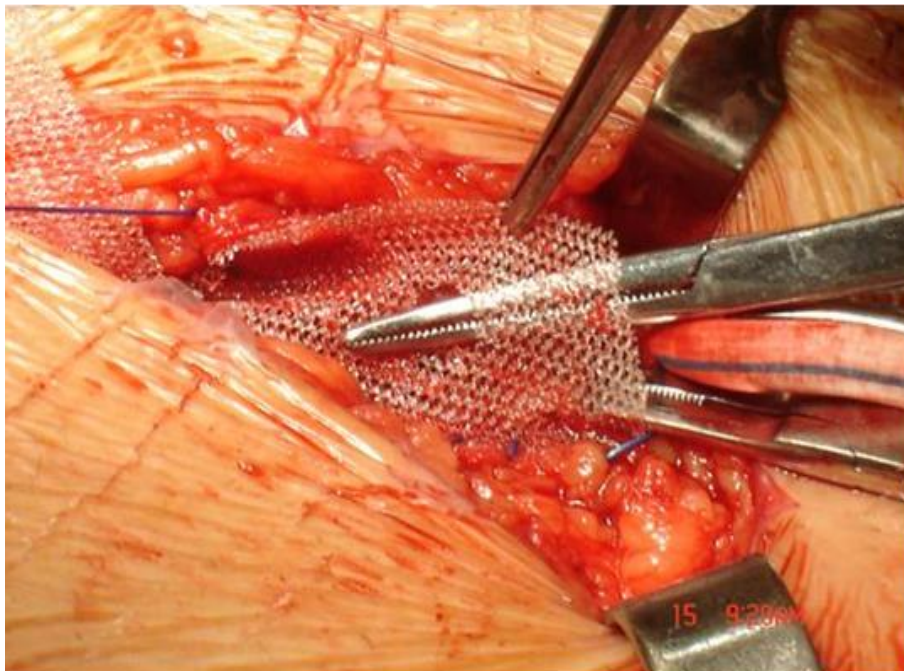
**Figure 10**

We operated 6 patients with comorbidity: inguinal hernia and contralateral critical limb ischemia and we decided to solve the 2 diseases in one operation: hernia treatment + ilio-femoral crossover bypass.

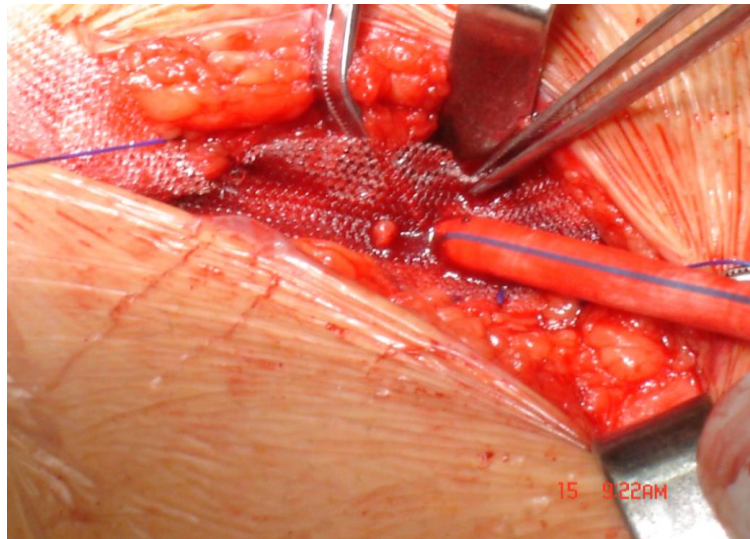
The steps for this operation were:

- a. After herniotomy we prepared the external iliac artery as the donor artery for the crossover bypass
- b. Prepare the contralateral femoral femoral

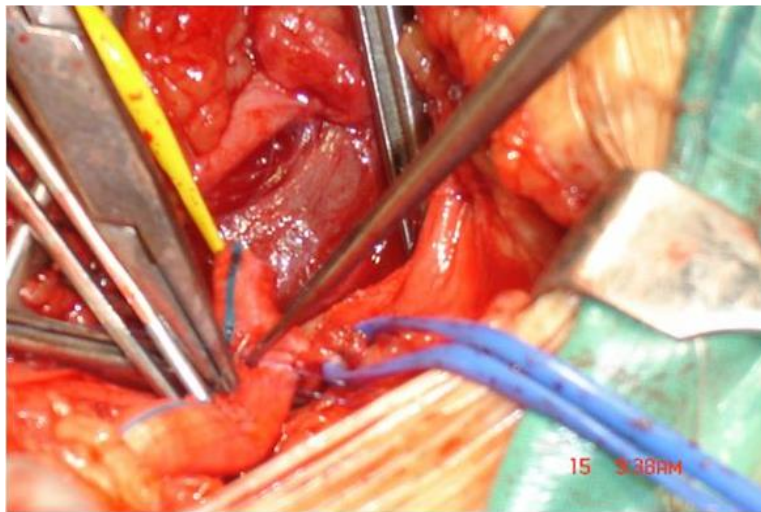
- c. bifurcation as recipient (outflow) artery
- c. Proximal iliac-graft side-to-end anastomosis
- d. Exteriorization of the vascular graft through a calibrated hole (figure 11) made in a Polypropylene mesh which closed the abdominal wall (figure 12)
- e. The transfer of the vascular graft towards the contralateral femoral bifurcation through the prepubic subcutaneous tissue
- f. Distal graft-femoral end-to-side anastomosis (figure 13)



**Figure 11**



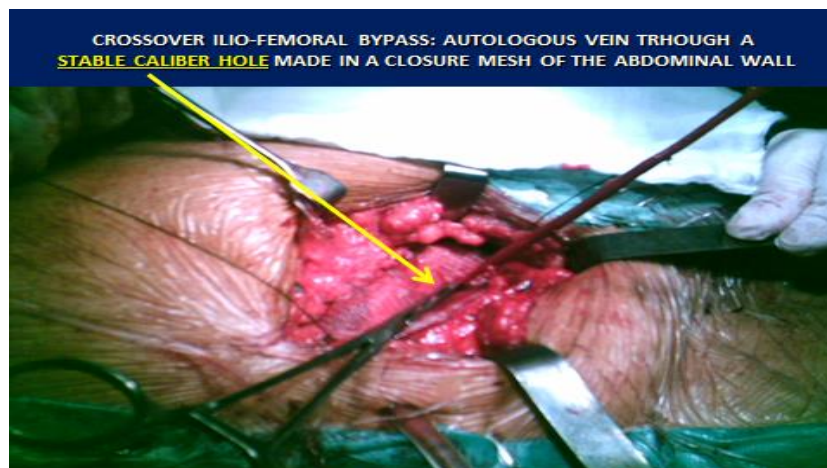
**Figure 12**



**Figure 13**

Seeing that this crossover bypass technique is feasible, we operated with this technique 6 more patients with critical ischemia, but without inguinal hernia; for 4 of these patients this operation was the primary arterial reconstruction and for the

other 2 patients this operation was a reoperation after the occlusion of a branch of an aorto-bifemoral prosthesis. In these 12 crossover bypass operations we used 5 vein autografts (figures 14, 15) and 7 prosthetic grafts.



**Figure 14**

### AUTOLOGOUS VEIN GRAFT USED IN ILIO-FEMORAL CROSSOVER BYPASS

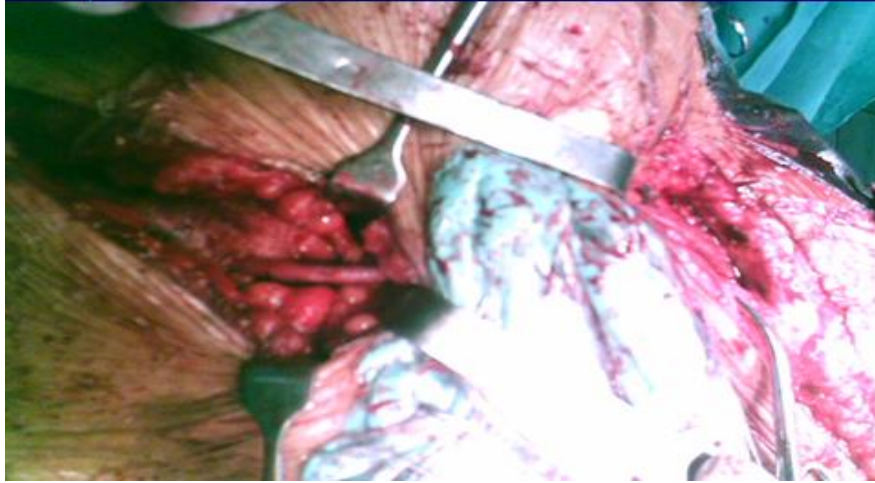


Figure 15

Post operative complications: 3 patients returned with late graft thrombosis, 1 with vein graft, 2 with prosthetic grafts; all cases had poor artery outflow (profunda femoris was used as recipient artery for these limb salvage operations).

#### 8.5. Treatment of groin infected prosthesis using obturator bypass

After anatomic bypass operations 12 patients returned at intervals between 2-4 years with late prosthesis infections located in the Scarpa triangle (groin). In 2 patients, the infection determined the exteriorization of the infected prosthesis (figure

16), and 10 patients returned with infected pseudoaneurysms (figure 17). In 5 patients we removed the infected prosthesis, which then required major amputations.

In 7 patients we performed obturator bypass and removal of the groin infected segment of the vascular prosthesis. We used this method in order to place the new uninfected graft at a sure distance from the groin infected site.

Patients operated with obturator bypass had no early complications and did not return with late complications

### Late groin prosthesis infection

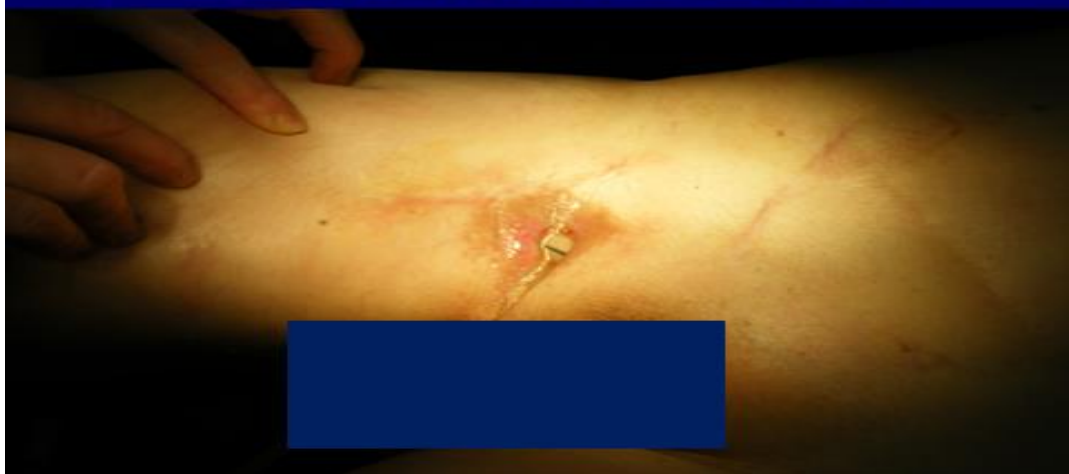

Figure 16

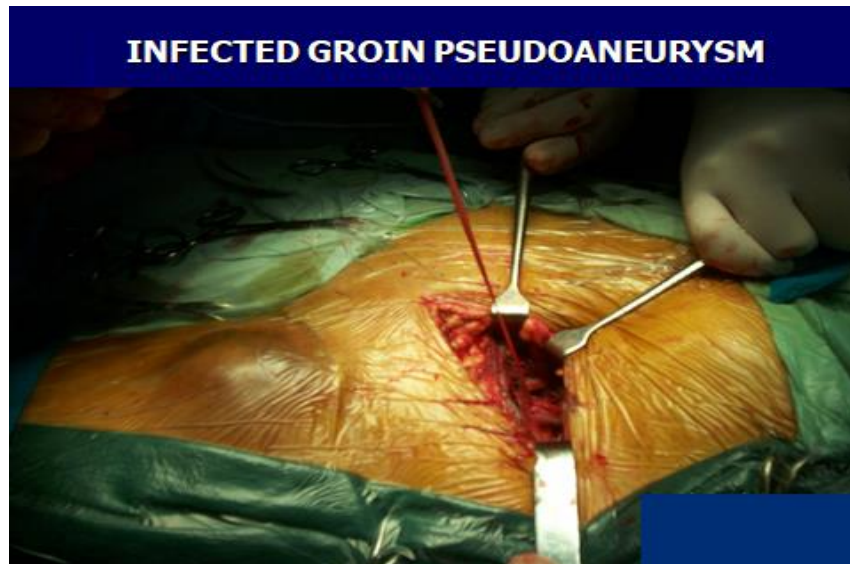

Figure 17

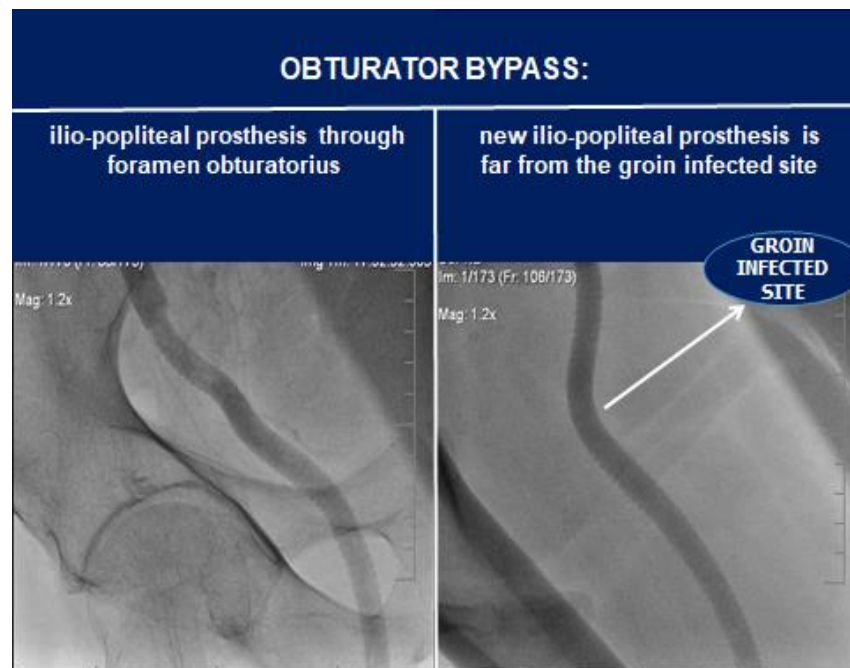


Figure 18

## Discussion

### a. Indications for extraanatomic bypass operations

Extraanatomic bypass operations are generally used as limb salvage operations in anesthetic and surgical high-risk patients (1-3).

These operations are also useful in patients with a prohibitive transabdominal approach (abdominal operations in their history or calcified, non-graftable aorto-iliac arteries), or in patients with infected vascular prostheses, where we performed the obturator bypass (4).

The patients in whom advanced age is a major risk-factor for trans-abdominal surgical approach have a complex of comorbidities as severe COPD +/- ischemic heart disease +/- diabetes etc. (5); in our study 72% of the patients had over 60 years.

In our research the extraanatomic bypass operations had 2 indications:

#### a. General indications:

- i. **High-risk patients** (coronary heart disease, severe chronic pulmonary disease).

If in literature (6) severe chronic obstructive pulmonary disease (COPD) and coronary heart disease have close percentages (20 - 30%) as indications for extraanatomic bypass, in our research there were 95 (80.5%) patients with coronary heart disease, 16 (13.5%) with severe COPD.

**ii. Local particular conditions:**

- multiple abdominal operations in patients' history ("hostile" abdomen) in 3 patients (2.5%)
- calcified, non-graftable aorta in 4 patients (3.5%)

**b. Patients with infected vascular prostheses:**

we didn't have cryopreserved homografts or vascular prostheses with anti-infectious properties coatings (silver-coated, rifampicin coated ) prostheses for "in situ" replacement the groin infected prostheses (7-9), so in 7 patients we performed the obturator bypass with good early and late results.

**1. Vascular grafts:** in peripheral bypass operations, we used 3 types of vascular grafts: autologous reversed greater saphenous veins, prosthetic grafts, composite grafts. In the extraanatomic bypass operations performed for the treatment of some suprainguinal arterial occlusions, we exclusively used vascular prostheses for the axillo(bi)-femoral operations and for crossover operations (ilio- or femoro-femoral) we used both vascular prostheses and autologous venous grafts.

**a. The autologous vein grafts**

In literature human saphenous vein grafts is considered to be one of the salvage bypass conduits when endovascular procedures are not feasible or fail; the remodeling process that venous grafts undergo during exposure to arterial conditions is crucial to improve their patency, which is often compromised by intimal hyperplasia (10). Other authors consider that saphenous vein offers the most durable conduit for reconstruction; 5-year failure rates are 30-50% and have remained largely unchanged for the past two decades (11). The main clinical risk factor in peripheral vascular graft occlusion is considered to be tobacco smoking: the overall effect of smoking shows a 2.35-fold increase in risk of graft failure (12).

In our experience the reversed autologous saphenous vein proved to provide multiple advantages: autologous veins are costless, they are much less thrombogenic and much more resistant to infections than vascular prostheses (13). These advantages have been confirmed by other authors: among patients with chronic limb

threatening limb ischemia who had an adequate great saphenous vein for surgical revascularization, the incidence of a major adverse limb event or death was significantly lower in the surgical group than in the endovascular group (14).

Knowing these advantages, we used venous grafts as much as possible (even to bypass the suprainguinal occluded arteries), in parallel with the decreased use of vascular prostheses and we noticed the following results:

- I. The slight increase of the vein grafts use in parallel with a slight decrease of the prostheses use in bypass operations led to an important decrease of the reoperations imposed by the graft thrombosis
- II. We had only 3 early vein graft thrombosis/total of 280 vein grafts used in bypass operations and these graft failures were due to technical errors (incorrect devalve operation of these "in situ" placed veins. The late vein graft thrombosis in 1 patient with crossover ilio-femoral bypass seemed to be due to a graft compression in its crossing path through the abdominal wall towards the contralateral femoral artery. This compression can be avoided when the vein graft from the retroperitoneum crosses this level through a stable caliber hole made in polypropylene mesh that closes the abdominal wall (15).
- III. In our study we didn't notice any vein graft infection; on the contrary, we have successfully used autologous saphenous vein to replace an infected segment of the vascular prosthesis after debridement of the infected site.

**b. Vascular prosthetic grafts** use has disadvantages when is compared to the venous grafts use: thrombosis and infection rates of are more common, especially with Dacron prostheses and less so with PTFE ones (16).

- I. the thrombogenicity of vascular prostheses requires multiple postbypass thrombectomies or successive rebypass operations and frequently determines the indication for major amputations
- II. The vascular graft prosthesis infection represents a severe postbypass complication, followed by a high rate of major amputation and mortality (17).

**c. The composite** grafts (18) were used for distal revascularization in some patients who presented infrainguinal occlusive lesions associated to the iliac occlusions that were resolved in a first operative time by the extraanatomic bypass; in these patients, the autologous saphenous graft was not long enough to reach from the femoral tripod to the popliteal or subpopliteal recipient artery. This operative tactic was used to improve the arterial outflow tree, which is known to be important for a longer-term patency of the vascular grafts (19). It was indicated to perform a distal veno-arterial anastomosis on the popliteal or subpopliteal recipient arteries in order to reduce the distal intimal hyperplasia, which is more accentuated on a prosthetic-arterial anastomosis (20,21). We used composite grafts in 5 patients where the distal anastomoses were performed on infragenicular arteries

### **3. Major amputations and perioperative mortality after extraanatomic bypass operations**

#### **a. Major amputations:**

- Of the 130 patients with extraanatomic bypass operations (primary + secondary arterial reconstructions), 17 (= 13.8%) required major amputations, 10 for graft occlusions and 7 for graft infections at 4 years after operation; in literature the major amputation rate after extraanatomic bypass operations exceeds 16% (22) at 4 years after operation (22).
- in our research we found that the amputation rate is higher for axillo(bi)-femoral bypass operations than for crossover ones: at 4 years postoperatively: for axillo(bi)-femoral operations the amputation rate was 17.6%, while for "crossover" operations it was 7.5%; these data are similar with those in the literature (23,24)

#### **b. Perioperative mortality:**

- in our research we didn't have any intraoperative deaths during the performance of extraanatomic bypass operations
  - postoperative mortality in patients undergoing extraanatomic bypass operations varies in the literature between 0 - 4% for crossover interventions and between 2 - 11% for axillo-bifemoral operations.
- In our research we had 2 early postoperative deaths/119 patients after extraanatomic bypass operations performed as primary arterial

reconstructions, which represents 1.68%/119 operations. In literature we found that mortality at operation day 0-30 days is around 8% (25,26)

### **4. Prophylactic and therapeutic measures against major graft failures in extraanatomic bypass operations**

#### **a. Prevention of graft occlusion**

i. The advantages of reversed autologous saphenous vein grafts are recognized in the literature and they were previously shown: they are costless, low-thrombogenic and resistant to infections.

Long term patency of the autogenous vein grafts can often be ensured only with antiplatelet treatment and there is no need for anticoagulant treatment in high doses, which is required in the case of the use of vascular prostheses.

In elderly, frequently hypertensive patients, the post-bypass anticoagulant treatment has can have a hemorrhagic side-effect; the bleeding risk assessment is not standardised and likely underestimated (27).

We extended the use of autologous vein grafts even for bypassing the suprainguinal arterial occlusions in crossover ilio-femoral or crossover femoro-femoral bypass operations; we didn't find this attitude in international literature.

In the crossover ilio-femoral bypass operation, we passed the vascular graft through a hole made in a closure mesh of the abdominal hole. Initially, we imagined this technique to solve 2 different diseases in a single operation: inguinal hernia and contralateral peripheral chronic ischemia due to iliac artery occlusion. The polypropylene mesh closed the abdominal wall in a tension-free manner during the hernioplasty (28) and the extraanatomic ilio-femoral crossover graft passed through this mesh. Later, we successfully extended this bypass technique to patients with chronic peripheral ischemia, but without associated inguinal hernia. This technique has an advantage when a vein graft is used in ilio-femoral crossover bypass: venous graft crosses the abdominal wall through a stable calibrated hole made in the mesh and so it avoids to be compressed after the direct suture of the abdominal wall: this compression (followed by a late venous graft occlusion) appeared in a patient 2 months after the operation

ii. A permissive and large outflow represents an appropriate parameter for the long-term patency of vascular grafts (29). In this sense, we extended the extraanatomical grafts distally, both after the completing the axillo(bi)-femoral bypass and after the crossover bypass. In our case report we used the extension of the extraanatomic graft by performing an additional distal bypass from the femoral tripod towards the popliteal artery or towards the subpopliteal arteries in 56 patients; the longest graft was in a patient in whom we performed an axillo-femoral-popliteal-tibioperoneal trunk bypass (the last segment was done by using a composite jump graft = vascular prosthesis until supragenicular popliteal artery continued with reversed autogenous vein until the tibio-peroneal trunk). Usually, we used composite grafts when the distal bypass was anastomosed to the popliteal or infragenicular level and when the autogenous reversed vein is not long enough to reach the infragenicular recipient artery. In order to improve the outflow on the femoral tripod, we performed angioplasty to enlarge the recipient deep femoral artery in 12 patients before performing the anastomosis between the extraanatomic graft and the femoral tripod.

#### **b. Prevention of prosthetic graft infection**

i. The axillo(bi)-femoral prosthesis infections were frequently located in the subcutaneous thoraco-abdominal segment. In order to avoid this severe complication we tunneled the prosthesis in a "sublay" fashion through the subaponeurotic muscular tissue, which better protects the prosthesis against infections (30,31).

ii. Groin represents a frequent site of vascular prosthesis infections (32,33). When intending to perform a crossover bypass with a prosthetic graft, it is more advantageous to use an ilio-femoral crossover bypass instead of a femoro-femoral one, since we surgically approach only 1 and not 2 groins

#### **c. Treatment of groin infected prosthesis using obturator bypass operation**

Obturator bypass remains a valuable operation for the treatment of groin prostheses infection (34,35). By performing this operation, the groin infected prosthetic segment is removed and the new trans-

obturator ilio-popliteal prosthesis that ensures the restoration of blood flow is located at a safe distance from the infected site located in the Scarpa triangle. This operation avoids the use of cryopreserved homografts or silver/antibiotic-coated prosthetic grafts that are rarely available or more expensive than an usual vascular prosthesis used in obturator bypass. In our study we successfully treated 7 groin prosthesis infections using this technique.

## **Conclusions**

1. When there are arterial occlusive lesions distal to the femoral tripod, it is necessary to ensure an adequate outflow which favors the long-term patency of the extraanatomic graft; this goal can be obtained by 2 methods: by enlargement profundoplasty and/or by performing an additional distal bypass towards the popliteal artery or towards the subgenicular arteries. The distal subgenicular anastomosis will be made between a venous graft and the distal outflow artery in order to reduce the distal intimal hyperplasia of the graft.
2. The more frequent use of the reversed autologous vein in crossover bypass operations performed for suprainguinal arterial occlusions has 2 major advantages over the use of vascular prostheses: the lower rate of graft thrombotic-occlusions and the avoidance of serious vascular prosthesis infections.
3. In the crossover ilio-femoral bypass operation in which the autologous venous graft is used, compression of the vein graft may occur during its passage through the musculo-aponeurotic layer of the abdominal wall; in order to avoid this complication, we passed the venous graft through a stable caliber hole made in a polypropylene closure mesh of the abdominal wall.
4. After the axillo(bi)-femoral bypass, vascular prosthesis infections occur in the passage of the prosthesis through the thoraco-abdominal subcutaneous tissue; to prevent the occurrence of these prosthesis infections, we promote the tunneling of the axillo-femoral prosthesis through the subaponeurotic muscular tissue because this tissue offers a better antiinfection protection.
5. The groin is a place where vascular prosthesis infections frequently occur. To reduce the rate of these infection locations, we prefer to perform the ilio-femoral crossover bypass instead of the femoral-femoral one

6. The obturator bypass remains a valuable procedure for the treatment of groin infected prosthesis.

## Conflict of Interest

“The authors have no conflicts of interest to declare.”

## References

1. Keun Her, ChangWoo Choi, YoungWoo Park, HwaKyun Shin, YongSoon Won: Concomitant Peripheral Artery Disease and Asymptomatic Coronary Artery Disease: A Management Strategy. *Ann Vasc Surg.* 2008 Sep; 22(5):649-56. doi: 10.1016/j.avsg.2008.01.010
2. Biancari F, Lepantalo M: Extra-anatomic bypass surgery for critical leg ischemia. A review. *J Cardiovasc Surg.* 1998; 39: 295-301
3. Daumerie G, Fleisher LA: Perioperative [beta]-blocker and statin therapy. *Curr Opin Anaesthesiol.* 2008;21(1):60-5. doi: 10.1097/ACO.0b013e3282f35ea5
4. Rutherford RB: Extra-anatomic Bypass, in Rutherford R. B. (ed.): *Vascular Surgery*, 2000: 990-992
5. Yasa KP, Christopher Ryalino C: Extra-Anatomic Axillofemoral Bypass After Failed Stenting for Aortoiliac-Occlusive Disease in a Patient with Severe Comorbidities. *Am J Case Rep.* 2020; 21: e925009-1–e925009-5. Published online 2020 Aug 17. doi: 10.12659/AJCR.925009
6. Hertzner NR, Bena JF, Karafa MT: A personal experience with direct reconstruction and extra-anatomic bypass for aortoiliac occlusive disease. *J Vasc Surg.* 2007; 45 (3):533-535
7. Dosluoglu HH, Kittredge J, Cherr GS: Use of Cryopreserved Femoral Vein for In Situ Replacement of Infected Femorofemoral Prosthetic Artery Bypass. *Vasc Endovasc Surg.* 2008 Feb-Mar;42(1):74-8. doi: 10.1177/1538574407308204
8. Zetrenne S, Wirth GA, McIntosh BC, Evans G R D, Narayan D: Managing Extracavitary Prosthetic Vascular Graft Infections. *Ann Plast Surg.* 2006;57(6): 57(6):677-82. doi: 10.1097/01.sap.0000226928.10734.ae
9. Molacek J, Treska V, Houdek K, Opatrný V, Certik B, Baxa J: Use of a Silver-Impregnated Vascular Graft: Single-Center Experience. *Antibiotics* (Basel). 2022; 11(3), 386; <https://doi.org/10.3390/antibiotics11030386>
10. Berard X, Déglise S, Alonso F, Saucy F, Meda P, Bordenave L, Corpataux JM, Haefliger JA: Role of hemodynamic forces in the ex vivo arterialization of human saphenous veins. *J Vasc Surg.* 2013 May; 57(5):1371-82. doi: 10.1016/j.jvs.2012.09.041
11. Owens CD, Ho KJ, Conte MS: Lower extremity vein graft failure: a translational approach. *Vasc Med.* 2008 Feb;13(1):63-74. doi: 10.1177/1358863X07083432
12. Fatourou EM, Paraskeva KI, Seifalian AM, Hamilton G, Mikhailidis DP: The role of established and emerging risk factors in peripheral vascular graft occlusion. *Expert Opin Pharmacother.* 2007 May; 8(7):901-11. doi: 10.1517/14656566.8.7.901
13. Sharrock M, Antoniou SA, Antoniou GA: Vein Versus Prosthetic Graft for Femoropopliteal Bypass Above the Knee: A Systematic Review and Meta-Analysis of Randomized Controlled Trials. *Angiology.* 2019; 70(7):649-661. doi: 10.1177/0003319719826460. Epub 2019 Jan 31
14. Farber A, Menard MT, Conte MS, Kaufman JA, Powell RJ, Choudhry NK, Hamza TH, Assmann SF, Creager MA, Cziraky MJ, Dake MD, Jaff MR, Reid D, Siami FS, Sopko G, White CJ, Max van Over, Strong MB, Villarreal MF, McKean M, Azene E, Azarbal A, Barleben A, Chew DK, Clavijo LC, Douville Y, Findeiss L, Garg N, Gasper W, Giles KA, Goodney PP, Hawkins BM, Herman CR, Kalish AJ, Koopmann MC, Laskowski IA, Mena-Hurtado C, Motaganahalli R, Rowe VL, Schanzer A, Schneider PA, Siracuse JJ, Venermo M, Rosenfield K: Surgery or Endovascular Therapy for Chronic Limb-Threatening Ischemia. *N Engl J Med.* 2022 Dec 22;387(25):2305-2316. doi: 10.1056/NEJMoa2207899. Epub 2022 Nov 7
15. Muresan M, Jimborean O, Jimborean G, Neagoe R, Bancu S, Muresan S, Borz C: Crossover iliofemoral bypass graft through tension-free abdominal wall-repair mesh. *Ann Ital Chir.* Digital edition 2017; 6pii: S0003469X17026434
16. Wilson WR, Bower TC, Creager MA, Sepideh Amin-Hanjani, O’Gara PT, Lockhart PB, Darouiche RO, Basel Ramlawi, Derdeyn CP, Bolger AF, Levison ME, Kathryn A. Taubert KA, Baltimore KA, Baddour LM: Vascular Graft Infections, Mycotic Aneurysms, and



- Endovascular Infections: A Scientific Statement From the American Heart Association. *Circulation*. 2016; 2016 Nov 15;134(20):e412-e460. doi: 10.1161/CIR.0000000000000457. Epub 2016 Oct 13.
17. Levin SR, Arinze N, Siracuse JJ: Lower extremity critical limb ischemia: A review of clinical features and management. *Trends Cardiovasc Med*. 2020 Apr; 30(3):125-130. doi: 10.1016/j.tcm.2019.04.002. Epub 2019 Apr 15.
  18. Holdsworth PJ, Riddell PS, Leveson SH: Distal femoropopliteal bypass using a composite graft of PTFE and non-reversed saphenous vein. *Ann R Coll Surg Engl*. 1989 Jan; 71(1): 4-6
  19. Desai TR, Meyerson SL, Skelly CL, MacKenzie KS, Bassiouny HS, Katz D, McKinsey JF, Gewertz BL, Schwartz LB: Patency and limb salvage after infrainguinal bypass with severely compromised ("blind") outflow. *Arch Surg*. 2001 Jun;136(6):635-42. Doi: 10.1001/archsurg.136.6.6357.
  20. LoGerfo FW, Quist WC, Nowak MD, Crawshaw HM, Haudenschild CC: Downstream anastomotic hyperplasia. A mechanism of failure in Dacron arterial grafts. *Ann Surg*. 1983 Apr; 197(4): 479-483. doi: 10.1097/0000658-198304000-00018Y
  21. Handa R, Sharma S: Vascular graft failure of leg arterial bypasses - a review. *J Hypertens Cardiol* 2014; 1(3):17-21. <https://doi.org/10.14302/issn.2329-9487.jhc-14-404>
  22. Al-Omran M, Tu JV, Johnston W, Mamdani MM et al: Outcome of revascularization procedures for peripheral arterial occlusive disease in Ontario between 1991 and 1998: A population-based study. *J Vasc Surg* 2003, 38, 279-288
  23. Rinckenbach S, Guelle N, Lillaz J, Al Sayed M, Ritucci V, Camelo G: Femorofemoral bypass as an alternative to a direct aortic approach in daily practice: appraisal of its current indications and midterm results. *Ann Vasc Surg*. 2012 Apr;26(3):359-64. doi: 10.1016/j.avsg.2011.04.011. Epub 2011 Nov 1.
  24. Johnson WC, Corson J, Vollman RW, Weisel RW, Davis RC, O'Hara ET, Nabseth DC, Mannick JA: A comparison of the late patency rates of axillobilateral femoral and axillounilateral femoral grafts. *Surgery*, 1977, 81 (1):33-8, 38-40
  25. Martin D, Katz SG: Axillofemoral bypass for aortoiliac occlusive disease. *Am J Surg*, 2000, 180(2):100-103
  26. Hertzner NR, Bena JF, Karafa MT: A personal experience with direct reconstruction and extra-anatomic bypass for aortoiliac occlusive disease, *J Vasc Surg*. 2007; 45(3):527-535; discussion 535. doi: 10.1016/j.jvs.2006.09.065
  27. De Carlo M, Schlager O, Mazzolai L, Brodmann M, Espinola-Klein C, Staub D, Aboyans V, Sillesen H, Debus S, Venermo M, Belch J, Ferrari M, De Caterina R: Antithrombotic therapy following revascularization for chronic limb-threatening ischaemia: a European survey from the ESC Working Group on Aorta and Peripheral Vascular Diseases. *Eur Heart J Cardiovasc Pharmacother*. 2023 Apr 10;9(3):201-207. doi: 10.1093/ehjcvp/pvac055
  28. Kurzer M, Belsham PA, Kark AE: The Lichtenstein repair for groin hernias. *Surg Clin North Am*. 2003 Oct; 83(5):1099-117. doi: 10.1016/S0039-6109(03)00134-8
  29. Nguyen LL, Conte MS, Menard MT, Gravereaux EC, Chew DK, Donaldson MC, Whittemore AD, Michael Belkin M: Infrainguinal vein bypass graft revision: factors affecting long-term outcome. *J Vasc Surg*. 2004 Nov;40(5):916-23. doi: 10.1016/j.jvs.2004.08.038
  30. Pereira C, Gururaj S: Onlay Versus Sublay Mesh Repair for Incisional Hernias: A Systematic Review. *Cureus*. 2023. doi: 10.7759/cureus.34156
  31. Kurzer M, Kark A, Selouk S, Belsham P: Open Mesh Repair of Incisional Hernia Using a Sublay Technique: Long-Term Follow-up. *World J Surg*. 2008; 32(1):31-36; discussion 37. doi: 10.1007/s00268-007-9118-z
  32. Exton RJ, Galland RB: Major groin complications following the use of synthetic grafts. *Eur J Vasc Endovasc Surg*. 2007 Aug; 34(2):188-90. doi: 10.1016/j.ejvs.2007.03.012. Epub 2007 May 18
  33. Williams IM, Milling MAP, Shandall AA: Vascularised muscular flaps and arterial graft infection in the groin. *Eur J Vasc Endovasc Surg*. 2003 May;25(5):390-5. doi: 10.1053/ejvs.2002.1890
  34. Patel A, Taylor SM, Langan EM 3rd, Snyder BA, Cull DL, Sullivan TM, Youkey JR, Gray BH, Carsten CG 3rd: Obturator bypass: a classic approach for the treatment of contemporary groin infection. *Am Surg*. 2002 Aug;68(8): 653-9
  35. Dubouis A, Gatinois A, Foret T, Rinckenbach S, Salomon Du Mont L: Obturator Bypass Remains a Useful Option. *Ann Vasc Surg*. 2023 Jul; 93:1-8. doi:

10.1016/j.avsg.2022.05.048. Epub 2022 Aug 1