

Published: August 31, 2023

Citation: Nair SC, N Niveditha, et al., 2023. Head and Neck Low Flow Vascular Lesions Treated with Corseting Technique, Medical Research Archives, [online] 11(8). <https://doi.org/10.18103/mra.v11i8.4278>

Copyright: © 2023 European Society of Medicine. This is an open-access article distributed under the terms of the Creative Commons Attribution License, which permits unrestricted use, distribution, and reproduction in any medium, provided the original author and source are credited.

DOI
<https://doi.org/10.18103/mra.v11i8.4278>

ISSN: 2375-1924

RESEARCH ARTICLE

Head and Neck Low Flow Vascular Lesions Treated with Corseting Technique

Dr. Sanjiv C Nair*¹, Dr. Niveditha N², Dr. Advait Nair³, Dr. Prashanth R⁴

1. Professor and Head of the Department, Maxillofacial Surgery Department, Bangalore Institute of Dental Sciences, Bangalore, India.
2. Assistant Professor, Maxillofacial Surgery Department, Vokkaligara Sangha Dental College and Hospital, Bangalore, India. ORCID: 0000-0002-7264-1937
3. Former Trainee, Vydehi Institute of Medical Sciences And Research Centre, Bangalore, India.
4. Associate Professor, Maxillofacial Department, Vokkaligara Sangha Dental College and Hospital, Bangalore, India. ORCID: 0000-0001-6771-7610

* Corresponding Author: snmaxfax@gmail.com

ABSTRACT:

Head and neck vascular lesions management has been a great challenge to the surgeons due to catastrophic bleeding that obscures the visibility during the surgery. A proposed surgical technique called CORSET SUTURING for the treatment of non cutaneous low-flow vascular malformations in the head and neck region minimizes the blood loss and facial disfigurement. Corset sutures are placed to strangulate the lesion and restore the facial symmetry with the least amount of comorbidities. The aim of the present study is to describe the clinical characteristics of patients treated by corset suturing technique, material used and surgical morbidity, in order to contribute to a better understanding of this technique. Medical records and images of 15 patients treated by the same corset suturing protocol were retrieved and analysed. The indications, advantages and disadvantages, technique and complications observed are discussed. There was a significant reduction in the bulkiness of tumour mass noted and also a return of the regional facial outline was evident. In conclusion, corset suturing has an important role in management of diffuse low-flow vascular malformations of the head and neck as it is found to be a simple, cost-effective, less scarring and acceptable method, hence can be considered as an alternative to the other expensive methods such as embolization, with least surgical comorbidities.

Keywords: Corset suturing, vascular malformations, head and neck

Introduction

Venous malformations are the one of the most common vascular malformations. The incidence of venous malformations is 1 in 5000 to 1 in 10,000 of child health. They are formed by abnormal collection of veins, venular capillaries and venules. They are usually present at birth and increase in size with growth and peaks being during growth spurts. The size varies with venous pressure which can be demonstrated by Valsalva's manoeuvre. They are blue- violet in colour, soft, compressible and cause facial asymmetry, disfigurement, pain, ulcers and bleeding. Massive bleeds and invasion of adjacent structures can compromise speech, respiration and deglutition leading to suffocation and death. They affect psychological and social well being of the patients. At the histological level they reveal dilated veins with flattened endothelium and are non cancerous. The ectatic nature increases with advanced age. Radiographically there are presence of phleboliths in venous malformations being one of the characteristic feature [7]. They can either be present as single or multiple located superficially or deep. The mostly affected anatomical sites are lips, cheek, tongue, mucosa and palate.

Treatment of symptomatic venous malformations is aimed at controlling symptom and eliminating or reducing the lesion. Recent treatment modalities include medication, sclerotherapy, cryotherapy, laser therapy, electrocoagulation, copper needles, corset suturing and surgical excision. Overall, the treatment approaches should be personalized depending on the initial symptoms, defects' severity, and the lesion's growing phase. There is no as such "gold standard" treatment for all patients. A better understanding of the nature of the lesion has led to a better response rate and a safer treatment for the patients [15]. Apart from the effect of each treatment procedure, the ultimate goal of using such treatments is to improve the appearance of lesions and patients' satisfaction with overall improvement in quality of life. As excision of complex lesions remains difficult due to secondary intraoperative bleeding, we performed a new wrapping technique called corset suturing for low flow VMs according to the size of malformation. This technique is similar to fascial plication technique but is deep and permits the shift of tension from the dermis to the fascia created during wound closure.

Colletti et al. describe the use of non-resorbable sutures involving the most superficial part of the venous malformation peeing into the underlying periosteum. The corset technique does not involve peeing the periosteum but only the bulk of the lesion. The suture used is PDS (polydioxanone). The

advantage of PDS is that its tensile strength lasts for over 2 weeks and it undergoes resorption within 180 days. This allows sufficient time for internal thrombosis and fibrosis. This technique involves placing of multiple sutures to encircle the lesion to control blood flow and achieve hemostasis. It is typically performed in operation room under general or regional anesthesia.[12]

Our purpose is to present a simple method for treating a diffuse low flow venous malformation. In the present study, we review the efficacy of corset suturing on VMs treated in our centre. We quantified the change in dimensions from preoperative size to the postoperative resultant size.

Methods

From the data collected between October 2016 to December 2022 by analysing the management pattern for patients with venous malformation, 15 patients were selected. All these patients underwent corset suturing procedure and were diagnosed with symptomatic venous malformations. A retrospective analysis and radiographic review were performed at the Bhagwan Mahaveer Jain Hospital. Patients with Low-flow vascular malformation who had difficulty in speech, swallowing and Lesions that were causing primary facial deformity were included. Exclusion criteria were High-flow arterial malformations, lesions having a self-healing tendency, lesions involving critical structures such as the eyes and carotid artery, and those in inaccessible spaces of the head and neck [16]. For the patients where assessing the lesions was difficult, follow up MR images were obtained.

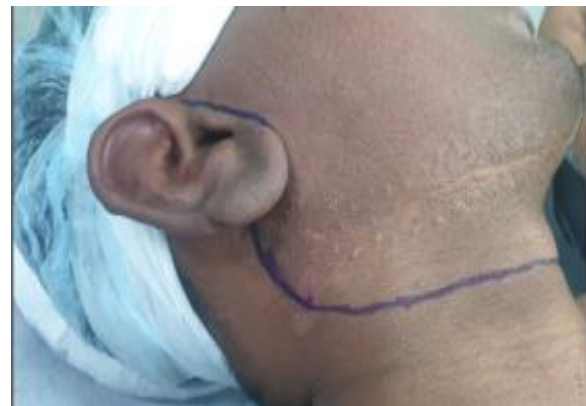

Figure 1: Modified Blair incision on right cheek

Technique

A corset is a woman's close-fitting foundation garment worn to hold and shape their waist. This concept was adapted in orthopaedics to encircle and support the vertebral column for trauma or for congenital deformities of the spine. The corset

suturing in similar manner reduces the bulkiness of the lesion and improves the appearance esthetically and minimises the blood loss in low flow venous malformations. In this technique, the surgeon carefully identifies the boundaries of the lesion and places a series of sutures in a figure of eight or crisscross sutures around it. incisions are placed along the skin tension lines in cosmetically acceptable site closest to the lesion (figure 1).

The flaps are raised in the sub-superficial muscular aponeurotic system (SMAS) plane. Polydioxanone, a bioresorbable suture is placed from the subcutaneous to the deep layer in a continuous vertical loop fashion from one end to the other at equidistant intervals. In case of larger lesions, it has to incorporate loops fashion in horizontal direction too, that is both from superoinferior and mediolateral directions to be covered (figure 2).

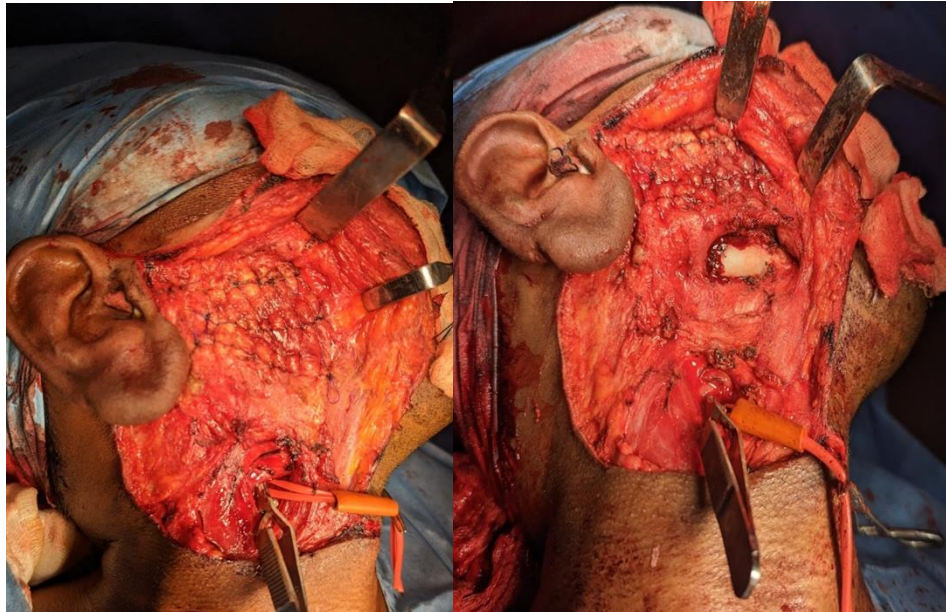


Figure 2: Placement of the bioresorbable suture in a continuous vertical looping fashion, in a superior to inferior direction and then further advanced in the medial to lateral direction to involve the whole lesion.

This encircles the lesion and compresses the vascular spaces by obstructing the feeding and draining vessels. As a result of which the intratumoral bulkiness reduces and also lowers the risk of swelling and bleeding.

It is important to perform the corset suturing in this fashion because of the presence of the sinuous, winding, and random network of vascular channels and collateral circulation present within the tumour [16]. The sutures need to be secured tightly with caution to reduce the amount of venous channels and compress the lumina which in turn decompresses the lesion and reduced the risk of haemorrhage. The flaps are reappromixated by marking and excising the excess skin (figure 3). Drains are placed and good closure is obtained.

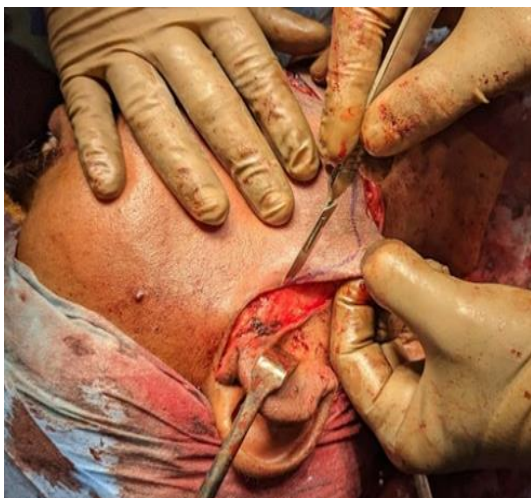

Figure 3: Excess skin marked on the skin flap

Results

Over a period of approximately 6 years (October 2016 to December 2022) 15 low flow venous malformations in the head and neck region were treated surgically with corsetting technique according to their anatomical location, size and depth of the lesion. The most commonly affected sites being cheek, lips, tongue, parotid, maxilla and mandible (Table 1). The mean calculated age was 24.4 years (range, 5-54 yrs).

Table 1: Patients summary

S NO.	AGE	SEX	CLASSIFICATION	SITE
1	9	Male	Type II	Left face
2	38	Male	Type III	Left parotid
3	24	Female	Type II	Right submandibular region and face
4	20	Male	Type II	Left Post auricular region
5	22	Female	Type II	Lips and Right face region
6	5	Male	Type III	Right parotid and retromandibular region
7	15	Male	Type V	Parapharyngeal and right shoulder
8	13	Female	Type I	Left side of face and retromandibular region.
9	22	Male	Type II	Right side of the face.
10	54	Male	Type III	Right cheek, Parotid and tongue.
11	12	Male	Type IV	Right cheek, maxilla and mandible
12	40	Male	Type III	Bilateral parotid right face, both lips and tongue.
13	30	Male	Type II	Right cheek
14	23	Female	Type III	Right side of the tongue
15	42	Male	Type II	Lower lip

Depending upon the categorization, diagnostic investigations such as computed tomography (CT) with contrast (12), magnetic resonance imaging (2) (MRI)/magnetic resonance angiography (1) (MRA), plain radiographs, and ultrasonography were

performed (table 2). Of the 15 patients included in the study, 11 were male (73.3%) and 4 were female (27.7%). By type, none of the type I were included, 8 were type II, 5 were type III, 1 were type IV, and 1 were type V (Table 2).

Table 2: Distribution of the patients according to the type of vascular location and imaging techniques.

Patient's data		No. Of patients
Gender	Male	11
	Female	4
Age	1-20	6
	21-40	7
	41-60	2
Imaging	CT	12
	MRI	2
	MRA	1
Type	I	1
	II	7
	III	5
	IV	1
	V	1

After careful diagnosis of the vascular malformations, 15 cases of low-flow venous malformations were selected for corset suturing. Type I cases were not included for corset suturing. 11 Patients underwent corset suturing alone and 4 required another surgery for excision. Corset suturing resulted in improvement or resolution of symptoms in all patients. The mean follow-up duration was 15.6 months (range 10-24 months). All the patients experienced resolution of symptoms after undergoing a single procedure [4].

Postoperatively, on day 2 and 3 there was oedematous swelling that appeared. A reduction of the turnout tumour mass and return of the regional outline was evident post 1 week after surgery. At 5th week post surgery, there was a considerable reduction in the size of the tumour mass and the patients had returned to normal function. By the end of 9 weeks, the lesions had almost disappeared completely in a few cases and the facial/oral region had attained a near normal appearance, colour, and consistency (Figure 4, 5).

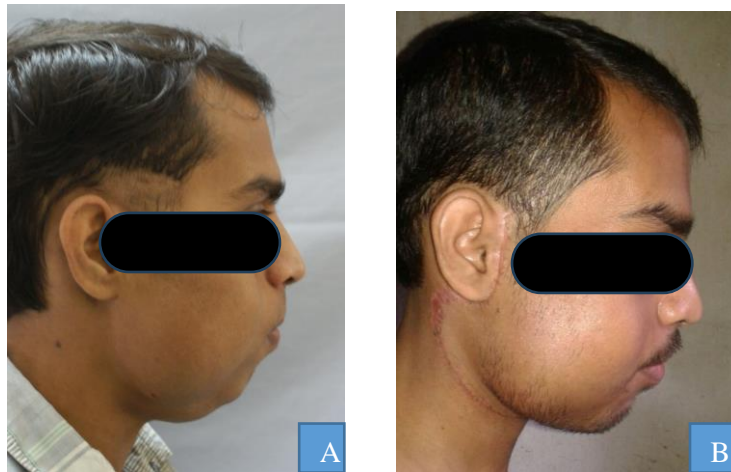

Figure 4: Case 1: Pre operative and postoperative images of patient with type II low flow venous malformation on right side of the cheek

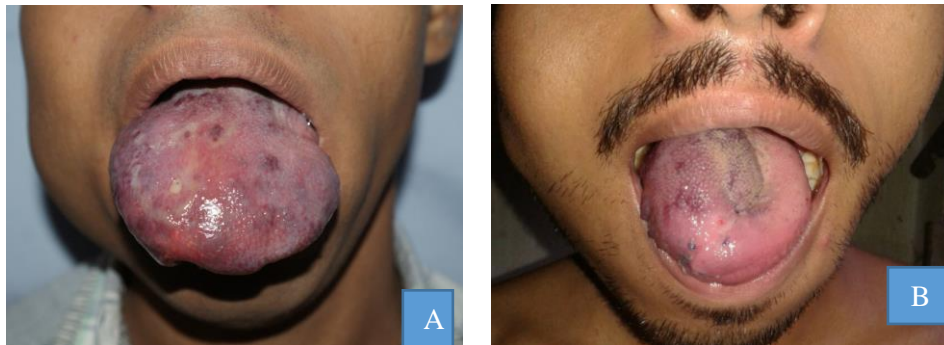


Figure 5: Case 2: Pre-operative (a) and postoperative (b) images of patient with type II low flow venous malformation on the anterior one-third of the tongue

In most of the cases, although the tumour mass was reduced in size by more than 50% due to necrosis and regression, a few required further excision of the lesion at a later stage. Depending upon the initial size of the lesion, most malformations took 5-9 weeks to resolve.

The patient's satisfaction was very high, with an improvement of their self-confidence and social relationships, as reported by the patients at the last follow-up visit.

Discussion

Venous lesions are low flow vascular malformations because they are by definition malformations of the venous system, that are usually not seen on arteriograms, even during the late venous phase. They are hazardous entities but not malignant. Any surgical management can cause life threatening hemorrhages. Due to these risks, there are no acknowledged guidelines for the management and are tailored case by case. The signs and symptoms usually depend upon the size and sites involved. They do not regress the way hemangiomas of infancy do, but increases with size with any increase

in venous pressure or hormonal variations. Extensive or multifocal malformations are rarely cured completely, but the extent of the malformations and the symptoms can be controlled. At our centre, large low-flow lesions treated surgically have been done under external carotid artery control leaving defects requiring reconstruction with flaps. Complete surgical excision of the extensive lesions is rarely possible without causing significant functional impairment and disfigurement. On the other hand, Venous malformations characterized by the aggregation of many smaller channels (section < 2 cm) respond poorly to sclerotherapy alone and even multiple sessions are frequently ineffective. In such cases, Sclerotherapy can be performed as a complementary procedure a few days before the surgical time, with the aim of inducing intracamerular coagulation and thus reducing intraoperative bleeding [2].

The corset technique described in this article was proposed as a new therapeutic modality for the treatment of large and diffuse low-flow vascular lesions [14]. The results have been satisfying with no requirement for major secondary reconstructions.

Most venous malformations show gradual enlargement, perhaps due to hormonal fluctuations or trauma which has led to chances of remission inspite of reduction in the bulkiness post corset suturing. The aim of this technique is the staged removal of the bulk of the malformation with the purpose of reducing the number of chambers and the volume of the mass, facilitating the excision of the malformation. The simplified categorization of vascular malformations into five types based on anatomical presentation provides input into the investigation and effective surgical management of these lesions (Table 2). In the authors' opinion, the proposed technique plays its main role in those challenging cases in which surgery is hampered by the localization and extent of the lesion. Both patients were originally approached surgically with the aim of removing the VMs. In both cases, at some point intraoperatively, it became clear to the surgeons that any further attempt to remove the VMs would have caused major blood loss and jeopardized facial nerve function. The first option in a similar setting would be terminating the operation, failing to achieve the goal of cosmetic amelioration.

We sought a minimally invasive approach to reduce the volume of the lesion that could not be extirpated. A variable number of stitches are placed depending on the size and position of the venous mass. The choice to use non-resorbable sutures such as nylon was made considering that any resorption of the stitches could allow a re-expansion of the VM and thus would cause a relapse of the VM with consequent long-term failure. We used 2/0 or 3/0 sutures because of their resistance when anchoring the periosteum. The direction of the stitches, parallel to the supposed direction of the facial nerve branches, is taught to be of critical importance to avoid strangling the nerve within the VM. This did not occur in the presented series.

Tightening a number of stitches from the surface of the lesion to the periosteum does not represent a cure for the VM but a decompression technique, reducing the volume of the unexcisable lesion by a permanent pressure dressing. Grey-scale ultrasound and Doppler analysis are useful in defining whether the lesion is solid or cystic and in establishing the flow dynamics of the lesion [3]. This technique of intra-tumoural ligation involves the occlusion of all arterial and venous connections within the regional vascular network and strangulates the vascular channels in and around the malformation [1, 16]. These enormous vascular channels of malformation are broken up into many segments that cannot communicate with each other,

resulting in the elimination of whole blood flow by two effects: (1) strangulated vessels produce buried scars that obstruct the vascular channels, and (2) blood stasis between the sutures produces blood clots, which undergo normal organization. Subsequently the vascular endothelium undergoes progressive atrophy with fibrous hyperplasia and the replacement of angiomatous tissue by fibro-connective tissue [6].

This technique could be used for the patients with cardiac complications as it doesn't involve catheterisation of common and external carotid arteries and also the vertebral arteries. It does not require selective angiography and introduction of foreign bodies that causes toxic reactions. This technique seems to be superior in terms of esthetics and is cost effective. It can also be used as an adjunctive to reduce the size of the excisional defect by performing corset suturing to reduce the size of the lesion followed by another surgery for surgical excision. Hence it can also reduce the usage of grafts and flaps to cover the surgical defect [8].

Considering the advantages of this approach, it can be indicated for diffuse low flow vascular lesions which are intraoperatively unresectable with high risk for bleeding and recurrence. Large lesions with a tendency for rapid growth and at a close vicinity to important structures like salivary glands, ducts that are not amenable to resection. Rapid growth of the lesions can be predicted in patients with hormonal changes as in puberty and pregnancy periods.

The limitations are that it cannot be performed in class 1 lesions, high flow lesions and also in airway compromised patients. No long-term side effects related to the procedure were observed. In cases where traditional methods like embolization and ligation may be ineffective or challenging, corset suturing offers an alternative approach.

Finally, it is worth stressing that this complementary approach has yielded good outcomes in large, infiltrative cases in which sclerotherapy had failed before. The need for a longer term follow-up is crucial to evaluate the success of this technique. Corset suturing needs experience and expertise in vascular surgery. Although it can be effective, it carries risk of complications such as vessel injury and compromise of blood supply to surrounding tissues and requires close postoperative monitoring to address any potential risks. The decision to use this technique has to be made on case basis, considering the characteristic features of the lesion, patient factors and collaboration with multidisciplinary team.

Conclusion

We found corset suturing to be an effective method for treating a diffuse low-flow venous malformations in the head and neck region. In this series complete symptomatic relief was observed and also provided acceptable esthetic appearance. Given that our data-set was smaller in comparison to other studies, we cannot use it as a definitive guide for treatment guideline but this can definitely add to the current literature.

However, follow-up studies on the subject can be expected to yield more concrete results. Given all these considerations, the availability of this technique could encourage surgeons to address those challenging cases that otherwise would be left untreated. This approach will be pursued in a larger

patient series to prove and strengthen its effectiveness.

Funding

None.

Competing interests

None.

Ethical approval

Retrospective case review—ethical clearance obtained.

Patient consent

Written patient consent was obtained to publish the clinical photographs

References:

1. Popescu V. Intratumoral ligation in the management of orofacial cavernous haemangiomas. *Journal of Maxillofacial Surgery*. 1985;13:99-107.
2. Berenguer B, Burrows PE, Zurakowski D, Mulliken JB. Sclerotherapy of craniofacial venous malformations: complications and results. *Plast Reconstr Surg*. 1999;104(1):1-11.
3. Dubois J, Soulez G, Oliva VL, Berthiaume M, Lapierre C, Therasse E. Soft-Tissue Venous Malformations in Adult Patients: Imaging and Therapeutic Issues. *RadioGraphics*. 2001;21(6):1519-31.
4. Johnson PL, Eckard DA, Brecheisen MA, Girod DA, Tsue TT. Percutaneous ethanol sclerotherapy of venous malformations of the tongue. *AJNR Am J Neuroradiol*. 2002;23(5):779-82.
5. Mulliken JB, Rogers GF, Marler JJ. Circular Excision of Hemangioma and Purse-String Closure: The Smallest Possible Scar. *Plastic and Reconstructive Surgery*. 2002;109(5):1544-54.
6. Vlahovic A, Simic R, Kravljanac D. Circular excision and purse-string suture technique in the management of facial hemangiomas. *International Journal of Pediatric Otorhinolaryngology*. 2007;71(8):1311-5.
7. Domp Martin A, Vikkula M, Boon LM. Venous malformation: update on aetiopathogenesis, diagnosis and management. *Phlebology*. 2010;25(5):224-35.
8. Nair S, Spencer N, Nayak K, Balasubramaniam K. Surgical management of vascular lesions of the head and neck: a review of 115 cases. *International Journal of Oral and Maxillofacial Surgery*. 2011;40(6):577-83.
9. Cornelis F, Neuville A, Labrèze C, et al. Percutaneous Cryotherapy of Vascular Malformation: Initial Experience. *Cardiovasc Intervent Radiol*. 2013;36(3):853-6.
10. Colbert SD, Seager L, Haider F, Evans BT, Anand R, Brennan PA. Lymphatic malformations of the head and neck—current concepts in management. *British Journal of Oral and Maxillofacial Surgery*. 2013;51(2):98-102.
11. Zheng JW, Mai HM, Zhang L, et al. Guidelines for the treatment of head and neck venous malformations. *Int J Clin Exp Med*. 2013;6(5):377-89.
12. Colletti G, Colombo V, Mattassi R, Frigerio A. Strangling technique to treat large cervicofacial venous malformations: a preliminary report. *Head Neck*. 2014;36(10):E94-8.
13. Behravesh S, Yakes W, Gupta N, et al. Venous malformations: clinical diagnosis and treatment. *Cardiovasc Diagn Ther*. 2016;6(6):557-69.
14. Kumar V, Nair S. Corset sutures in the management of vascular lesions of the head and neck — our experience. *International Journal of Oral and Maxillofacial Surgery*. 2017;46:145.
15. Colletti G, Ierardi AM. Understanding venous malformations of the head and neck: a comprehensive insight. *Med Oncol*. 2017;34(3)
16. Nair S, Chawla J, Shroff S, Kumar B, Shah A. Corseting: a new technique for the management of diffuse venous malformations in the head and neck region. *International Journal of Oral and Maxillofacial Surgery*. 2018;47(12):1534-40.
17. Nair S, Chawla J, Shroff S, Kumar B, Shah A. 'Corseting' and 'strangling'—two techniques sharing similar concepts to treat large venous malformations in the head and neck region. *International Journal of Oral and Maxillofacial Surgery*. 2019;48(5):698.
18. Omranifard M, Rasti Ardakani M, Jafari R. Postoperative Outcomes in Patients with Facial Vascular Malformation Regarding Quality of Scar, Satisfaction, and Quality of Life. *Shiraz E-Med J*. 2022;23(10):e122799.