

Published: April 30, 2024

Citation: Ajim A, Elkhatabi W, et al., 2024. Tuberculosis or Sarcoidosis or the Both? A Case Report of Concomitant Tuberculosis and Sarcoidosis, Medical Research Archives, [online] 12(4).

<https://doi.org/10.18103/mra.v12i4.5153>

Copyright: © 2024 European Society of Medicine. This is an open-access article distributed under the terms of the Creative Commons Attribution License, which permits unrestricted use, distribution, and reproduction in any medium, provided the original author and source are credited.

DOI

<https://doi.org/10.18103/mra.v12i4.5153>

ISSN: 2375-1924

CASE SERIES

Tuberculosis or Sarcoidosis or the Both? A Case Report of Concomitant Tuberculosis and Sarcoidosis

A. Ajim¹, W. Elkhatabi¹, H. Arfaoui¹, N. Bougteb¹, H. Jabri¹, M.H. Afif¹, K. Rebbouh², H. Tabakh², A. Siwane², N. Touil², O. Kacimi², N. Chikhaoui²

¹ Departement of Pneumology 20 August 1953, university hospital IBN ROCHD, Casablanca, Morocco

² Emergency radiology department, university hospital IBN ROCHD, Casablanca, Morocco

*Corresponding author: docteurasmaajim@gmail.com

ABSTRACT:

Tuberculosis and sarcoidosis are two chronic granulomatous diseases that are similar in many aspects, although different.

We report a case of 38-year-old female patient who presented a progressive shortness of breath and recurrent epistaxis associated to a night sweats and fatigue with a deterioration of general condition, in which a CT-scan showed a multiple voluminous lymphadenopathy involving all the mediastinum territories, without parenchymal abnormalities. During investigations bronchoscopy showed mucosal hypertrophy and granulations located on the nasopharyngeal walls. The biopsy of the lip and nasal's lesion showed a non-caseating granuloma and ACE (angiotensin converting enzyme) was high, which considered sufficient to retain the diagnosis of sarcoidosis, but the blood Quantiferon-TB Gold in Tube test was positive and the excision biopsy of cervical lymphadenopathy, revealed a necrotizing granulomatous inflammation suggestive of tuberculosis. The association between sarcoidosis and tuberculosis was discussed. the patient was treated with antituberculosis drugs during six months. The evolution was marked by a progressive regression of lymph nodes. There was no significant improvement of rhinological symptoms with local corticoids. Consequently, the corticosteroid treatment in form oral was introduced during 1 month. The prednisolone was gradually tapered off after 1 month due to the complete disappearance of lesions.

The case described is suggestive of a coexistent systemic sarcoid manifestation and tuberculosis, which is an underrecognized entity in the medical literature.

Keywords : tuberculosis, sarcoidosis, granulomatous, coexistence.

Introduction:

Tuberculosis and sarcoidosis are two frequent granulomatosis in the daily practice of pneumology. These two diseases cause a problem of differential diagnosis, given their clinical, radiological and histological resemblance.

Tuberculosis is an infectious disease caused by *Mycobacterium tuberculosis*, with caseating granuloma being a hallmark. In contrast, sarcoidosis is a multisystem inflammatory disorder of unknown etiology affecting the lungs and intrathoracic lymph nodes, non-caseating epithelioid granulomas being a hallmark. Nevertheless, the similarities between conditions histologically facilitated the search for associations between both diseases.

The association of sarcoidosis with tuberculosis has already been described in the past, the tuberculosis could be a complication of treatment in sarcoidosis otherwise the sarcoidosis may occur secondary to a tuberculosis infection. But their coexistence is rarely reported in the literature.

The present article describes one case of a simultaneous association sarcoidosis-tuberculosis, shed light on the clinical presentation, means of

diagnosis, the management and the evolution of each disease.

Observation:

A 38-year-old female patient thyroidectomized a year and a half ago for papillary thyroid carcinoma, undergo iratherapy and thyroid hormone replacement therapy, with no other medical history. She was admitted to our department for a progressive shortness of breath associated to a recurrent epistaxis confused initially with hemoptysis. The patient had also reported a night sweats and fatigue with a deterioration of general condition (weight loss of 10 kg over two months). Physical examination revealed a multiple bilateral cervical lymphadenopathy, tender, mobile. The chest X-ray (Figure 1) showed a bilateral hilar lymph node enlargement.

Chest CT scan on the mediastinal window (Figure2) demonstrating a multiple voluminous lymphadenopathy involving all the mediastinum territories, which are bilateral, symmetrical, noncompressive and nonnecrotic. Without parenchymal abnormalities on the lung window (Figure 3).

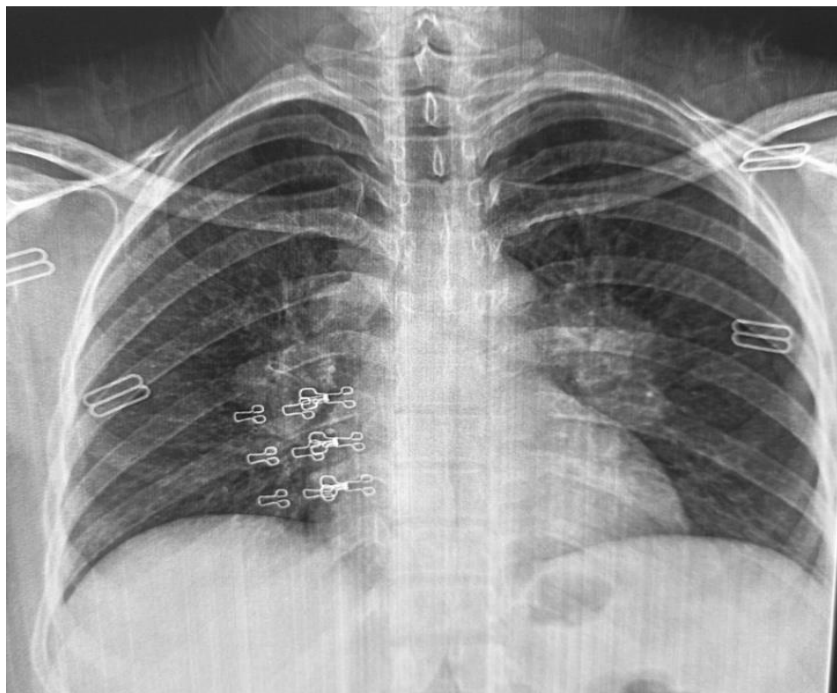


Fig 1: Bilateral hilar lymphoma on a frontal chest radiograph.

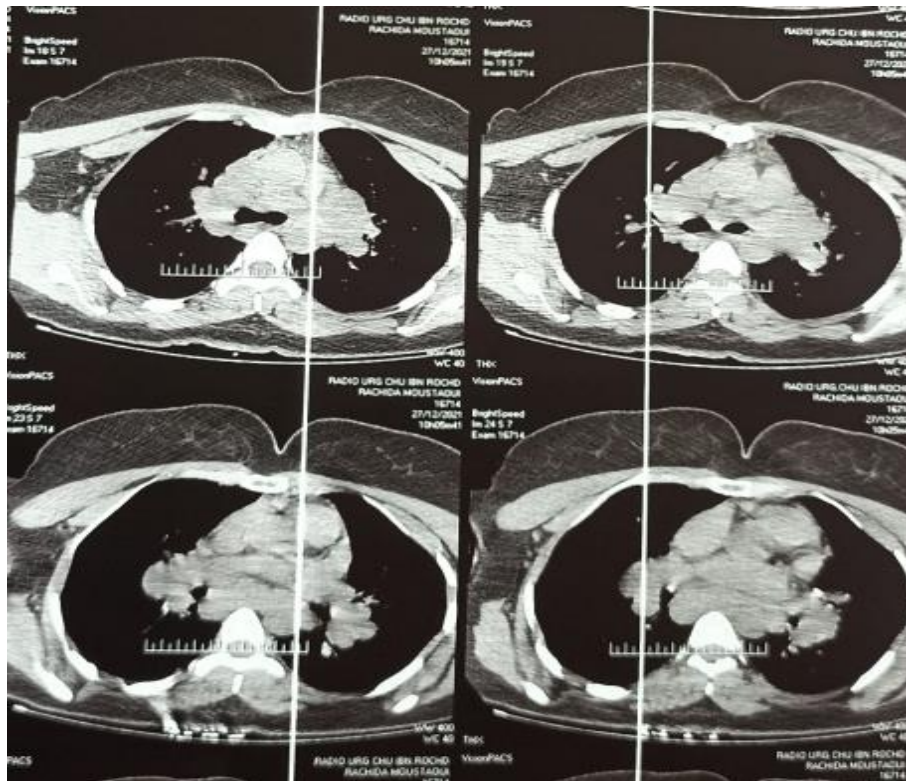


Fig 2: Chest CT scan on the mediastinal windows show multiple centimetric lymphadenopathies involving all the mediastinal territories, bilateral, symmetrical, non-compressive, without necrosis, without pleuro-pericardial effusion.

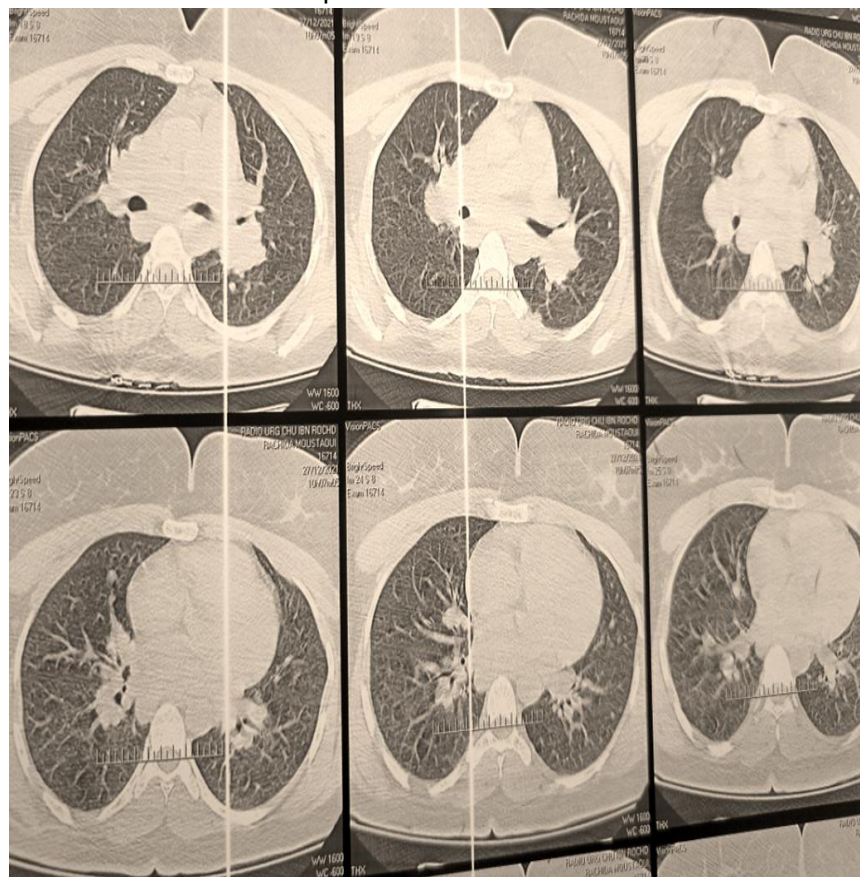


Fig 3: Chest CT scan on the parenchymal windows noticed the absence of nodules or micronodules or septal thickening.

The patient had a microcytic hypochromic anemia with a lymphopenia (1197/mm³).

Bronchoscopy showed mucosal hypertrophy and granulations located on the nasopharyngeal walls (Figure 4) associated to an extrinsic bilateral compression on the bronchi (lingula, right Fowler, middle lobar), without endobronchial granulations.

The diagnosis of an infection especially caused by mycobacterium tuberculosis usually relies on microbiological exams from bronchial aspirations which were negative.

Sarcoidosis seems more likely probable, without being able to rule out other diagnosis, such as tuberculosis and lymphatic dissemination of the papillary carcinoma already mentioned in the medical history.

Histopathologic confirmation is required to establish the potential diagnosis. The biopsy of the lip and nasal's lesion showed a non-caseating granuloma

which considered sufficient to retain the diagnosis of sarcoidosis. The investigation for sarcoidosis was completed by the ACE (angiotensin converting enzyme) that was high (at 106 U/l). But the blood Quantiferon-TB Gold in Tube test was positive.

The bronchoscopy biopsies were aspecific, without signs of malignancy. The excision biopsy of cervical lymphadenopathy, revealed a necrotizing granulomatous inflammation suggestive of tuberculosis. The microbiological study of the lymph node was not done.

After a collective decision, the patient was treated with antituberculosis drugs during six months. The evolution was marked by a progressive regression of lymph nodes. There was no significant improvement of rhinological symptoms with local corticoids. Consequently, the corticosteroid treatment in form oral was introduced during 1 month. The prednisolone was gradually tapered off after 1 month due to the complete disappearance of lesions.

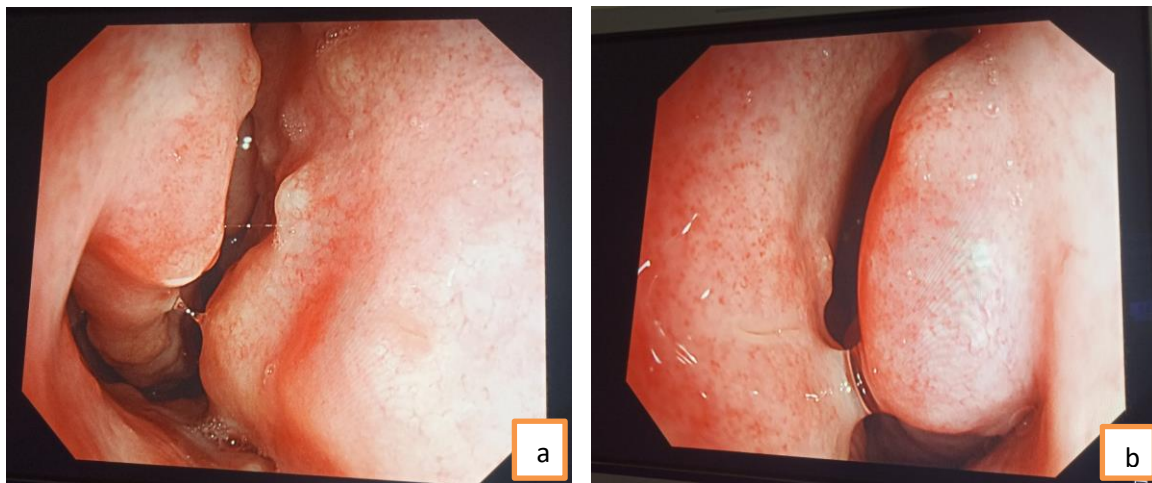


Fig 4: Bronchoscopy had showed granulations (a), and inflammation on the nasal mucosa (b)

Discussion:

Tuberculosis and sarcoidosis are two chronic multi-systemic granulomatosis that are common in the daily practice of the pulmonologist and radiologist, but their association remains understudied.

The diagnosis of one makes the differential of the other. Their diagnosis based on a set of arguments: anamnestic, clinical, radiological, biological, and histological ⁽¹⁾.

There are 3 types of this association: tuberculosis caused by the corticosteroid therapy in sarcoidosis. A simultaneous association sarcoidosis - tuberculosis, and a sarcoidosis secondary to a tuberculosis infection.

Sarcoidosis represents a stereotyped, antigen-driven immune disorder with diverse etiologies ⁽²⁾. A century of epidemiologic, molecular, and immunologic literature emphasizes the hypothesis

about a causal role of mycobacteria antigens in some sarcoidosis cases ^{(3) (4) (10)}.

In an important meta analysis, Gupta and colleagues analyzed 31 series and case control studies published between 1980 and 2006. In a pooled analysis, 231 out of 874 patients with sarcoidosis were positive for mycobacterial (MTB or non-MTB) nucleic acid ⁽⁵⁾. The authors concluded that, despite evidence of a reporting bias, the odds ratio in their analysis suggested an association between mycobacteria and sarcoidosis ^{(5) (12)}.

This association may be observed in the immunocompetent as in the immunocompromised patients. Patients with tuberculosis had an 8.09 higher risk of developing sarcoidosis throughout the follow-up period. This risk is increased in the extra-pulmonary tuberculosis ⁽⁶⁾.

Patients with sarcoidosis, especially during the first year, had a 1.85 times higher risk of developing tuberculosis than patients without sarcoidosis ⁽⁶⁾, suggesting that a history of tuberculosis is a risk factor for the development of sarcoidosis.

The relationship between infectious agents and sarcoidosis is complex. Although there is a hypothesis that infectious agents may play a role in the pathogenesis of sarcoidosis, this remains speculative. Conversely, infectious diseases can also complicate sarcoidosis, leading to repeated hospitalizations, respiratory exacerbations, and/or death ⁽⁷⁾.

Several hypotheses in the literature tried to explain this association between mycobacteria (both MTB and MTN) and sarcoidosis, one more plausible is that the slow-growing mycobacteria are able to trigger a type IV immune response and granulomatous lesions in a genetically predisposed terrain ⁽¹⁴⁾.

Due to this close association, with possible coexistence in the same patient, some authors consider tuberculosis and sarcoidosis are two ends of the same spectrum ^{(2) (13)}.

These hypotheses lead to ask the following questions: will the treatment of the two pathologies be modified? how may the existence of one affect the evolution of the other?

It should be noted that antibacillary treatment does not influence the evolution of sarcoidosis ⁽²⁾. The prescription of steroid in the association sarcoidosis-tuberculosis is not systematic and it follows the usual indications. The positive evolution under corticosteroids is in favor of sarcoidosis ⁽³⁾.

The presence of mycobacteria seems influence the evolution of sarcoidosis. It was noted that all patients with mycobacteria-positive samples failed to respond to typical immunosuppressive treatment for sarcoidosis, but other mycobacteria-negative patients responded positively to the same treatment ^{(4) (11)}. Additionally, patients with positive mycobacterial nucleic acid samples showed a tendency for chronic course of sarcoidosis compared to mycobacterial negative patients ⁽⁸⁾.

Very few trials have been conducted to study the impact of antituberculosis drugs on the course of sarcoidosis, conclude that this therapy probably does not influence the natural evolution of sarcoidosis ^{(9) (8)}.

Conclusion:

Sarcoidosis and tuberculosis are two frequent multi-systemic granulomatous, one makes differential diagnosis of the other. Their coexistence is rare, its pathophysiology remains unclear.

The most probable hypothesis is that mycobacteria can induce a persistent hypersensitivity reaction in genetically predisposed patients.

The clinician should keep in mind the possible association of the both diseases in the same patient especially with an unexplained lack of improvement in treatment.

References

1. Hatzakis K, Siafakas NM, Bouros D. Miliary Sarcoidosis following Miliary Tuberculosis. *Respiration* 2000;67(2):219-222.
2. Agrawal R, Kee AR, Ang L, Tun Hang Y, Gupta V, Kon OM, et al. Tuberculosis or sarcoidosis: Opposite ends of the same disease spectrum? *Tuberculosis (Edinb)*. mai 2016;98:21-6.
3. King EQ, Johnson JB, Batten GS, Henry WL. Tuberculosis following cortisone therapy; report of a case of rapidly progressive pulmonary tuberculosis following cortisone therapy for rheumatoid arthritis. *J Am Med Assoc*. 15 sept 1951;147(3):238-41. .
4. Fité E, Fernández-Figueras MT, Prats R, Vaquero M, Morera J: High prevalence of Mycobacterium tuberculosis DNA in biopsies from sarcoidosis patients from Catalonia, Spain. *Respiration* 2006;73:20-26.
5. Gupta D, Agarwal R, Aggarwal AN, Jindal SK. Molecular evidence for the role of mycobacteria in sarcoidosis: a meta-analysis. *Eur Respir J* 2007;30:508–516.
6. Wang SH, Chung CH, Huang TW, Tsai WC, Peng CK, Huang KL, Perng WC, Chian CF, Chien WC, Shen CH. Bidirectional association between tuberculosis and sarcoidosis. *Respirology*. 2019 May;24(5):467-474. doi: 10.1111/resp.13482. Epub 2019 Feb 5.
7. Mohapatra P.R., Garg K., Singhal N., Aggarwal D., Gupta R., Khurana A., et al. Tuberculosis lymphadenitis in a well managed case of sarcoidosis. *Indian J Chest Dis Allied Sci*. 2013;55(4):217–220.
8. Grosser M, Luther T, Füssel M, Bickhardt J, Magdolen V, Baretton G. Clinical course of sarcoidosis in dependence on HLA-DRB1 allele frequencies, inflammatory markers, and the presence of M. tuberculosis DNA fragments. *Sarcoidosis, vasculitis, and diffuse* .
9. Edelson E. Isoniazid in the treatment of sarcoidosis; a preliminary report. *J Invest Dermatol*. août 1953;21(2):71-4. .
10. Brownell I, Ramírez-Valle F, Sanchez M, Prystowsky S. Evidence for mycobacteria in sarcoidosis. *Am J Respir Cell Mol Biol*. 2011 Nov;45(5):899-905. doi: 10.1165/rcmb.2010-0433TR. Epub 2011 Jun 9. PMID: 21659662; PMCID: PMC3361363.
11. Moller DR: Treatment of sarcoidosis - from a basic science point of view. *J Intern Med* 2003;253:31-40.
12. Drake WP, Newman LS: Mycobacterial antigens may be important in sarcoidosis pathogenesis. *Curr Opin Pulm Med* 2006;12:359-363.
13. Gupta D, Agarwal R, Aggarwal AN, Jindal SK. Sarcoidosis and tuberculosis: the same disease with different manifestations or similar manifestations of different disorders. *Curr Opin Pulm Med*. 2012;18:506–516.
14. Maaloune et al, Une sarcoïdose dans le décours d'une tuberculose. *Rev Med Liege* 2019; 74 : 7-8 : 394-400