



RESEARCH ARTICLE

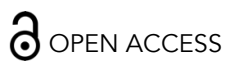Real-world Outcomes of Benralizumab in EGPA: A 24-Patient Series from a Severe Asthma Clinic in North India

Chinkita Agrawal¹, Aamir Shokat¹, Rahul Mittal¹, Deepak Prajapat¹, Kanishka Kumar¹, Deepak Talwar^{2*}

¹Metro Centre for Respiratory Diseases, Sector-11, Noida, U.P.

²Chairman & Director, Metro Centre for Respiratory Diseases, Sector-11, Noida, U.P.

*dtlung@gmail.com



OPEN ACCESS

PUBLISHED

31 December 2025

CITATION

Agrawal, C., Shokat, A., et al., 2025. Real-world Outcomes of Benralizumab in EGPA: A 24-Patient Series from a Severe Asthma Clinic in North India. Medical Research Archives, [online] 13(12).

<https://doi.org/10.18103/mra.v13i12.XXXX>

COPYRIGHT

© 2025 European Society of Medicine. This is an open- access article distributed under the terms of the Creative Commons Attribution License, which permits unrestricted use, distribution, and reproduction in any medium, provided the original author and source are credited.

DOI

<https://doi.org/10.18103/mra.v13i12.XXXX>

ISSN

2375-1924

ABSTRACT

Introduction: Eosinophilic granulomatosis with polyangiitis (EGPA) is a small- medium vessel vasculitis that has multisystem involvement. It is mostly seen in severe bronchial asthma patients. Eosinophils play a major pathological role in both the diseases. Targeted monoclonal antibodies have been emerging as a pivotal part of treatment.

Aim: To study the clinical, radiological profile of patients of Eosinophilic granulomatosis with Polyangiitis (EGPA) and the response to treatment.

Methods: A prospective study conducted in 24 confirmed EGPA patients at a tertiary care center in India. Clinical features, radiological patterns, laboratory markers, lung function parameters, and symptom scores were recorded at baseline and after 3 months of Benralizumab therapy.

Results: The mean age of cohort was 57.7 ± 14.4 years, with females 54.2%. Asthma was present in 83.3% patients. 83.3% showed AEC >150 while P-ANCA was positive in 41.7% cases. Ground-glass opacities were the most common hrct chest finding (54.2%). Sinonasal disease occurred in 71%, skin involvement in 50%, and neuropathy in 20.8% cases. After 3 months of Benralizumab, significant improvements were observed across clinical and biomarker domains. Mean AEC decreased from 671 to 288 cells/ μ L ($p < 0.001$), and mean total IgE declined from 1193 to 558 kU/L ($p < 0.001$). FEV₁% predicted improved from 55% to 71% ($p < 0.001$). Number of patients with FeNO level <25 ppb increased from 41.7% to 83.3% ($p < 0.002$). The mean ACT improved from 15 to 20 ($p < 0.001$), indicating better symptomatic control.

Conclusion: Patients with EGPA demonstrated characteristic clinical and radiological patterns, with early diagnosis enabled by 2022 EULAR criteria. Benralizumab produced significant improvements in eosinophilia, lung function, and symptom control within 3 months, supporting its role as an effective targeted therapy. Early recognition and biologic intervention may help prevent long-term organ damage and improve patient outcomes.

Introduction

Eosinophilic granulomatosis with polyangiitis (EGPA) is a ANCA associated systemic necrotizing vasculitis (SNV) affecting small-to-medium-sized vessels. Its clinical presentation is heterogeneous, usually involving pulmonary, sinonasal, neurological, dermatological, and cardiovascular systems and often overlaps with several other diseases because of which the diagnosis is delayed¹. Peripheral eosinophilia serves as important diagnostic and phenotypic markers². Over the past decade, guidelines for EGPA management have evolved: the European League Against Rheumatism (EULAR) first published recommendations in 2009, which were subsequently revised in 2022, delineating the standard of care for patients with EGPA and emphasizing individualized therapy according to disease phenotype and organ involvement³.

The epidemiology of EGPA is variable, with a global pooled incidence estimated at 1.22 cases per million person-years but the morbidity is substantial. Many patients suffer relapses, severe asthma, frequent hospitalisations, and complications from long-term immunosuppression. This highlights its rarity and the need for high clinical suspicion for timely diagnosis⁴.

Standard therapy for EGPA has long consisted primarily of systemic corticosteroids and broad immunosuppressive agents. While often effective in controlling disease activity, these treatments carry significant risks of long-term adverse effects and may not always achieve sustained remission. In particular, the heavy reliance on oral corticosteroids (OCS) is problematic, and there is ongoing need for steroid-sparing, targeted therapies.

Interleukin-5 (IL-5) plays a central role in eosinophil growth, differentiation, activation, and survival, making the IL-5 pathway a critical therapeutic target in EGPA. Monoclonal antibodies directed against IL-5 or its receptor, such as mepolizumab and benralizumab, have demonstrated efficacy in reducing eosinophilic inflammation, improving disease control, and minimizing corticosteroid dependence. Benralizumab, an anti-IL-5 receptor alpha (IL-5R α) monoclonal antibody, induces near-complete depletion of eosinophils through antibody-dependent cell-mediated cytotoxicity, leading to rapid depletion of eosinophils from blood and tissue. Hence the clinical improvement

in asthma symptoms, systemic manifestations, and eosinophil-related organ damage is achieved⁵⁻⁸.

Real-world data further support these findings: in one retrospective cohort of 33 patients treated with Benralizumab, 39.4% at 3 months to 65.0% at 36 months ($p < 0.001$). Corticosteroid use declined from 90.9% to 15.4%, eosinophil counts dropped from 850 to 0 cells/ μ L showing significant improvement⁹.

Despite these encouraging results globally and in European cohorts, there is a paucity of data from South Asia — including northern India — where genetic, environmental, demographic and health-care access factors differ and may influence disease phenotype and drug response. Given the rarity of EGPA, variability in presentation, and differences in background exposures, investigating the effectiveness, safety, and real-world applicability of Benralizumab in Indian EGPA patients would hold considerable clinical relevance.

Therefore, a study assessing the effect of Benralizumab in EGPA patients in northern India could provide novel and much-needed evidence to guide local clinical practice, improve outcomes, reduce steroid exposure, and better characterize the safety profile in this population.

Aim:

To study the clinical, radiological profile of patients of Eosinophilic granulomatosis with Polyangiitis (EGPA) and the response to treatment.

Methodology:

STUDY DESIGN AND SETTING: This was a prospective interventional study conducted from January 1, 2024, to September 1, 2025, at the Metro Centre for Respiratory Diseases, Noida. The written informed consent was obtained from all participants prior to enrolment.

STUDY POPULATION: Patients diagnosed with Eosinophilic granulomatosis with polyangiitis (EGPA) according to the 2022 American College of Rheumatology/European Alliance of Associations for Rheumatology (ACR/EULAR) classification were eligible.

Inclusion criteria were:

- Age ≥ 18 years
- Clinically confirmed EGPA

- Willingness to provide informed consent and comply with follow-up

Exclusion criteria included:

- Severe comorbidities contraindicating immunotherapy
- Pregnancy or lactation
- Previous treatment with biologics for EGPA within 6 months

BASELINE ASSESSMENT:

At enrolment, all patients underwent:

1. Clinical Evaluation: Detailed history including duration of asthma, ENT symptoms, neurological involvement, dermatological manifestations, and prior treatments. Physical examination was performed with emphasis on respiratory, neurological, and cutaneous findings.

2. Laboratory Investigations:

- Absolute eosinophil count (AEC)
- Total IgE levels
- Routine haematological and biochemical tests

3. Imaging Studies:

- High-resolution computed tomography (HRCT) of the chest
- Non-contrast computed tomography (NCCT) of paranasal sinuses

4. Specialized Tests:

- Nerve conduction studies for patients with peripheral neuropathy
- Dermatological evaluation and biopsy when indicated

5. Pulmonary Function Tests:

- Spirometry to determine FEV1 % predicted
- Fractional exhaled nitric oxide (FENO) measurement

6. Asthma Control:

- Asthma Control Test (ACT) score assessment to determine symptom control status

INTERVENTION: All patients received **Benralizumab (anti-IL-5R α) therapy**, administered as per recommended dosing guidelines. Concomitant symptomatic treatments, including inhaled corticosteroids, bronchodilators, and short courses of systemic corticosteroids, were prescribed as clinically indicated.

FOLLOW-UP ASSESSMENT: Patients were followed up at 3 months post-treatment initiation. The following parameters were reassessed:

- Spirometry (FEV1 % predicted)
- Fractional exhaled nitric oxide (FENO)
- Absolute eosinophil count (AEC)
- Total IgE
- Asthma Control Test (ACT) score

Outcome Measures:

- Change in AEC
- Change in FEV1 % predicted
- Change in FENO levels
- Change in Asthma Control Test (ACT) scores
- Change in Total IgE

STATISTICAL ANALYSIS: Data were analysed using **SPSS version XX**. Continuous variables were expressed as mean \pm standard deviation (SD), and categorical variables as frequencies and percentages. Paired t-tests or Wilcoxon signed-rank tests were used for comparing baseline and follow-up values. A p-value <0.05 was considered statistically significant.

Results:

Table 1: Demographic Variables

Variable	Category	Number (n=24)	Percentage	Mean \pm SD
AGE	>70	4	16.7	57.7 \pm 14.4
	51-70	15	62.5	
	31-50	5	20.8	
GENDER	MALE	11	45.8	-
	FEMALE	13	54.2	
COMORBIDITY	HTN	7	29.1	-
	DM	12	50	
	OSA	3	12.5	
	Absent	2	8.3	
Previous Diagnosis	Bronchial Asthma	20	83.3	-
	HES	3	12.5	
	None	1	4.2	

Table 1 summarizes the baseline demographic variables of the study participants. The mean age was 57.7 ± 14.4 years, with the majority (62.5%) falling within the 51–70 year age group. Participants aged above 70 years constituted 16.7%, while 20.8% were between 31–50 years. Females represented a slightly higher proportion (54.2%) compared to males (45.8%).

Regarding comorbidities, diabetes mellitus (DM) affected 50% of the cohort, followed by

hypertension (HTN) at 29.1%. Obstructive sleep apnea (OSA) was present in 12.5%, and 8.3% reported no comorbid conditions.

In terms of previous diagnoses, bronchial asthma was seen in 83.3% of participants, whereas 12.5% had a prior diagnosis of hypereosinophilic syndrome (HES). Only 4.2% reported no previous respiratory diagnosis.

Table 2: LAB parameters

Variable	Category	Number (n=24)	Percentage	Mean \pm SD
P ANCA	Positive	10	42	-
	Negative	14	58	
MPO/PR3	Negative	24	100	-
	Positive	0	0	
EULAR Criteria	6.0	2	8.3	8.17 ± 1.5
	7.0	2	8.3	
	8.0	13	54.2	
	9.0	2	8.3	
	10.0	3	12.5	
	11.0	1	4.2	
	13.0	1	4.2	

Table 2 presents the distribution of key laboratory findings. Perinuclear ANCA (p-ANCA) positivity was seen in 42% (n=10) patients and MPO/PR3 was

unanimously negative in all the patients. All the 24 patients in the study passed the EULAR criteria with mean value- 8.17 ± 1.5 .

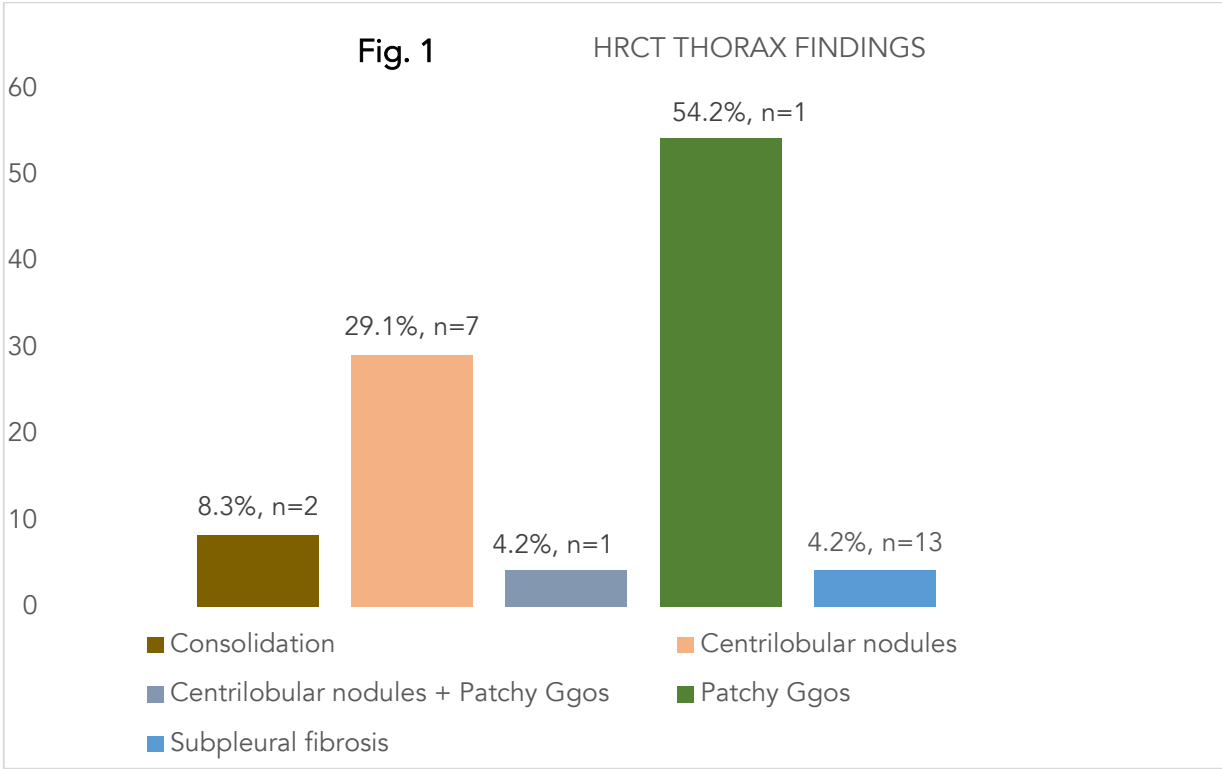


Figure 1: HRCT THORAX findings

The bar chart illustrates the findings on high-resolution computed tomography (HRCT) of the thorax in the study population. Patchy ground-

glass opacities (GGOs) were the most frequent finding, observed in 54.2% (n = 13) of patients. Centrilobular nodules were present in 29.1% (n =

7), while 8.3% (n = 2) showed consolidation. Less common findings included centrilobular nodules

with patchy GGOs in 4.2% (n = 1) and subpleural fibrosis in 4.2% (n = 1).

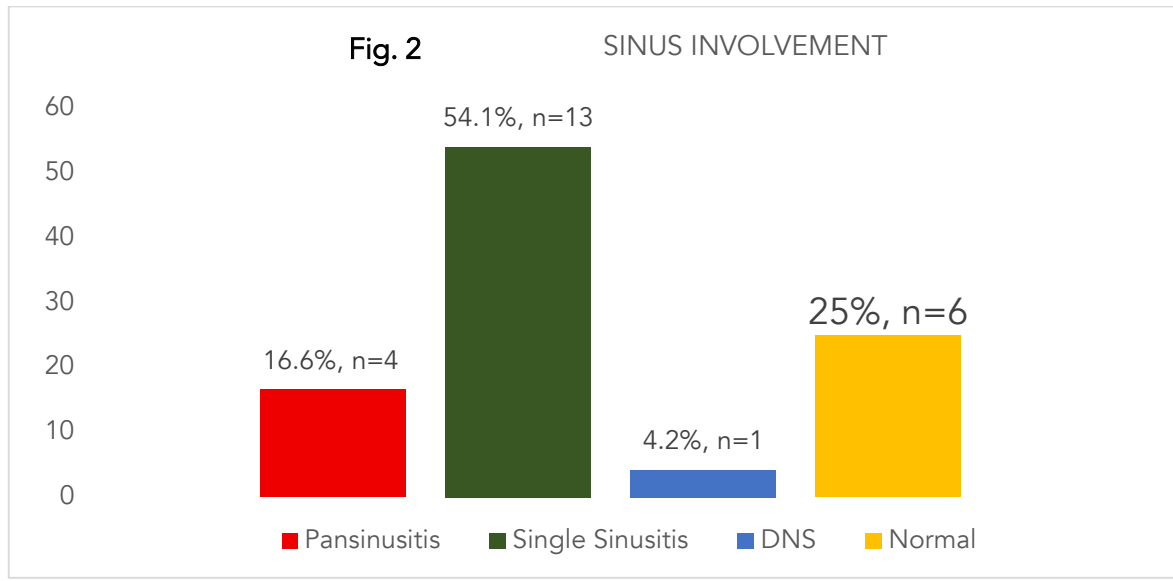


Figure 2: SINUS Involvement

The bar chart illustrates the distribution of sinus abnormalities among the study participants. Single sinusitis was the most common finding, observed in 54.1% (n = 13) of individuals. Pansinusitis was present in 16.6% (n = 4), while 4.2% (n = 1) had a

deviated nasal septum (DNS). A total of 25% (n = 6) showed no sinus involvement and were categorized as normal.

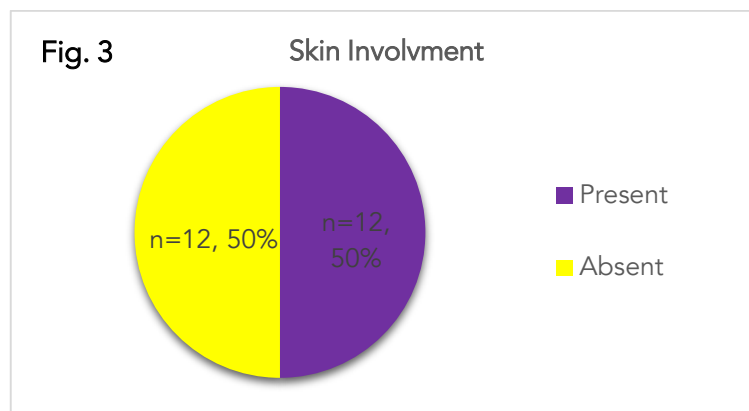


Figure 3: SKIN involvement

The pie chart show that 50% of the cohort had skin lesions.

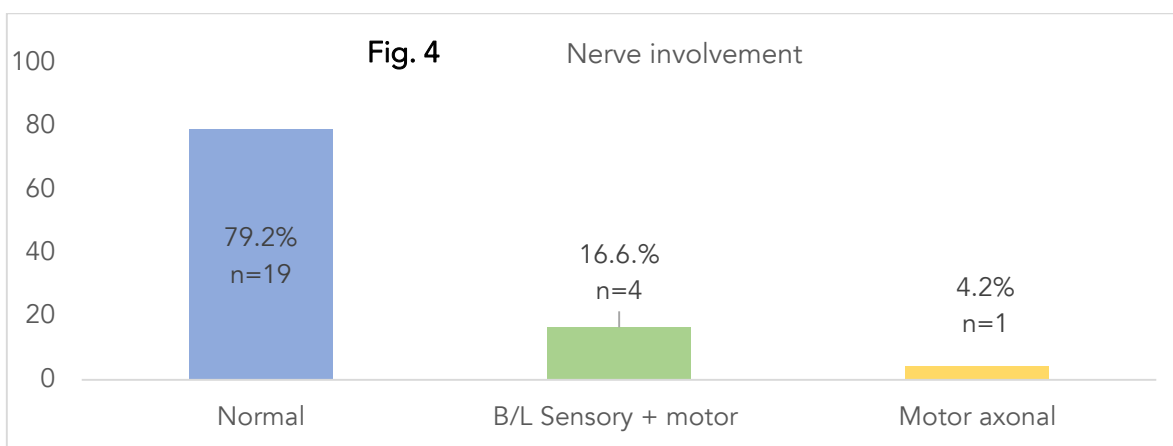


Figure 4: Nerve Involvement

The bar chart depicts the distribution of nerve involvement among the study participants. The majority of individuals (79.2%, $n = 19$) demonstrated normal nerve function. Bilateral

sensory and motor involvement was identified in 16.6% ($n = 4$) of participants, while 4.2% ($n = 1$) showed evidence of motor axonal neuropathy.

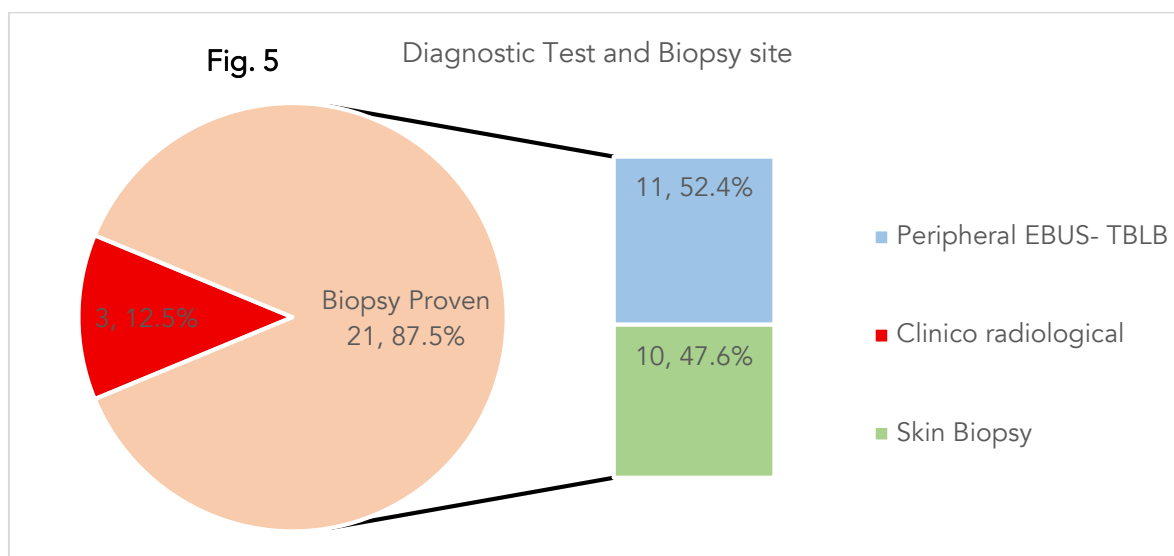


Figure 5: Diagnostic Test and Biopsy Site

In my cohort, 12.5% ($n=3$) were diagnosed clinico-radiologically and rest 87.5% ($n=21$) underwent biopsy from different site with confirmed histopathological diagnosis. Amongst 21 patients,

52.4% ($n=11$) underwent peripheral EBUS-TBLB while 47.6% ($n=10$) patients were diagnosed by skin biopsy.

Table 3: Absolute Eosinophil Count at First Visit and After 3 months of Treatment

AEC	At First Visit		After 3 months		P value
	No. (n=24)	%	No. (n=24)	%	
0-150	4	16.6	10	41.6	0.014 *S
151-499	7	33.3	6	25	
500-999	3	12.5	3	12.5	
1000-1499	3	12.5	0	0	
>1500	3	12.5	1	4.16	
Total	24	100	24	100	
Mean \pm SD	671 \pm 750		288 \pm 501		<0.001 *HS
AEC <150	4		10		0.014 *S

Table 3 compares the Absolute Eosinophil Count (AEC) of patients at the first visit and after three months of treatment. A significant shift toward lower AEC categories was observed following treatment. At baseline, only 16.6% of patients had an AEC of 0–150 cells/ μ L, whereas this proportion increased to 41.6% after three months. Higher AEC ranges (≥ 1000 cells/ μ L) showed a marked decline, with no patients remaining in the 1000–1499 range after treatment and only one patient (4.16%) persisting in the >1500 category. The mean AEC

decreased substantially from 671 \pm 750 cells/ μ L at baseline to 288 \pm 501 cells/ μ L after three months, a change that was highly significant ($P < 0.001$). The overall distribution difference between the two time points was statistically significant ($P = 0.014$).

Table 4: Total IgE at First Visit and After 3 months of treatment

Total IgE	At First Visit		After 3 months		P Value
	No. (n=24)	%	No. (n=24)	%	
<500	19	79.2	21	87.5	0.157 *NS
≥500	5	20.8	3	12.5	
Total	24	100	24	100	
Mean ± SD	1193 ± 4480		558 ± 2072		<0.001 *HS

Table 4 shows the distribution of total IgE levels at the first visit and after three months of treatment. Although there was an increase in the proportion of patients with IgE levels <500 IU/mL (from 79.2% to 87.5%), the overall change in categorical distribution was not statistically significant (P =

0.157). However, the mean total IgE level demonstrated a substantial reduction, decreasing from 1193 ± 4480 IU/mL at baseline to 558 ± 2072 IU/mL after treatment, which was highly significant (P < 0.001).

Table 5: FEV1% predicted at First Visit and After 3 months of treatment

FEV1% predicted	At First Visit		After 3 months		P value
	No. (n=24)	%	No. (n=24)	%	
≥80%	2	8.3	4	16.6	<0.001*HS
≤50% - 80%	11	45.83	18	75	
≤30% - 50%	9	37.5	2	8.3	
<30%	1	4.16	0	0	
Total	24	100	24	100	
Mean ± SD	55.54 ± 16.8		71.25 ± 11.94		<0.001 *HS

Table 5 presents the changes in FEV1 % predicted at the first visit and after three months of treatment. The proportion of patients with FEV1 ≥80% increased from 8.3% to 16.6%, while those in the 30–50% range decreased from 37.5% to 8.3%. No patients remained in the <30% category after

treatment. The mean FEV1 % predicted increased significantly from 55.54 ± 16.8% at baseline to 71.25 ± 11.94% after three months (P < 0.001), demonstrating a significant improvement in pulmonary function following treatment.

Table 6: Fractional exhaled Nitric Oxide (FENO) at First Visit and After 3 months of treatment

FENO	At First Visit		After 3 months		P value
	No. (n=24)	%	No. (n=24)	%	
<25	10	41.7	20	83.3	<0.002*HS
>25	14	58.3	4	16.67	
Total	24	100	24	100	
Mean ± SD	30 ± 19.17		13.71 ± 15.41		<0.001*HS

Table 6 illustrates the changes in fractional exhaled nitric oxide (FENO) at the first visit and after three months of treatment. The proportion of patients with FENO <25 ppb increased from 41.7% to 83.3%, while those with FENO >25 ppb decreased

from 58.3% to 16.7%. The mean FENO level decreased significantly from 30 ± 19.17 ppb at baseline to 13.71 ± 15.41 ppb after treatment (P < 0.001), indicating a substantial reduction in airway inflammation

Table 7: Asthma Control Test (ACT) at First Visit and After 3 months of Treatment

ACT Score	At First Visit		After 3 months		P value
	No. (n=24)	%	No. (n=24)	%	
Well controlled (20-25)	3	12.5	17	70.8	<0.001 *HS
Partially Controlled (16-19)	9	37.5	6	25	
Uncontrolled (5-15)	12	50	1	4.16	
Total	24	100	24	100	
Mean ± SD	15 ± 3.2		20 ± 3.01		<0.001*HS

Table 7 demonstrates changes in asthma control, as measured by the Asthma Control Test (ACT), from the first visit to three months of treatment. The proportion of patients with well-controlled asthma (ACT 20–25) increased from 12.5% to 70.8%, while those with uncontrolled asthma (ACT

5–15) decreased from 50% to 4.16%. The mean ACT score improved significantly from 15 ± 3.2 at baseline to 20 ± 3.01 after treatment ($P < 0.001$), indicating substantial enhancement in overall asthma control.

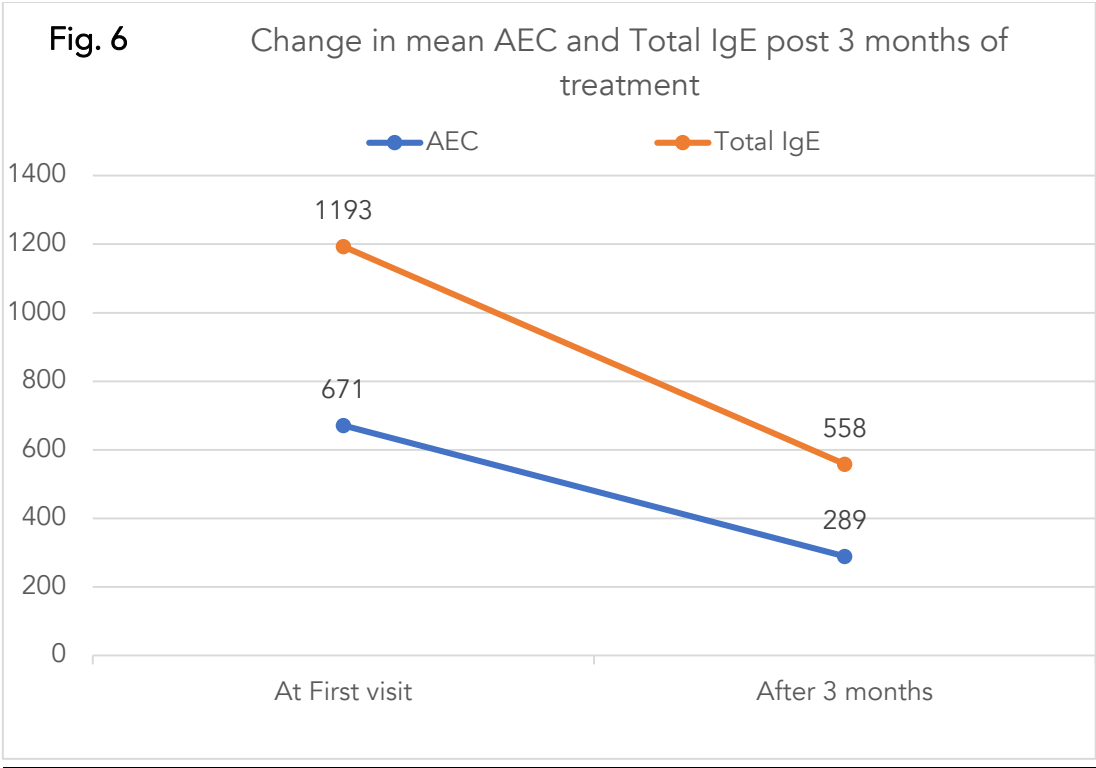


Figure 6: Change in mean AEC and Total IgE post 3 months of treatment

Pictorial presentation of reduction in mean AEC and Total IgE from 671 to 289 and 1193 to 558 respectively after 3 months of treatment with Benralizumab.

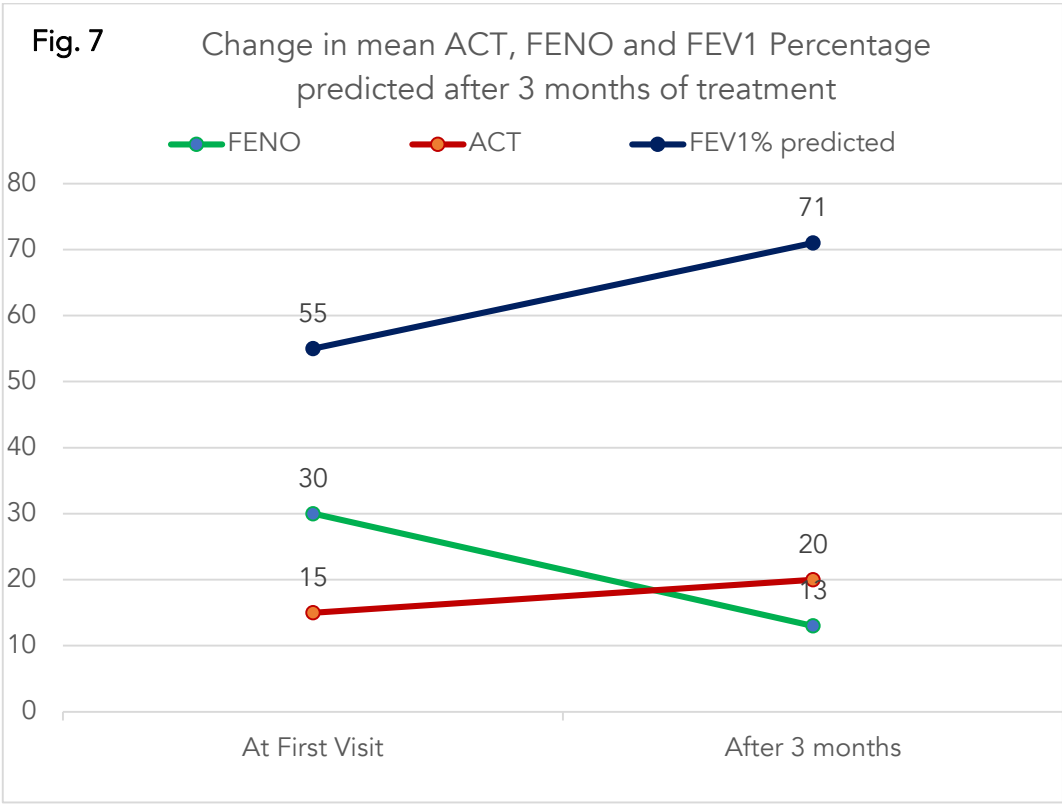


Figure 7: Change in mean ACT, FENO and FEV1 % predicted after 3 months of treatment

Pictorial presentation of reduction in mean FENO from 30 to 13 and increase in mean ACT and FEV1 % predicted from 15 to 20 and 55% to 71% after 3 months of treatment.

Discussion:

We conducted a study on 24 diagnosed cases of eosinophilic granulomatosis with polyangiitis (EGPA) in which we evaluated their clinico-radiological profile, symptom score, lung function parameters, and response to targeted biological therapy with Benralizumab after 3 months.

STUDY POPULATION AND DEMOGRAPHICS:

The mean age of our cohort was 57.7 ± 14.4 years, consistent with the age distribution noted in European and Asian EGPA registries, where the peak incidence typically occurs between 50–60 years. Comarmond et al.¹⁰ showed mean age of 50.3 years. Females constituted 54.2% of the study population, aligning comparable to published cohorts showing slight female predominance or comparable results with no male predominance¹⁰⁻¹¹. Another study in Doublet et al.¹² in American population showed similar results where mean age was 50 years and females constituted 59% of the population. Sada et al.¹³, a Japanese study reported mean age 55 years and male: female ratio -1:2.

Bronchial asthma was the most common antecedent condition (83.3%), aligning with classical descriptions where asthma nearly universally precedes systemic vasculitis as seen in Comarmond et al.¹⁰ where 91% cases had asthma. Doublet et al.¹² reported 69% patients with bronchial asthma. The most frequently found comorbidity was DM seen in 50% patients followed by HTN in 29.1% patients and Obstructive sleep apnea seen in 12.5% patients.

LABORATORY FINDINGS:

Peripheral eosinophilia is a hallmark of EGPA. The mean AEC in our study was 671 cells/ μ L, with AEC >150 in 83.3% cases and severe eosinophilia (>1000 cells/ μ L) in 25% cases. Total IgE was >500 kU/L in 20.8% patients and mean value was 1193 kU/L. Davanzo F, et al.⁹ reported peripheral eosinophilia 850 cells/ μ L.

ANCA positivity was observed in 41.7%, similar to global reports indicating ANCA positivity in 30–40% of EGPA patients¹¹. Comarmond et al.¹⁰ and Sada et al.¹³ showed positivity rate of 50% and 67.8% respectively. Matucci A et al.⁷ showed ANCA

positivity in 38.1% cases and the mean serum IgE 505.7 ± 667 kU/L. Nazer et al.¹⁴ showed ANCA positivity in 36% cases.

All patients fulfilled the 2022 EULAR criteria for EGPA, which have a reported sensitivity of 85% and specificity of 99% (Grayson PC et al.¹⁵ and Emmi G et al.¹¹). The mean score in our cohort was 8.17 ± 1.5 . This underscores that the EULAR criteria serve as a practical and essential screening tool for patients suspected of EGPA, with a score ≥ 6 warranting further diagnostic evaluation.

RADIOLOGICAL AND CLINICAL MANIFESTATIONS:

Radiological abnormalities were present in all patients on HRCT thorax (fig. 1). Ground-glass opacities were the most common finding (54.2%), followed by centrilobular nodules (29.1%), consolidation (8.3%), and a mixed pattern of centrilobular nodules with patchy GGOs or subpleural fibrosis (4.2% each). Subpleural fibrosis was uncommon, suggesting early or non-fibrotic disease. Trivioli G et al.¹⁶, Kim Y.K. et al.¹⁷ and Cottin V et al.¹⁸ report GGOs or infiltrates in 40–50% of cases.

Sinonasal involvement (fig. 2) was frequent (71%), with pansinusitis in 16.6% consistent with the reported prevalence of 45–75%. Skin involvement (fig. 3) was present in 50% cases comparable to usual prevalence of 40–60%. Comarond et al.¹⁰ observed skin lesion in 39% patients and Marques CC et al.¹⁹ in 50% cases. Neuropathy (fig. 4) was detected in 20.8% patients, lower than standard prevalence rate reported of 50–70%^{10,20} but in consistent with lower rate 9% reported by Nanzer et al.¹⁴ -likely reflecting earlier disease detection in our cohort. Doublet et al.¹² reported 22% patients with mononeuritis multiplex and 35% patients with sensory neuropathy.

Histopathological confirmation (fig. 5) was obtained in 87.5% of patients. Skin biopsy was performed in 47.6% and peripheral EBUS guided TBLB in 52.3% cases. Both the tests are minimally invasive but peripheral EBUS- TBLB is more definitive diagnostic yield, as skin lesions may be old or non-representative. HPE was suggestive of perivascular and peri adnexal inflammation along with eosinophilic infiltration of vessel wall along with ill formed granuloma in most of the patients 83.3%²¹⁻²³.

TREATMENT RESPONSE WITH BENRALIZUMAB:

All patients received Benralizumab, and treatment response at 3 months was assessed both subjectively and objectively.

The change in AEC count was statistically significant ($p = 0.014$) and the mean AEC count was reduced from 671 to 288 ($p < 0.001$) with the proportion of patients achieving AEC < 150 increasing from 4 to 10 ($p = 0.014$) (Table 3, Fig.6). Total serum IgE declined significantly from a mean of 1193 to 558 kU/L ($p < 0.001$) (Table 4, Fig.6).

Lung function improved markedly: the improvement in FEV1% predicted after 3 months so therapy was also statistically significant ($p < 0.001$) and the mean FEV1 % predicted increased from 55% to 71% ($p < 0.001$) (Table 5, Fig.7). The number of patients with FENO < 25 ppb increased from 10 to 20 (41.7% to 83.3%) ($p < 0.002$). The mean FENO decreased from 30 to 13ppb ($p < 0.001$) (Table 6, Fig.7) suggesting that treatment targeting EGPA improved both asthmatic and vasculitis components.

The mean Asthma control test was 15 at the time of diagnosis and increased to 20 post 3 months of treatment (Table 7, Fig.7). The change in ACT was statistically significant ($p < 0.001$) suggesting better symptomatic control. Rowell J, et al.²⁴, a systematic review of 8 studies also reported significant improvement in symptom control via ACT and ACQ after eosinophil depleting therapies in EGPA i.e. Benralizumab.

COMPARISON WITH PUBLISHED LITERATURE:

A meta-analysis of 396 EGPA patients showed the efficacy of Benralizumab in reducing OCS requirements and achieving remission²⁵. Additional studies have shown similar response^{14,26-27}. Martínez-Rivera et al.²⁸ reported case of EGPA where eosinophil count reduced from 2300 to 0 cells/ μ L and FEV1% predicted increased from 28% to 51% on day 9 of treatment of Benralizumab. Laviolette M et al.²⁹ showed complete suppression of peripheral eosinophilia after 1 month of therapy respectively. Nanzer et al.¹⁴ demonstrated improvement in ACQ from 2.4 to 1.71 after 24 weeks of therapy. Jackson et al.³⁰, a meta-analysis of 39 studies reported remission rates 46% to 69% after 1 year and 66% to 71% after 2 years. There was significant oral corticosteroid sparing effect with complete discontinuation in 32% to 68% patients. Padoan R et al.³¹ reported 24 weeks treatment with benralizumab reduced the glucocorticoids use markedly and improved symptoms and overall outcomes.

Our study corroborates these results in a real-world Indian cohort, demonstrating early and significant benefits of benralizumab therapy.

Conclusion:

In this cohort of 24 patients with eosinophilic granulomatosis with polyangiitis, early diagnosis guided by the 2022 EULAR criteria enabled timely initiation of targeted therapy. Clinico-radiological patterns—including predominant asthma, peripheral eosinophilia, characteristic HRCT findings, and frequent sinonasal and dermatological involvement—were largely consistent with global epidemiological profiles. Bronchial asthma does not cause any structural abnormality in lungs therefore any patient of Bronchial Asthma with changes in HRCT thorax should be evaluated further for additional pathology. Histopathology, particularly via peripheral EBUS-guided TBLB, provided strong diagnostic confirmation.

Benralizumab demonstrated significant clinical, functional, and biomarker improvement within just 3 months of therapy. Marked reductions were observed in eosinophil counts, serum IgE, and FeNO levels, along with substantial gains in FEV₁ and asthma control scores. These results affirm the efficacy of Benralizumab in targeting both the eosinophilic and vasculitis components of EGPA, supporting its role as a valuable therapeutic option in disease management. Early recognition and prompt biologic treatment may help prevent long-term organ damage and improve overall patient outcomes.

Conflict of Interest Statement:

There are no conflicts of interest.

Funding Statement:

There is No funding taken for the research.

Acknowledgment:

The authors gratefully acknowledge the participation and cooperation of all patients included in this study. We extend our appreciation to the clinical, nursing, and allied health staff of Respiratory Medicine department for their support in patient evaluation, imaging, and laboratory analysis.

The authors also thank the colleagues who provided scientific input during the study planning and manuscript review. Access to benralizumab

through a patient-support initiative is duly recognized, with no role of the provider in the study design, data interpretation, or publication decisions.

This study was conducted in accordance with institutional ethical guidelines, and no financial

support or sponsorship influenced the conduct or reporting of this work.

References:

1. Lazzeroni M, Longoni V, Bizzi E, et al. Anti-IL5/IL-5 receptor therapies for eosinophilic granulomatosis with polyangiitis: an updated systematic review. *Front Immunol*. 2025;16:1587158.
2. Raffray L, Guillevin L. Updates for the treatment of EGPA. *Presse Med*. 2020;49(3):104036.
3. Mukhtyar C, Guillevin L, Cid MC, et al. EULAR recommendations for the management of primary small and medium vessel vasculitis. *Ann Rheum Dis*. 2009;68(3):310-317.
4. Jakes RW, Kwon N, Nordstrom B, et al. Burden of illness associated with eosinophilic granulomatosis with polyangiitis: a systematic literature review and meta-analysis. *Clin Rheumatol*. 2021;40(12):4829-4836.
5. Berti A, Atzeni F, Dagna L, et al. Targeting the interleukin-5 pathway in EGPA: evidence, uncertainties, and opportunities. *Ann Rheum Dis*. 2023;82(2):164-168.
6. Koike H, Nishi R, Yagi S, et al. A review of anti-IL-5 therapies for eosinophilic granulomatosis with polyangiitis. *Adv Ther*. 2023;40(1):25-40.
7. Matucci A, Vivarelli E, Perlato M, et al. EGPA phenotyping: not only ANCA, but also eosinophils. *Biomedicines*. 2023;11(3):776.
8. Pelaia C, Calabrese C, Vatrella A, et al. Benralizumab: from the basic mechanism of action to the potential use in the biological therapy of severe eosinophilic asthma. *BioMed Res Int*. 2018;2018:4839230.
9. Davanzo F, Iorio L, Codirenzi M, et al. Long-term effectiveness and safety of benralizumab in EGPA: a 3-year single-center experience. *Ann Med*. 2025;57(1):2581812.
10. Comarmond C, Pagnoux C, Khellaf M, et al. Eosinophilic granulomatosis with polyangiitis (Churg-Strauss): clinical characteristics and long-term follow-up of 383 patients enrolled in the French Vasculitis Study Group cohort. *Arthritis Rheum*. 2013;65(1):270-281.
11. Emmi G, Bettiol A, Gelain E, et al. Evidence-based guideline for the diagnosis and management of eosinophilic granulomatosis with polyangiitis. *Nat Rev Rheumatol*. 2023;19(6):378-393.
12. Doubelt I, Cuthbertson D, Carette S, et al. Clinical manifestations and long-term outcomes of eosinophilic granulomatosis with polyangiitis in North America. *ACR Open Rheumatol*. 2021;3(6):404-412.
13. Sada KE, Amano K, Uehara R, et al. A nationwide survey on the epidemiology and clinical features of eosinophilic granulomatosis with polyangiitis (Churg-Strauss) in Japan. *Mod Rheumatol*. 2014;24(4):640-644.
14. Nanzer AM, Dhariwal J, Kavanagh J, et al. Steroid-sparing effects of benralizumab in patients with eosinophilic granulomatosis with polyangiitis. *ERJ Open Res*. 2020;6(4):00165-2020.
15. Grayson PC, Ponte C, Suppiah R, et al. 2022 American College of Rheumatology/European Alliance of Associations for Rheumatology classification criteria for eosinophilic granulomatosis with polyangiitis. *Arthritis Rheumatol*. 2022;74(3):386-392.
16. Trivioli G, Terrier B, Vaglio A. Eosinophilic granulomatosis with polyangiitis: understanding the disease and its management. *Rheumatology (Oxford)*. 2020;59(Suppl 3):iii84-iii94.
17. Kim YK, Lee KS, Chung MP, et al. Pulmonary involvement in Churg-Strauss syndrome: analysis of CT, clinical, and pathologic findings. *Eur Radiol*. 2007;17(12):3157-3165.
18. Cottin V, Bel E, Bottero P, et al. Respiratory manifestations of eosinophilic granulomatosis with polyangiitis (Churg-Strauss). *Eur Respir J*. 2016;48(5):1429-1441.
19. Marques CC, Fernandes EL, Miquelin GM, Colferai MM. Cutaneous manifestations of Churg-Strauss syndrome: key to diagnosis. *An Bras Dermatol*. 2017;92(1):56-58.
20. White JP, Dubey S. Eosinophilic granulomatosis with polyangiitis: a review. *Autoimmun Rev*. 2023;22(1):103219.
21. Fagni F, Bello F, Emmi G. Eosinophilic granulomatosis with polyangiitis: dissecting the pathophysiology. *Front Med (Lausanne)*. 2021;8:627776.
22. Carlson JA. The histological assessment of cutaneous vasculitis. *Histopathology*. 2010;56(1):3-23.
23. Tabb ES, Duncan LM, Nazarian RM. Eosinophilic granulomatosis with polyangiitis: cutaneous clinical and histopathologic differential diagnosis. *J Cutan Pathol*. 2021;48(11):1379-1386.
24. Rowell J, et al. Measuring the humanistic burden of EGPA: a systematic review. *Ann Rheum Dis*. 2024;83:1958-1959.
25. Spataro F, Solimando AG, Di Girolamo A, et al. Efficacy and safety of benralizumab in eosinophilic

granulomatosis with polyangiitis: a meta-analysis of eight studies. *Eur J Clin Invest*. 2025;55(2):e14333.

26. Guntur VP, Manka LA, Denson JL, et al. Benralizumab as a steroid-sparing treatment option in eosinophilic granulomatosis with polyangiitis. *J Allergy Clin Immunol Pract*. 2021;9(3):1186-1193.

27. Nanzer AM, Maynard-Paquette AC, Alam V, et al. Long-term effectiveness of benralizumab in eosinophilic granulomatosis with polyangiitis. *J Allergy Clin Immunol Pract*. 2024;12(3):724-732.

28. Martínez-Rivera C, Garcia-Olivé I, Urrutia-Royo B, et al. Rapid effect of benralizumab in exacerbation of severe eosinophilic asthma associated with eosinophilic granulomatosis with polyangiitis. *BMC Pulm Med*. 2021;21(1):35.

29. Laviolette M, Gossage DL, Gauvreau G, et al. Effects of benralizumab on airway eosinophils in asthmatic patients with sputum eosinophilia. *J Allergy Clin Immunol*. 2013;132(5):1086-1094.

30. Jackson DJ, Wechsler ME, Bleecker ER, et al. Systematic literature review of real-world outcomes of benralizumab in eosinophilic granulomatosis with polyangiitis. *J Allergy Clin Immunol Pract*. 2025;13(11):3054-3065.e4.

31. Padoan R, et al. Benralizumab as a glucocorticoid-sparing treatment option for severe asthma in eosinophilic granulomatosis with polyangiitis. *J Allergy Clin Immunol Pract*. 2020;8(9):3225-3227.e2.