

**Oxygen transport to diseased hind limb :
A comparison of medical treatments**

Authors:

T. Koyama^a

T. Sasajima^b

S.Kikuchi^c

Authors Note

a:Hokkaido Univ. emeritus, Sapporo,

b:Asahikawa Medical Univ. emeritus,
Asahikawa, Japan

c:Asahikawa Medical Univ.

Corresponding author

Tomiyasu Koyama

e-mail address: (tomkoyamajp@yahoo.co.jp)

Abstract To rescue severely affected hind limbs from amputation, the surgery of the distal vein arterialization DVA technique has been used and refined in respect of different theoretical and pathophysiological aspects; tissue cylinder model, total venular length, oxygen diffusion to muscles, water movements are discussed under the surgically introduced unusual circumstances. All these variables are interrelated to support the fundamental oxygen utilization of muscle tissues to survive. Separately carried out studies and techniques are summarized here. The therapeutic results of DVA surgery were compared with angiogenic and pharmacological treatments in respect of peripheral arterial disease.

Key words: peripheral arterial disease, distal vein arterialization, tissue cylinder model, oxygen diffusion, angiogenetic treatment, pharmacological treatment

**Oxygen transport to diseased hind limb :
A comparison of medical treatments**

1 Introduction:

The foot muscle of standing human hind-limbs is compressed by body weight, hydrostatic and arterial blood pressure. The blood flow may transiently be hindered in human hind limbs.. In experimental animals 90 minutes occlusion of femoral artery results in increases in lysosomes, edema in muscle cells and edematous changes in vascular endothelial cells (Apell [1]). The following reperfusion for 60 minutes intensifies edematous changes in muscles and vascular endothelial cells accompanied with protein loss (Apell [2]). Shortly hind limbs are often exposed to destructive stresses. 10.5 million people in the United States suffer from intermittent or chronic peripheral pain in the hind limbs [3] Criqui? . Some of them are subjected to the chronic hard pain and treated with amputation. The human life after amputation is inconvenient. But 8000

Japanese patients were treated by the amputation in the year 2001.. Peripheral arterial disease (PAD) in human patients causes ischemic rest pain, ulcerations and often gangrene. Some patients require surgical revascularization or amputation. Since the vascular destruction in PAD starts on peripheral arteries of the hind limb, distal vein arterialization is made as one of the surgical methods to improve the tissue reoxygenation (distal vein arterialization, DVA) [4](Sasajima et al.). Recently biochemical and angiogenetic treatments are developing for the treatment of PAD. In the present article we summarize the DVA treatment and compare with the pharmacologic and angiogenetic treatments.

2.Methods

2.1 A scheme for the peripheral circulatory system in DVA (Fig.1)

Oxygen transport to diseased hind limb :
A comparison of medical treatments

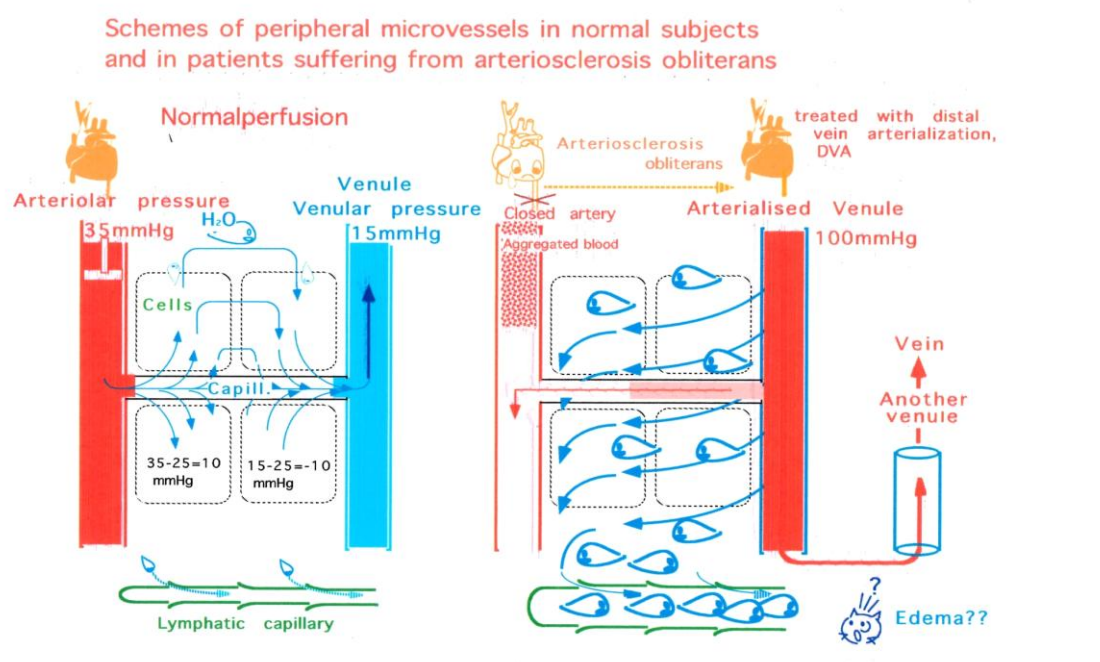


Fig.1 Schematic presentation of the blood and water movements in the distal vein arterIALIZation modified from Ref. 9. The valve in the retrogradely perfused venule is forced to open.

The peripheral circulatory system is schematically depicted previously [5]. The oxygenated blood is pumped out by the left ventricle, flows into an arteriole (left). The pumped oxygenated blood flows into a capillary expressed by a horizontal column. Oxygen diffuses out of the capillary to surrounding tissues according to the oxygen gradient caused by muscle cell respiration and is consumed. The water component is pushed out into the tissue because of the hydraulic pressure gradient and flows back into the later half of the capillary because of the low hydrostatic pressure on the venular side on the half way of the capillary. Since arterioles are affected in PAD, a small healthy arterial branch is brought to be

connected with a small vein by DVA surgery (right). Now the oxygenized blood flows directly into a venule. The blood flowing through the venule transmits some amount of oxygen and fluid to the surrounding tissue. The oxygen is consumed by muscle cells, while the fluid can not flow back to the venule but probably collected by the lymphatic network (below). The lymphatic flow-out depends on the total surface area. The total surface area in DVA is much reduced, since blood flows mostly through the venular network and not flows into the capillary network. The overflow fluid caused practically no serious effects on lymphatic pressure because of the generally large lymphatic capacity and the reduced surface

**Oxygen transport to diseased hind limb :
A comparison of medical treatments**

area of effective surface area.

2.2 Venular valves

The increase in the blood volume in large veins causes destructive effects on important organs such as liver and heart. The venous hypertension reduces the physiological function of main organs such as the liver and kidney. A healthy small artery branch should be selected for the arterial blood supply and connected with a small foot vein.

Venular networks are equipped with small valves to limit the retrograde blood flow. Fine valves can be found also in the thin venule with a diameter of $18\mu\text{m}$ [6].

The first question is whether venular valves permit arterial blood to flow into the venular network. In one of our previous studies in rats the femoral artery was anastomosed to the femoral vein. However the arterial blood could not flow into the popliteal vein. Only when the popliteal venous valve was destructed by the use of a thin guide wire, the arterial blood could attain the venular network in the peripheral foot tissue [7].

The distension in the thin venular walls permitted a retrograde inflow of the arterial blood to the peripheral thin venules. The increase in arterial pressure introduced into the venous system renders their valve leaflets incompetent. The venular valve leaflets cannot close the venular lumen against the arterial blood pressure. This consideration was consistent with the physical analysis based on the Laplace equation and confirmed using thermography and fluorescein infusion

in the rat model [7]

The intra-arterial injection of fluorescein-containing saline into the venous system above the knee, when valves in popliteal vein were destructed by means of a thin guide wire, fluorescein could flow to the foot periphery accompanied with a sharp rise in the skin temperature in the foot [7].

2.3 Oxygen supply in the tissue cylinder surrounding venules.

The start of distal vein perfusion recovers quickly the skin color of the affected foot.

The tissue oxygenation can be analyzed mathematically. The total length of venular nets is reported 4.43 mm/mm^3 in rat skeletal muscle (2.32 mm/mm^3 for the collecting venule and 2.11 mm/mm^3 for the arcade venule) in the skeletal muscle [9] (Engelson et al.). If these vessels were stretched and connected to form a single, narrow venular tube, the total density would be 4.43 mm/mm^3 . From the reciprocal of this value, the tissue cylinder surrounding the venule would have a radius of $268\mu\text{m}$. Taking an oxygen consumption rate for resting skeletal muscle of 0.16 ml/100g/min , and pO_2 value of 40 mmHg at the end of the venular cylinder, the one-dimensional diffusion equation gives a maximal diffusion distance of $328\mu\text{m}$.

Since oxygen consumption rate of skeletal muscle at rest is given to be $0.89\sim 1.6 \times 10^{-3} \text{ ml/min/100g}$. The maximum oxygen front at rest is calculated to be $587\sim 328\mu\text{m}$ which is

**Oxygen transport to diseased hind limb :
A comparison of medical treatments**

greater than the calculated tissue cylinder radius ($268\mu\text{m}$, [7][8] Oxygen Transp Tissue XXXlii 335-339, XXXV245-250). The quiet walk, however, causes an increase in oxygen consumption rate (7.9×10^{-3} ml $\text{O}_2/\text{min}/\text{gr}$ at 5.6 km/hr walk) and reduces oxygen front at the outlet of the tissue cylinder to $197\mu\text{m}$ which is smaller than the above imaginary radius of the tissue cylinder. In other words anoxic area may be induced in the tissue cylinder near the outlet, which may be called a dead corner. In other words in the actually treated hind limbs the quiet walk will cause a massage action on peripheral blood vessel networks. The infused blood flow may not be restricted to venular nets but extend to capillary ones. The perfused tissue area increases. In other words tissue cylinder would be thinner in DVA-supported hind limb muscle than in the simple venular network at rest. The muscle contraction causes an increase in the massage action of the peripheral blood flow.

2.4 Short circuited flowout of infused arterial blood, a leakage of the blood flow

The venous system consists of many anastomosing branches, venular networks and outflows. The introduced arterial blood may eventually open new outlets to other venous route. The blood may leave skeletal muscles through newly formed short cut route of outlet without delivering oxygen to muscles sufficiently. If a new outlet is formed, then it should be shut down. Oezeck [9] recommended to close even the saphenous

vein when necessary

2.5 Skin flap and expected VEGF supply

Vascular endothelial growth factor, VEGF, is the most effective factor to stimulate endothelial cell proliferation and vascular formation. The concentration of VEGF in plasma can be an index for PAD ([10]Findley). Plasma VEGF is reduced in diabetic patients. VEGF is produced mainly by endothelial cells and keratinocytes [11](Jonson and Wilgus. Wound healing).

[Adv Wound Care \(New Rochelle\)](#). 2014 Oct 1;3(10):647-661.

Vascular Endothelial Growth Factor and Angiogenesis in the Regulation of Cutaneous Wound Repair.

[Johnson KE1, Wilgus TA2.](#)

The covering of the surgically treated area with skin flap prepared from patients' own but unaffected tissue is an effective procedure to accelerate the recovery of the treated hind limbs from wound ([4]Sasajima). The type of free flap was selected, being based on the size of tissue loss, harvested from the rectus abdominis, the scapular fasciocutaneous flap, or latissimus dorsi. The free flap artery was anastomosed to the distal site of the DVA graft in an end-to-side manner. The vein of the free flap was anastomosed to the proximal segment of the vein used for DVA, such as the terminal posterior tibial vein or the dorsal pedal vein. Serial angiographies were performed to evaluate blood supply patterns and DVA outcome ([4]Sasajima).

**Oxygen transport to diseased hind limb :
A comparison of medical treatments**

2.6 Role of venular valves on the arterial blood infusion in the reversed direction

The venous valves may resist against the reversely introduced arterial blood to flow into the microvascular or venular system in the foot. A check was intended to answer this question. In a preceding study the femoral artery was anastomosed to the femoral vein in anesthetized rats (Sasajima ..Koyama OTT 36 [12][18]?). The reversibly introduced arterial blood could not flow into the popliteal vein which has intact valves. The inflow to the popliteal vein and foot was observed only when the popliteal venous valves were destroyed by means of a thin guide wire. Fluorescein inflow and sharp rise in skin temperature in popliteal vein could be observed only in rats whose popliteal venous valves had been destroyed.

2.7 VEGF and skin flap

Peripheral arterial disease (PAD) in human patients causes ischemic rest pain, ulcerations, often gangrene disease and ischemic rest pain. Some patients require surgical revascularization or amputation. Since the vascular destruction in most PAD patients starts on peripheral arteries, the surgical reoxygenation should be made on the venous side. The surgically treated area should be covered with the skin flap which had been prepared on the patients' own healthy body surface. The artery and vein of the flap are microscopically connected with the healthy blood vessels nearby.

The expected roles of the skin flap-covering

is the automatic supply of the vascular endothelial growth factor, VEGF, to the DVA treated wounded area. VEGF strongly supports the revascularization of the destructed foot tissues.

The application of the arterial blood pressure onto the venous vascular net may destruct venous vascular cells and cause a varicoes-like changes in the venular network [14] (Takase S et al.) . VEGF supplied by the freshly planted flap acts to preserve or rebuild the venous networks.

Medical treatments for PAD

There are four types of treatments of PAD at present; 1. Pharmacological agent, Cilostazol per os, [15]. 2. Therapeutic angiogenesis, intramuscular injection of VEGF, 3. Proteomics-based approach, intramuscular implantation of bone marrow-mononuclear cells [16] and 4. Distal vein arterialization (DVA). The healthy small arterial blood flows through the venular network in muscles and provides oxygen to the surrounding tissues in DVA coupled with covering with the surgically treated area with free skin flap prepared from patient's own skin [3]. The healthy skin produces VEGF to stimulate sprouting of new blood vessels in foot muscles.

In the present study the therapeutic usefulness of the pharmacological, angiogenetic and DVA methods was compared in relation with ankle brachial index (ABI) of successfully treated patients.

**Oxygen transport to diseased hind limb :
A comparison of medical treatments**

The index, ABI, is widely used for the evaluation of vascular resistance in the foot. The severity of PAD is evaluated by the reduction in ABI because of the ease in the practice. However, it should be remembered that the blood pressure in the ankle artery is often difficult to measure in diabetic patients because of the calcification of the artery wall. The calcified ankle artery often can not be compressed by the cuff inflation maneuver. ABI in diabetic patients was, therefore, discarded from consideration. Moreover, Findley et al [10] found no correlation between ABI and the severity of PAD. Kikuchi et al. [12] confirmed inactive VEGF in the peripheral blood. VEGF was rather low in diabetic peripheral blood.

Despite these confusions mean and \pm SD or ranges for ABI values mentioned by five publications classified by medical treatments are listed below for comparison with DVA..

Results

Effects of different Medical Treatments on ABI in PAD patients

Some medicaments are reported to improve

the walking capacity of patients suffering from peripheral arterial disease. Some related treatments and ABI (ankle-brachial index) values measured before the start of the treatments are listed here. Bone marrow mononuclear cells are expected to produce vascular endothelial cell growth factor in the muscle. The cells were implanted to the skeletal muscle. Cilostazol suppresses cAMP and also adenosine degradation by phosphodiesterase inhibition.

It can be seen that DVA surgery was carried out in severely suffering patients. ABI values were strongly reduced. Three diabetic patients were excluded from DVA table. Their ABI could not be determined since ankle blood pressure could not be determined because of the calcification of the ankle blood vessel. In the patients who received the bone marrow implantation ABI values were higher than in DVA surgery. Cilostazol was given per os to the patients who had higher ABI values. Average values for PAD and TAO are shown separately (PAD, peripheral artery disease and TAO, tromboangitis obliterans)

Authors	ABI	Treatments
Sasajima et al [4]	0.21 \pm 0.17	DVA, Microvascular surgery
Taylor RS et al [7]	0.16 \pm 0.28	DVA, Microvascular surgery
Tateishi et al.[8]	0.35 \pm 0.14	Bone marrow, Intramuscular implantation
Matoba et al.[6]	0.6 & 0.8	Bone marrow, Intramuscular implantation* PAD & TAO
Money SR et al.[11]	0.6 & 0.8	Cilostazol 200mg oral uptake* PAD & TAO

**Oxygen transport to diseased hind limb :
A comparison of medical treatments**

4. Discussion

The surgical DVA has been applied to patients most severely suffering from the shortage of blood flow and oxygen in hind limbs. Patients of this group suffered from severe ulcers too. After the completion of the surgery the whole surgically treated area was covered with the free flap prepared from their own healthy skin. The ulcer disappeared in a few weeks after DVA surgery. The vascular wall cells in the skin flap prepared from the healthy skin may secrete vascular endothelial growth factors and stimulate the formation of new vascular networks [13] in the rescued muscles. The muscle damage caused by ischemia followed by reperfusion of the coronary blood vessel is well known in the heart muscle. A similar engraving effects by ischemia followed by reperfusion is known also in skeletal muscles of the hind limb. [1, 2]

When spreading endothelial cells on collagen plate, it takes 20 days for them to proliferate and form a capillary network-like structure (Folkman)[14]. To reconstruct peripheral vascular networks in patients, a quick procedure for vascular reconstruction is required against the quickly proceeding aggravation of the hind limbs.

The severely restricted hind limbs are notified with low ABI. The muscle tissue is

destroyed because of the oxygen shortage. The normalization of the muscle requires a recovery of the oxygen supply. The recovery of oxygen route by DVA seems reasonable.

5. Conclusion

It seemed probable that suitable pharmacological treatment and/or therapeutic angiogenesis were selected for patients in each field of treatments having milder disorder in peripheral blood flow.

DVA surgery provides a unique vascular surgery for the heavily affected hind limbs. However, there remain still problems to be cleared in respects of the fragility of venous networks to the arterial blood pressure and leakage of the infused arterial blood through nearby venous networks.

The technical and physiological aspects related to the surgery of distal vein arterialization DVA are described comprehensively in the present article. Patients having severely disturbed peripheral tissues and low values in ABI need the distal vein arterialization surgery.

Acknowledgements Thanks are due to Professor Dr. Ian Silver and Professor Dr. Maria Erecinska for their kindest reading of the manuscript and valuable suggestions.

**Oxygen transport to diseased hind limb :
A comparison of medical treatments**

References

1. Apell HJ et al. (1993) Skeletal muscle damage during tourniquet-induced ischaemia. The initial step towards atrophy after orthopaedic surgery? *Eur.J Appl Physiol Occup Physiol.* 67(4):342-7
2. Apell HJ et al. (1997) Administration of tourniquet. II. Prevention of post- ischemic oxidative stress can reduce muscle edema.*Arch Orthop Trauma Surg.* 116(1-2):101-5.
3. Criqui MH.(2001) Peripheral arterial disease-epidemiological aspects. *Vasc Med.*6(3 Suppl):3-7.
4. Sasajima T, Azuma N, Uchida H et al. (2010) Combined distal venous arterialization and free flap for patients with extensive tissue loss. *Annals of Vasc. Surgery* (2010) 24(3):373-81
- 5 Koyama T, Sasajima T, Kikuchi S. (2014) Physiological aspects of oxygen transport to peripheral tissue by retrograde perfusion (distal vein arterialization) in: *Advances in Medicine and Biology, NOVA biomed.* Berhardt LV editor. vol. 73. chapt.9, 149-156.
6. Caggiati A, Phillip M et al. (2006) Valves in small veins and venules. *Eur J Vasc Endovasc Surg.* 32(4):447-452
7. Sasajima T, Kikuchi S, Ishikawa N, Koyama T (2014). Skin temperature in lower hind limb subjected to distal vein arterialization in rats. *Oxygen Transport to Tissue* vol.XXXVI 2014 Springer Verlag.361-368.
8. Engelson EL, Schmid-Schoenbein GW, Zweifach BM (1985). The microvasculature in skeletal muscle III. Venous network anatomy in normotensive and spontaneously hypertensive rats. *Intern J Microcirc.: Clin. Exp* 4, 229-248.
9. Koyama T & Sasajima T (2011) Sufficient oxygen can be transported to resting skeletal muscle via arterialization of the vein: Theoretical considerations in a rat model. *Oxygen Transport to Tissue* vol.XXXII Springer Verlag. vol. 32. 335-339.
10. Koyama T, Sugihara-Seki M, Sasajima T, Kikuchi S (2014). Venular Valves and retrograde perfusion. *Oxygen Transport to Tissue.* vol.XXXVI Springer. Verlag (editors; HM Schwartz, DK Harison, DF Bruley) vol. 36:317-323.
11. Johnson KE, Wilgas TA. (2014) Vascular Endothelial Growth Factor and Angiogenesis in the Regulation of Cutaneous Wound Repair. [Adv Wound Care \(New Rochelle\)](#). 3(10):647-661.
12. Oezbek C et al. (2005). A novel approach: Ascending venous arterialization for Atherosclerosis obliterans. *Eur J Vasc Endovasc Surg* 29:47-51.
13. Findley CM. et al. (2008). Critical determinants of limb ischemia. *J. Am Coll Cardiol.* 52:387-393.
14. Kikuchi, R. et al. (2014) An antiangiogenic isoform of VEGF-A contributes to impaired vascularization in peripheral artery disease. *Nat. Med.* 20,

**Oxygen transport to diseased hind limb :
A comparison of medical treatments**

1464–1471

15. Taylor RS, Belli A-M, Jacob S. (1999) Arteriovenous anastomosis in the treatment of gangrene of the extremities. *The Lancet* 354: 1962-1965

16. Tateishi-Yuyama E, Matsubara H et al. (2002) Therapeutic angiogenesis for patients with limb ischemia by autologous transplantation of bone marrow cells: a pilot study and a randomized controlled trial. *The Lancet* 360:427-35

17. Matoba S, et al. (2008) Long term clinical outcome after intramuscular implantation of bone marrow mononuclear cells (Therapeutic angiogenesis by cell transplantation [TACT] trial) in patients with chronic limb ischemia. *Amer Heart J* 156:1010-8

18. Money RSR, Herd JA et al.(1998) Effect of cilostazol on walking distance in patients with intermittent claudication caused by peripheral vascular disease. *J Vasc Surg* 27:267-274

19. Sasajima T, Kikuchi S, Ishikawa N, Koyama T (2014). Skin temperature in lower hind limb subjected to distal vein arterialization in rats. *Oxygen Transport to Tissue* vol.XXXVI 2014 Springer

Verlag.361-368.

20. Sasajima T, Koyama T (2013). Biological maintenance of distal vein arterialization. *Oxygen Transport to Tissue XXXIV* Springer Verlag (editors; WJ Welch, DK Harrison, DF Bruley) vol.XXXIV 34:245-250.

21. Koyama T & Sasajima T (2012). Retrograde perfusion of the hind leg in diabetic patients suffering from arteriosclerosis obliterans: Theoretical considerations of oxygen supply and lymphatic flow based on rat models. vol.XXXIII Springer Verlag (editors, Martin Wolf et al.) *Oxygen Transport to Tissue* Springer Verlag.259-262.

22. Folkman J, Haendenschild C, (1980) Angiogenesis in vitro. *Nature* 288:551-6.

23. Mimoun M, Hilligot P, Baux S (1989). The nutrient flap: A new concept of the role of the flap and application to the salvage of arteriosclerotic lower limbs. [Plast Reconstr Surg](#). 84(3):458-67.

24. Takase S, Pascarella I, Bergan JJ, Schmid-Schönbein GW.(2004) Hypertension-induced venous valve remodeling. *J Vas Surg*. 39, 1329-34.