

Medical Research Archives. Vol. 5 Issue 1. January 2017.  
**DESMOID TUMORS: PATHOPHYSIOLOGY, EPIDEMIOLOGY, DIAGNOSIS AND  
TREATMENT MODALITIES .A REVIEW.**

**Authors:**

Çiğdem Fırat KOCA<sup>1</sup>

Yüksel TOPLU<sup>2</sup>

Ahmet Kızılay<sup>3</sup>

**Authors Note:**

<sup>1</sup>Medical Doctor Department of Otolaryngology Malatya State Hospital.

<sup>2</sup> Asistant Professor Doctor Department of Otolaryngology Inonu Univ. Medical Faculty.

Email address: [y.toplu@mynet.com](mailto:y.toplu@mynet.com)

<sup>3</sup>Professor Doctor Department of Otolaryngology Inonu Univ. Medical Faculty.

Email address: [ahmet.kizilay@inonu.edu.tr](mailto:ahmet.kizilay@inonu.edu.tr)

**Correponding Author:**

Çiğdem Fırat KOCA

Malatya State Hospital

Malatya, TURKEY

e-mail: [cifirat@hotmail.com](mailto:cifirat@hotmail.com)

TEL NO: +905302239624

**ABSTRACT**

Desmoid tumors are benign tumors that can be locally aggressive. These tumors are infrequent. The incidence is 2.4 to 4.3 % cases per million in general population. Little is known about the true pathophysiology of these tumors. Hormonal, genetic, trauma have been reported for occurrence of desmoid tumors. But most commonly desmoid tumors are idiopathic. They may be associated with Gardner syndrome and mutations of the familial adenomatous polyposis (FAP) gene. Spontaneous desmoid tumors most commonly are related with beta-catenin gene mutations. This beta-catenin defect causes activation of Wnt/catenin signaling. Desmoid tumors of head and neck region consist of 7-15% of all desmoid cases. The localizations of the tumor is variable. The behaviour and clinical course can not be estimated. For these characteristics there is no standard consensus on treatment approach. Treatment of desmoid tumors based on surgical. The aim of surgery is to maintain low recurrence and morbidity. We wanted to remind the etiology, pathophysiology and treatment modalities under guidance of the literature.

**KEY WORDS:** Desmoid tumors, aggressive fibromatosis, beta-catenin

## **DESMOID TUMORS: PATHOPHYSIOLOGY, EPIDEMIOLOGY, DIAGNOSIS AND TREATMENT MODALITIES .A REVIEW.**

### **INTRODUCTION/BACKGROUND**

World Health Organization (WHO ) described desmoid tumors as ' clonal fibroblastic proliferations 'which originate in the deep soft tissues and behave infiltratively with incapable of metastasis (Kasper et al. 2011).Desmoid tumors are infrequent , locally aggressive tumors. They are nonmalignant tumors of fibroblastic origin. Desmoid tumors can be fatal because of the local invasion , especially when affect vital organs. Mc Farlane first reported the tumor , occurred in the anterior abdominal wall of a young woman in 1832.Later in 1838, Müller gave the name 'desmoid' . Desmoid was derived from the Greek word 'desmos' . Desmos means tendon like.

Desmoid tumors can grow at the site of any fascia, mainly , musculoaponeurotic junction and frequently be met in the anterior abdominal musculature. Desmoid tumors can be categorized according to their occurrence site.

- 1-Abdominal -in the anterior wall.
- 2-Intra-abdominal in the mesentery or pelvis, intraperitoneal or retroperitoneal , and
- 3-Extra-abdominal in the chest ,extremities and head and neck region (Kallam et al 2014).

Stout, in 1954, was first described the terminology. Desmoid tumor, desmona, non-metastasizing fibrosarcoma are some terms that have been used in the literature. There have been no report about racial or ethnic distribution. Allen in 1977, described a classification for fibromatosis and in 1995 Enziger and Weiss handled another classification consist of two subdivisions: superficial (fascial) and deep (musculoaponeurotic) fibromatosis (Kruse et al. 2010).Desmoid tumors form 3 %of all soft tissue neoplasms. The incidence is 2.4 to 4.3 % cases per million in general population.Familial polyposis (FAP) can increase the risk about 1000 folds. Desmoid tumors originate from myofibroblasts, do not have a real capsule and often grow into the surrounding muscle. They act as a 'malignant

tumors ' due to the infiltrative pattern. They can lead to life-threatening and even cause death . Approximately 37 % to 50% desmoids occur in the abdominal region, according to the past studies (Lewis et al. 1999, Bruce et al. 1996, Clark et al. 1996, Kallam et al. 2014)

Desmoid tumors choose especially 30 years , but they may occur younger ages..The average age for diagnosis is 40 years. It has a female predominance. Little is known about the true pathophysiology of these tumors. Hormonal, genetic, trauma have been reported for occurrence of desmoid tumors. But most commonly desmoid tumors are idiopathic. They can develop sporadic or with FAP. Approximately 12-15 % of patients diagnosed FAP develop desmoid tumors. Desmoid tumors that develop in FAP most commonly present in intraabdominal localization.. Desmoid tumors may regress spontaneously rarely. In most cases they continue proliferation and require treatment (Jenayah et al. 2015).

### **1.ETIOLOGY AND PATHOPHYSIOLOGY**

The pathophysiology of desmoid tumors remain unclear and are thought to be multifactorial.Trauma have been shown to enhance occurrence of fibromatosis in 19 to 49 % of cases (Prabhu et al. 2013).Hormonal factors may take part in desmoid tumor development . Reitamo declared increased estradiol receptor content of desmoid tumors compared with unaffected control tissue of the same patients (Reitamo et al 1986).The tumor growth rate slowest in young girls, follows a peak at menopause and decreases later. Familial adenomatous polyposis (FAP), and Gardner 's syndrome increase the desmoid tumor occurrence rate. These diseases have germline mutations within the APC gene (adenomatosis polyposis coli) , located on the long arm of chromosome 5. Approximately 5-19 % of these patients may develop desmoid tumors. On the other hand, germline mutations exist in 1-2 % of all desmoids (Willks et al. 2012).

## DESMOID TUMORS: PATHOPHYSIOLOGY, EPIDEMIOLOGY, DIAGNOSIS AND TREATMENT MODALITIES .A REVIEW.

Desmoid tumors may be present as a part of genetic syndromes, like FAP, which is characterized with a mutation in the gene called adenomatosis polyposis coli (APC). Desmoid tumors can affect approximately 10 - 15% of FAP patients, with an > 800 folds increased risk. Gardner syndrome is described as FAP with extra-abdominal tumors (desmoid tumors, osteomas, etc). The risk factors of desmoid tumor development in FAP patients can be mentioned as , positive family history of desmoid tumor, female sex, an APC mutation 3' to codon 1399 (Sinha et al. 2010, Reitamo et al. 1986). According to a recent study desmoid tumor developing risk exist 100 % in the C3 genotype (described by an APC mutation in 1395-1493 codons) (Nuyttens et al. 2000). Somatic mutations in both APC and beta-catenin genes may also result in sporadic desmoid tumor formation (codon 41,45 of exon 3 of the beta-catenin gene) (Escobar et al. 2012).

### 1.a. CYTOGENETICS

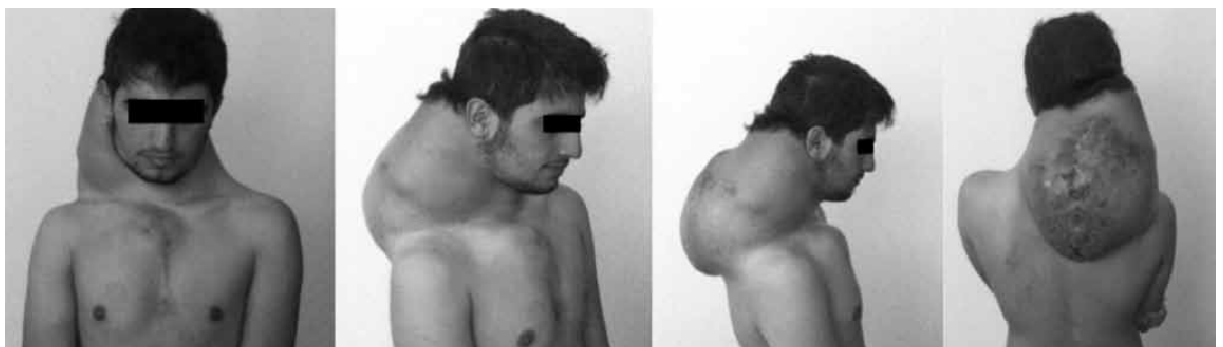Clonal chromosome aberrations are frequent in desmoid tumors. 12-46 % trisomy of chromosome 8 or 20 has been observed in desmoid tumor. Beta-catenin gene mutations has been considered to initiate desmoid tumor formation (Wilks et al. 2012). Beta-catenin , exists in the nucleus and responsible for transcription in the nucleus and takes a role as a cell adhesion molecule. Especially in mesenchymal cells these functions are so important. The exon 3 of CTNNB1 encodes a protein that organize the phosphorylation of beta-catenin . Mutations of CTNNB1 cause beta-catenin accumulation. According to the

some studies , approximately 85 % of sporadic desmoid cases show mutations in this gene; three distinct mutations; T41A, S45F, and S45P. S45F was accused for recurrences after desmoid tumor surgery. The relative risk has been reported as 3.5 folds. These knowledge underline the molecular pattern of this tumor (Kasper et al. 2011).

APC controls the beta-catenin protein amount by phosphorylation. In standard situation ; the Wnt pathway inhibit the phosphorylation. This nonphosphorylated beta-catenin piles up in the cytoplasm and goes to the nucleus and plays role together with other proteins to maintain transcription of genes like as CYCD1 and MYC. These genes are responsible for proliferation , like in embryological pattern, organ development, regeneration of epithelial tissues and wound healing (Lazar et al. 2009). According to many authors ( Tejpar et al. 1999, Montgomery et al 2002) beta-catenin can be used to differentiate desmoid from other histological similar tumor ( Kallam et al. 2014).

### 2. DIAGNOSIS

The desmoid tumor incidence peaks both at 8 years of age and in the third of fourth decades of life (Wang et al. 2014). Desmoid tumors of head and neck region consist of 7-15% of all desmoid cases (De Bree et al. 2013). An enlarging painless mass is the most prevalent symptom of head and neck region tumors. Sometimes the tumor can reach greater sizes with local invasion among facial plans and can cause deformities. Toplu et. al reported a huge desmoid tumor in the neck region (Figure 1-2) ( Toplu et al. 2014).



**DESMOID TUMORS: PATHOPHYSIOLOGY, EPIDEMIOLOGY, DIAGNOSIS AND TREATMENT MODALITIES .A REVIEW.**

Figure 1: A 20-year old man; a huge desmoid tumor located in his neck region. (from [Toplu Y, Öztanır N, Çetinkaya Z, Koç A, Kızılay A.](#) [Giant desmoid tumor in the neck]. [Kulak Burun Bogaz Ihtis Derg.](#) 2014 Sep-Oct;24(5):299-302.)

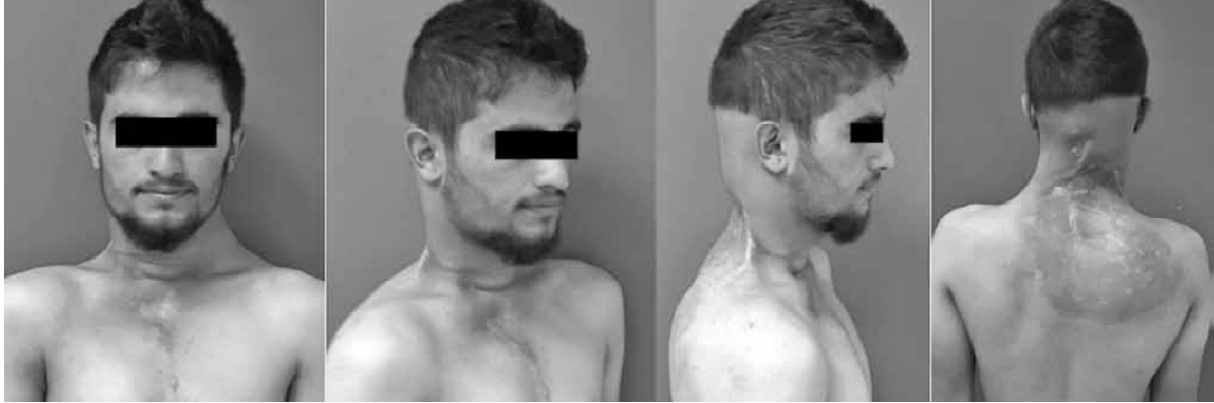

Figure 2: Photographs of the same patient after two months later (after surgery combined with radiotherapy) (from [Toplu Y, Öztanır N, Çetinkaya Z, Koç A, Kızılay A.](#) [Giant desmoid tumor in the neck]. [Kulak Burun Bogaz Ihtis Derg.](#) 2014 Sep-Oct;24(5):299-302.)

The prominent affected location is mandible, followed by the submandibular region, tongue, neck and paranasal sinuses. Kruse et al. (Kruse et al. 2010) proved that approximately 57 % of all desmoid tumors of head and neck region existed in pediatrics under age 11 and they may present at a younger age comparison with other regions, with a median age of 3.6 years versus 7.8 (Zheng et al. 2016).

A fibrosed , immobile skar is the most common complaint that limits the functional skills. Desmoid tumors sometimes can be fatal and deaths are recorded in the literature. Desmoid tumors look like scar tissue macroscopically. Characteristically, they are poorly circumscribed with frequent infiltration of adjacent structures. Cellularity is variable and muscle invasion with destruction is frequently observed. Desmoid tumors may be painful, due to rapid growth , encasement of nerves or effects on joint mobility ( Wilks et al. 2012).

Desmoid tumor imaging findings have no characteristically. On CT lesions with high collagen content have higher attenuation and enhancement . On MRI scans, desmoid tumors seem isointense to skeletal muscles on T1-weighted images and hyperintense on T2-

weighted images. High signal intensity on T2-weighted images mean increased cellularity on the other and low signal intensity correlate with high collagen content.

In histological sections , a monoclonal spindle cell neoplasm is observed without atypia or dysplastic features. Fibrosarcoma, leiomyosarcoma, fibroma, leiomyoma, nodular fasciitis, hypertrophic or keloid scar should be reminded in differential diagnosis ( Zheng et al. 2016).

Nuclear staining for beta-catenin helps in the diagnosis and is a fixed finding (about 80 % of patients), but it is not specific and can be determined in some other types of tumors. The confirmation of beta-catenin gene mutation support the exact diagnosis, which can be found in approximately 85 % of cases (Carlson et al. 2007).

In extra-abdominal desmoids , the differential diagnosis should be made with fibroblastic sarcoma and low- grade fibromyxoid sarcoma, keloids. Fibroblastic sarcoma characteristically is more cellular , has more atypia and the spindle cells exist in a conspicuous hemgbare pattern and the sarcoma may be positive in beta-catenin staining. On the other hand , low-grade fibromyxoid sarcomas have more sensitive nucleus structure

## **DESMOID TUMORS: PATHOPHYSIOLOGY, EPIDEMIOLOGY, DIAGNOSIS AND TREATMENT MODALITIES .A REVIEW.**

and characteristically show a typical network of curvilinear blood vessels. Also beta-catenin staining may present in 30 % of cases. The translocation FUS-CREB-3L2 gene fusion by fluorescence in situ hybridization analysis can help in the diagnosis of low- grade fibromyxoid sarcoma ( Kasper et al. 2011).

Desmoid tumors are positive for vimentin and sometimes for smooth muscle actin. Staining for nuclear beta-catenin can be observed in most of desmoid tumors, but it is not specific. 56 % of superficial fibromatosis, 30% of low-grade myofibroblastic sarcoma and 22% of solitary fibrous tumors can express staining for nuclear beta-catenin. The beta-catenin gene is located on chromosome 3p22 ( Escobar et al. 2012).

### **3.TREATMENT**

Treatment of desmoid tumors based on surgical. The aim of surgery is to maintain low recurrence and morbidity. Tumor location size (> 5 cm), gender and resection margins affect the prognosis ( Kasper et al. 2011). Aggressive methods at resection these tumors; may cause poor prognosis. The treatment modality has to be individualized for each patient ( Jenayah et al. 2015). A locally circumscribed tumor can be operated surgically in the first-line therapy. Observation, watch and see, may be another therapeutic option. The tumors behave infiltrative and have no true capsule ( Kasper et al. 2011).

A wide surgical excision of the lesion sometimes difficult in the head and neck region because of the vital structures. Radiation therapy is usually combined with surgery for residual disease and to reduce recurrence ( Sobani et al. 2011). However the rare incidence of desmoid tumor in head and neck region complex structural anatomy, vital structures, and infiltrative nature of the tumor make impossible an exact diagnose and complete resection ( Rhim et al. 2013). Surgery is the main treatment modality, especially for resectable, localized tumors. The unpredictable tumor behaviour , site involvement affect the surgery. Microscopic status of tumor margins is an enigma.

Tumor site; affects the quality of the surgery. Surgical approach , first of all , should preserve functional and structural capacity. An aggressive approach may result in unnecessary morbidity and enable to maintain local recurrence prevention ( Kasper et al. 2011). Desmoid tumors can proliferate into surrounding tissues and destroy even vital structures or organs. This may be fatal. Fasching et al (Fasching et al. 1988) reported a correlation between positive margins and incidence of local recurrence of the disease. Aggressive fibromatosis frequently may not be resectable completely. Gay et al, Miche and Seegenschmiedt, and Konath et al. underlined the importance of radiotherapy in control of postoperative setting and in unresectable or incomplete resectable diseases. Patients diagnosed with desmoid tumors should be followed -up closely. Recurrence may be often seen in the following first few years ( Sun et al. 2010).

Radiation therapy is effective in desmoid tumor especially after margin positive resection and/or in unresectable tumors ( Kasper et al. 2011). It has been reported that microscopic margin status of the tumor are a risk factor on local recurrence of the desmoid tumors (Ballo et al. 1999, Stoeckle et al 2009, Spear et al. 1998). On the other hand, some studies could not show the effect of microscopic margin on recurrence of the tumor ( Lev et al. 2007, Merchant et al. 1999, Gronchi et al 2003, Lewis et al. 1999, Lazar et al. 2009).

Radiotherapy has been reported as an effective treatment method in adults , but there is a little information about effectiveness in paediatric population. Long term risk of secondary malignancy limits the radiotherapy. Radiotherapy should be preferred in children for unresectable desmoid tumors or as a complimentary therapy in which surgical or systemic treatments become unsuccessful . Radiotherapy combined with chemotherapy in adjuvant setting has been reported to be effective in positive resection margins, and to maintain a reduced rates from 74 to 40 % ( Buitendijk et al. 2005, Wilks et al. 2012).

## **DESMOID TUMORS: PATHOPHYSIOLOGY, EPIDEMIOLOGY, DIAGNOSIS AND TREATMENT MODALITIES .A REVIEW.**

Radiation therapy (50 to 60 Gy) alone or combined with surgery is an effective treatment method. Soft tissue necrosis, bone fracture, radiation, enteritis, peripheral neuropathy, edema with cellulitis, limb shortening, bone hypoplasia are the side effects can be seen due to higher dose levels of radiation therapy (Lakhan et al. 2008). Radiation-induced neoplasms especially can be observed after high doses > 56 Gy

Tamoxifen, nonsteroidal and steroidal anti-inflammatory agents, interferon, testolactone and cytotoxic chemotherapeutic agents have been assigned to control desmoid tumors when surgery is impossible (Kasper et al. 2011).

Desmoid tumors have been observed more frequent among women. Approximately 80% of these tumors occur in women. Desmoid tumors get a higher incidence during pregnancy, in premenopausal women. This can be explained by a hormonal dependency. Tamoxifen, toremifene, progesterone, medroxyprogesterone acetate, prednisolone, testolactone and gosereline are some hormonal agents that have been tried in desmoid tumor treatment (Janinnis et al. 2003). It has been showed that all desmoid tumors express nuclear estrogen receptor  $\beta$ . On the other hand; a small part of patients respond to antihormonal therapies (Deyrup et al. 2006). Although the little databases about tamoxifen (120-200 mg/day) are more effective than lower doses (10-40 mg/day) (Hansmann et al. 2004, Kasper et al. 2011).

Oophorectomy also play role as menopause and decreases the desmoid tumor occurrence incidence. NSAIDs, vit C therapy, warfarin have 50 % success. High dose tamoxifen at 120 mg per day along with sulindac is the most common accepted medication. This medication may not be adequate for patients who can not tolerate this treatment (Jenayah et al. 2015).

Pharmacotherapy is often used to control the progression of the tumor. This pharmacotherapy includes non-steroidal anti-inflammatory drugs, cyclooxygenase inhibitors and classical chemotherapy regimens. There has been no consensus on the optimal therapy protocol. The positive effect of NSAIDs in desmoid tumor treatment was detected incidentally in a patient taking indomethacin for radiation-induced pericarditis. The patient had a single desmoid tumor of sternum and the regression was observed during indomethacin treatment (Waddel & Gerner. 1980).

COX-2 was accused for desmoid tumor occurrence. NSAIDs influence beta-catenin pathway. There is no enough study to clarify the alone or combined treatment of NSAIDs with tamoxifen. NSAIDs have low toxicity and this is the advantage of these agents in first choice. Traditional cytotoxic chemotherapy is another alternative (Kasper et al. 2011). Doxorubicin-based chemotherapy (doxorubicin with dacarbazine or doxorubicin with cyclophosphamide and vincristine), actinomycin-D-based chemotherapy or a combination of methotrexate with a vinca alkaloid (vinblastine or vinorelbine) are the main chemotherapy regimens used (Janinis et al. 2003). Weekly administration of methotrexate and vinblastine has been studied mainly in children and has lower toxicity (Kasper et al. 2011).

The dose of doxorubicin ranged between 60 and 90 mg/m<sup>2</sup>/cycle. The main toxicity of doxorubicin is late cardiotoxicity. VAC (Vincristine, actinomycin-D, cyclophosphamide) regimen is another choice. Carcinogenesis and sterility is the limitation of VAC therapy. Desmoid tumor consist of abundant collagen tissue, and has rare mitoses for this characteristics; chemotherapy responses may be slow (Janinis et al. 2003). The treatment algorithm is summarized in Figure 3.

**DESMOID TUMORS: PATHOPHYSIOLOGY, EPIDEMIOLOGY, DIAGNOSIS AND TREATMENT MODALITIES .A REVIEW.**

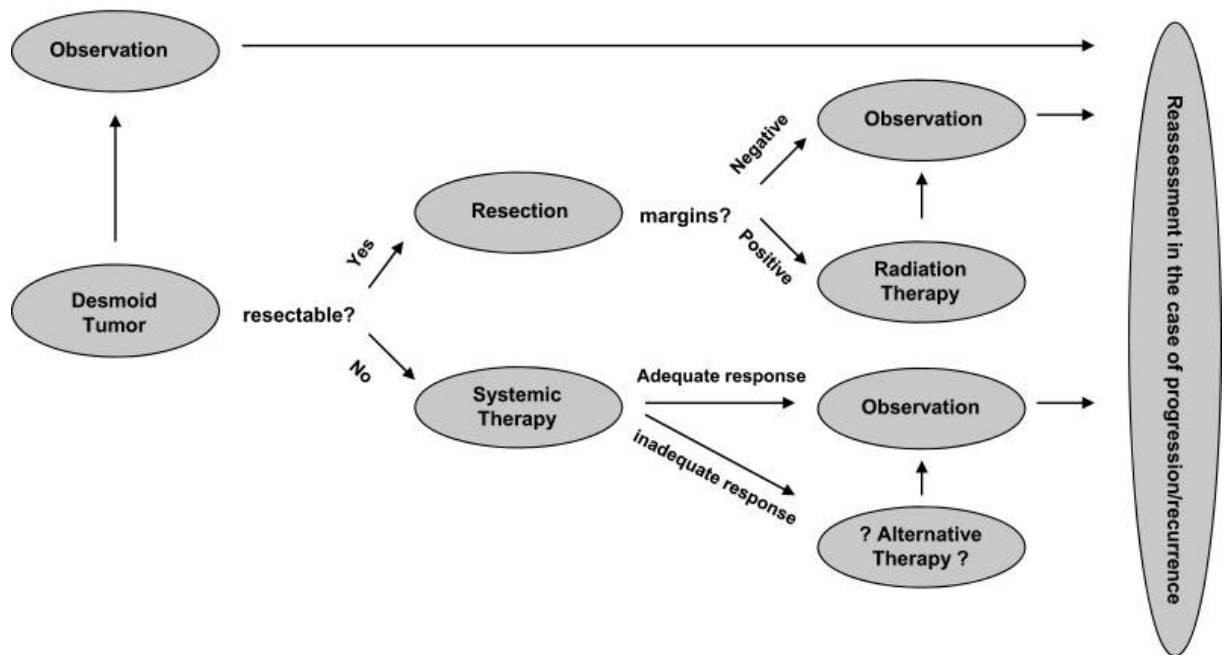


Figure 3: A treatment algorithm for desmoid tumors

Adapted from Lev et al. (Lev D, Kotilingam D, Wei C, et al. Optimizing treatment of desmoid tumors. *J Clin Oncol.* 2007;25:1785–1791).and Lazar et al. (Lazar AJF, Hajibashi S, Lev D. Desmoid tumor: From surgical extirpation to molecular dissection. *Curr Opin Oncol.* 2009;21:352–359).University of Texas MD Anderson Cancer Center.

In 1948 Musgrove and Mc Donald described the desmoid tumors as 'benign nature' (Mankin et al. 2010).Metastasis of desmoid tumors has not been reported yet. Approximately 12% of extra-abdominal fibromatosis originates in the head and neck location. The course of tumor is more aggressive in the head and neck than standard. This more aggressive nature may be due to the restricted anatomy, vital vascular,neural structures ( Kruse et al. 2010).Although malignant transformation of desmoid tumors is very rare, there are some reports of malign transformation in the literature. Posner et al., Schwickerath and Künzig (Posner et al. 1989, Schwickerath et al. 1995)reported malign transformation of desmoid -type fibromatosis to fibrosarcoma. DeSantis ( De Santis et al. 1998).described a case with a transformation into a fibrosarcoma in mandible in 1998 (Min et al. 2011).

Head and neck desmoid tumors are more frequent in children compared to adults. Younger age (< 10 years) was shown as a good prognostic factor in two studies (Oudot et al. 2012, Meazza et al. 2010, Flucke et al. 2014).In pediatric population desmoid tumors prefer head or facial region rather than the neck, and there has been a male predominance different from adults (Rhim et al. 2013).

İlaslan et al. have been reported radiofrequency ablation method with no recurrence after 30 months follow-up (İlaslan et al. 2010).Mayo clinic , USA showed percutaneous cryoablation as an alternative treatment for small to middle sized tumors (Kujak et al. 2010, Sobani et al. 2011).

Patients should be observed closely by clinical examination postoperatively by the help of radiographic studies every 6 months for the first 3 years , every 12 months from 3 to 6 years , and after every other year ( Escobar et al. 2012).

**DESMOID TUMORS: PATHOPHYSIOLOGY, EPIDEMIOLOGY, DIAGNOSIS AND TREATMENT MODALITIES .A REVIEW.**

**REFERENCES**

1. Ballo MT, Zagars GK, Pollack A, et al. Desmoid tumor: prognostic factors and outcome after surgery, radiation therapy, or combined surgery and radiation therapy. *J Clin Oncol* 1999; 17:158–167. [PubMed: 10458229]
2. Bruce JM, Bradley EL 3<sup>rd</sup>, Satchidanand SK. A desmoid tumour of the pancreas. Sporadic intra-abdominal desmoids revisited. *Int J Pancreatol.* 1996;19:197- 203. [PubMed: 8807365]
3. Buitendijk S, van de Ven CP, Dumans TG, et al. Pediatric aggressive fibromatosis: a retrospective analysis of 13 patients and review of literature. *Cancer.* 2005 Sep 1;104(5):1090-9. [PubMed: 16015632]
4. Carlson JW, Fletcher CD. Immunohistochemistry for beta-catenin in the differential diagnosis of spindle cell lesions: Analysis of a series and review of the literature. *Histopathology* 2007;51:509 –514. [PubMed: 17711447]
5. Clark SK, Phillips RK. Desmoids in familial adenomatous polyposis. *Br J Surg.* 1996; 83:1494-504.. [PubMed:9014661]
6. De Bree E, Zoras O, Hunt JL, et al. Desmoid tumors of the head and neck: a therapeutic challenge. *Head Neck* 2013;36:1517–26.[PubMed:24421052]
7. De Santis D. Fibromatosis of the mandible: case report and review of previous publications. *Br J Oral Maxillofac Surg* 1998;36:384-8.[PubMed:9831061]
8. Deyrup AT, Tretiakova M, Montag AG. Estrogen receptor-beta expression in extraabdominal fibromatosis: An analysis of 40 cases. *Cancer* 2006;106(1):208-13.[PubMed:16333857]
9. Escobar C, Munker R, Thomas JO, Li BD, Burton GV. Update on desmoid tumors. *Ann Oncol.* 2012 Mar;23(3):562-9. [PubMed:21859899]
10. Fasching MC, Saleh J, Woods JE. Desmoid tumors of the head and neck. *Am J Surg.* 1988 ;156(4):327-31.[PubMed:3177760]
11. Flucke U, Tops BB, van Diest PJ, Slootweg PJ. Desmoid-type fibromatosis of the head and neck region in the paediatric population: a clinicopathological and genetic study of seven cases. *Histopathology.* 2014 May;64(6):769-76. [PubMed:24206198]
12. Gronchi A, Casali PG, Mariani L et al. Quality of surgery and outcome in extra-abdominal aggressive fibromatosis: A series of patients surgically treated at a single institution. *J Clin Oncol* 2003;21:1390 –1397. [PubMed:12663732]
13. Hansmann A, Adolph C, Vogel T et al. High-dose tamoxifen and sulindac as first-line treatment for desmoid tumors. *Cancer* 2004;100:612– 620. [PubMed:14745880]
14. Ilaslan H, Schils J, Joyce M, Marks K, Sundaram M: Radiofrequency ablation: another treatment option for local control of desmoid tumors. *Skeletal Radiol* 2010, 39:169-173. [PubMed:19816682]
15. Janinis J, Patriki M, Vini L, Aravantinos G, Whelan JS. The pharmacological treatment of aggressive fibromatosis: a systematic review. *Ann Oncol.* 2003 Feb;14(2):181-90. [PubMed:12562642]
16. Jenayah AA, Bettaieb H, Saudi S, Gharsa A, Sfar E, Boudaya F, Chelli D. Desmoid tumors: clinical features and treatment options: a case report



**DESMOID TUMORS: PATHOPHYSIOLOGY, EPIDEMIOLOGY, DIAGNOSIS AND TREATMENT MODALITIES .A REVIEW.**

- and a review of literature. *Pan Afr Med J.* 2015 Jun 5;21:93. [PubMed:26516394]
17. Kallam AR, Ramakrishna BV, Roy GK, Karthik KR. Desmoid tumours: our experience of six cases and review of literature. *J Clin Diagn Res.* 2014 Oct;8(10):NE01-. [PubMed:25478405]
18. Kasper B, Ströbel P, Hohenberger P. Desmoid tumors: clinical features and treatment options for advanced disease. *Oncologist.* 2011;16(5):682-93. [PubMed:21478276]
19. Kruse AL, Luebbers HT, Grätz KW, Obwegeser JA. Aggressive fibromatosis of the head and neck: a new classification based on a literature review over 40 years (1968-2008). *Oral Maxillofac Surg.* 2010 Dec;14(4):227-32. [PubMed:20407799]
20. Kujak JL, Liu PT, Johnson GB, Callstrom MR: Early experience with percutaneous cryoablation of extra-abdominal desmoid tumors. *Skeletal Radiol* 2010, 39:175-182. [PubMed:19768644]
21. Lakhan SE, Eager RM, Harle L. Aggressive juvenile fibromatosis of the paranasal sinuses: case report and brief review. *J Hematol Oncol.* 2008 May 28;1:3. [PubMed:18577255]
22. Lazar AJ, Hajibashi S, Lev D. Desmoid tumor: from surgical extirpation to molecular dissection. *Curr Opin Oncol.* 2009 Jul;21(4):352-9. [PubMed:19436199]
23. Lev D, Kotilingam D, Wei C, et al. Optimizing treatment of desmoid tumors. *J Clin Oncol* 2007; 25:1785–1791. [PubMed:17470870]
24. Lewis JJ, Boland PJ, Leung DH, Woodruff JM, Brennan MF. The enigma of desmoid tumours. *Ann Surg.* 1999;229:866-72. [PubMed:10363901]
25. Mankin HJ, Hornicek FJ, Springfield DS. Extra-abdominal desmoid tumors: a report of 234 cases. *J Surg Oncol.* 2010 Oct 1;102(5):380-4. [PubMed:19877160]
26. Meazza C, Bisogno G, Gronchi A, Fiore M, Cecchetto G, Alaggio R, Milano GM, Casanova M, Carli M, Ferrari A. Aggressive fibromatosis in children and adolescents: the Italian experience. *Cancer.* 2010 Jan 1;116(1):233-40. [PubMed:19950127]
27. Merchant NB, Lewis JJ, Woodruff JM et al. Extremity and trunk desmoid tumors: A multifactorial analysis of outcome. *Cancer* 1999;86:2045–2052. [PubMed:10570430]
28. Min R, Zun Z, Lizheng W, Minjun D, Shengwen L, Wenjun Y, Chenping Z. Oral and maxillofacial desmoid-type fibromatoses in an eastern Chinese population: a report of 20 cases. *Oral Surg Oral Med Oral Pathol Oral Radiol Endod.* 2011 Mar;111(3):340-5. [PubMed:21247785]
29. Montgomery E, Torbenson MS, Kaushal M, Fisher C, Abraham SC. Beta-catenin immunohistochemistry separates mesenteric fibromatosis from gastrointestinal stromal tumour and sclerosing mesenteritis. *Am J Surg Pathol.* 2002;26:1296-301. [PubMed:12360044]
30. Nuyttens JJ, Rust PF, Thomas et al. Surgery versus radiation therapy for patients with aggressive fibromatosis or desmoid tumors: a comparative review of 22 articles. *Cancer* 2000; 88: 1517–1523. [PubMed:10738207]
31. Oudot C, Orbach D, Minard-Colin V, Michon J, Mary P, Glorion C, Helfre S, Habrand JL, Oberlin O. Desmoid fibromatosis in pediatric patients: management based on a retrospective analysis of 59 patients and a review of the literature. *Sarcoma.*

**DESMOID TUMORS: PATHOPHYSIOLOGY, EPIDEMIOLOGY, DIAGNOSIS AND TREATMENT MODALITIES .A REVIEW.**

- 2012;2012:475202.  
[PubMed:2292401]
32. Posner MC, Shiu MH, Newsome JL, Hajdu SI, Gaynor JJ, Brennan MF. The desmoid tumor: not a benign disease. *Arch Surg* 1989;124:191-6. [PubMed:2916941]
33. Prabhu R, Natarajan A, Shenoy R, Vaidya K. Aggressive fibromatosis (desmoid tumour) of the head and neck: a benign neoplasm with high recurrence. *BMJ Case Rep.* 2013 Jun 28;2013. [PubMed:23814230]
34. Reitamo JJ, Scheinin TM, Hayry P. The desmoid syndrome. New aspects in the cause, pathogenesis and treatment of the desmoid tumor. *Am J Surg* 1986;151:230e7. [PubMed:3946757]
35. Rhim JH, Kim JH, Moon KC, Park SW, Sohn CH, Choi SH, Yun TJ, Chang KH. Desmoid-type fibromatosis in the head and neck: CT and MR imaging characteristics. *Neuroradiology.* 2013 Feb;55(3):351-9. [PubMed:23338838]
36. Schwickerath J, Künzig HJ. Spontaneous malignant transformation of extra-abdominal fibromatosis to fibrosarcoma. *Geburtshilfe Frauenheilkd* 1995;55:173-5. [PubMed:7665068]
37. Sinha A, Tekkis PP, Gibbons DC et al. Risk factors predicting desmoid occurrence in patients with familial adenomatous polyposis: a meta-analysis. *Colorectal Dis* 2010. [PubMed:20528895]
38. Sobani ZA, Junaid M, Khan MJ. Successful management of aggressive fibromatosis of the neck using wide surgical excision: a case report. *J Med Case Rep.* 2011 Jun 27;5:244. [PubMed:21707981]
39. Spear MA, Jennings LC, Mankin HJ et al. Individualizing management of aggressive fibromatoses. *Int J Radiat Oncol Biol Phys* 1998;40:637– 645. [PubMed:9486614]
40. Stoeckle E, Coindre JM, Longy M et al. A critical analysis of treatment strategies in desmoid tumours: A review of a series of 106 cases. *Eur J Surg Oncol* 2009;35:129 –134. [PubMed:18760561]
41. Sun G, Xu M, Huang X. Treatment of aggressive fibromatosis of the head and neck. *J Craniofac Surg.* 2010 Nov;21(6):1831-3. [PubMed:21119433]
42. Tejpar S, Nollet F, Li C, Wunder JS, Michils G, dal Cin P, et al. Predominance of beta-catenin mutations and beta-catenin dysregulation in sporadic aggressive fibromatosis. *Oncogene.* 1999;18:6615-20. [PubMed:10597266]
43. Toplu Y, Öztanır N, Çetinkaya Z, Koç A, Kızılay A. [Giant desmoid tumor in the neck]. *Kulak Burun Bogaz İhtis Derg.* 2014 Sep-Oct;24(5):299-302. [PubMed:25513876]
44. Waddell WR, Gerner RE. Indomethacin and ascorbate inhibit desmoid tumours. *J Surg Oncol* 1980;15:85–90. [PubMed:7421272]
45. Wang W, Koirala U, Ma S, et al. Age-based treatment of aggressive fibromatosis in the head and neck region. *J Oral Maxillofac Surg* 2014;72:311–21. [PubMed:24438598]
46. Wilks DJ, Mowatt DJ, Merchant W, Liddington MI. Facial paediatric desmoid fibromatosis: a case series, literature review and management algorithm. *J Plast Reconstr Aesthet Surg.* 2012 May;65(5):564-71. [PubMed:22154716]
47. Zheng Z, Jordan AC, Hackett AM, Chai RL. Pediatric desmoid fibromatosis of the parapharyngeal space: A case report and review of

**DESMOID TUMORS: PATHOPHYSIOLOGY, EPIDEMIOLOGY, DIAGNOSIS AND  
TREATMENT MODALITIES .A REVIEW.**

literature. Am J Otolaryngol. 2016 Jul-  
Aug;37(4):372-5. [PubMed:

27040413]